

CASE REPORT

An unusual finding of giant fat-rich retroperitoneal masses in a patient with Graves' disease

Hiromichi Yoshida^{1,*}, Kazuaki Nakajima², Haruyuki Hayashi², Shinjiro Kimura³ and Yasufumi Irie¹

¹Division of Internal Medicine, San-ai Memorial Hospital, Chiba, Japan, ²Division of Surgery, San-ai Memorial Hospital, Chiba, Japan, ³Division of Radiology, Inoue Memorial Hospital, Chiba, Japan

*Correspondence address. Division of Internal Medicine, San-ai Memorial Hospital, 2-2-3 Shinchiba, Chuo-ku, Chiba 260-0031, Japan. Tel: +81(043)-246-2271; Fax: +81(043)-248-6807; E-mail: yosh-915@spice.ocn.ne.jp

Abstract

We report the case of a 48-year-old man who was unexpectedly found by abdominal ultrasonography to have large retroperitoneal masses accompanied by Graves' disease. Computed tomography and magnetic resonance imaging further demonstrated giant fat-rich soft masses arising within both renal sinuses. Histopathological examination of the mass was performed twice at 5-year intervals, with both examinations indicating fatty tissue cells with chronic fibrous panniculitis. Intravenous pulse therapy and successive oral glucocorticoid therapy were ineffective against Graves' ophthalmopathy or mass lesion. An antithyroid hormone regimen was followed by subtotal thyroid resection, leading to improvements in hyperthyroidism. Mass growth then attenuated slowly as the thyroid hormones returned to normal levels. The long-term follow-up of this patient should carefully monitor the appearance of warning signs such as mass effects.

INTRODUCTION

Graves' disease is the most common disorder resulting in hyperthyroidism due to autoantibody production. Chronic panniculitis (CP) is a rare, non-neoplastic, inflammatory disorder characterized by chronic mesenteric inflammation. Herein, we encountered a rare case with both the diseases and their long-term complications. From a standpoint of the cause-and-effect relationship, a possible association between these complications has been considered.

CASE PRESENTATION

A 48-year-old man presented to our institution in May 1999 with complaints of facial oedema and chest discomfort. Bilateral exophthalmos, mild soft struma, a mildly distended abdomen with a soft mass, and slight leg oedema were noted during

physical examination. The patient had no medical history. Laboratory examinations revealed hyperthyroidism: thyroid-stimulating hormone (TSH), <0.05 (normal range, 0.50–5.00) μ U/ml; free triiodothyronine (FT3), 12.40 (normal range, 2.30–4.30) pg/ml; free thyroxine (FT4), 4.00 (normal range, 0.90–1.70) ng/dl and anti-TSH receptor antibody, 5.5 (normal levels, <2.0) IU/l. No other abnormal laboratory examinations were noted. Clinical data were consistent with that of Graves' disease. Hyperthyroidism was treated using thiomazole. Abdominal ultrasonography showed unexpected abdominal masses attached to the hilus of each kidney. Abdominal computed tomography (CT) demonstrated large bilateral retroperitoneal masses arising within the renal sinuses, with some heterogeneous attenuation in the fat-rich density area. However, no deformity or dilatation implying a mass effect on the urine stream was observed in the ureters, pelvis or calyx, which were surrounded by fat-rich tissue (Fig. 1). From the series of CT examinations,

Received: August 23, 2019; Revised: April 27, 2020; Accepted: May 22, 2020

© The Author(s) 2020. Published by Oxford University Press. All rights reserved. For Permissions, please email: journals.permissions@oup.com

This is an Open Access article distributed under the terms of the Creative Commons Attribution Non-Commercial License (<http://creativecommons.org/licenses/by-nc/4.0/>), which permits non-commercial re-use, distribution, and reproduction in any medium, provided the original work is properly cited. For commercial re-use, please contact journals.permissions@oup.com

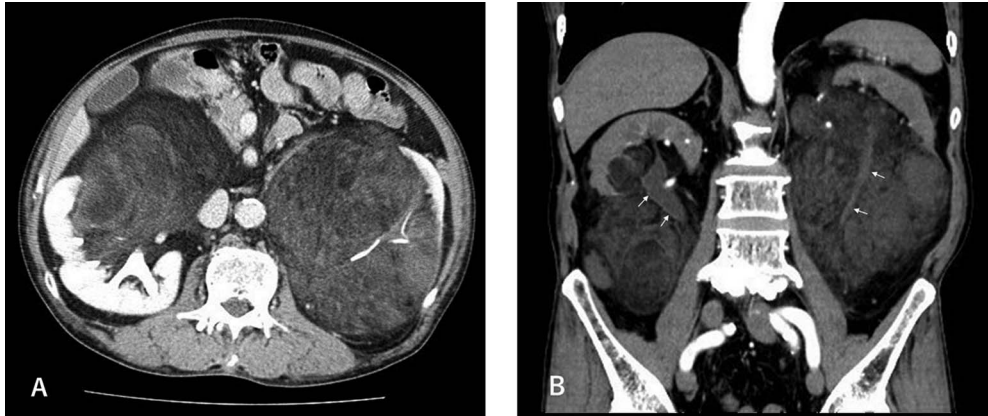

Figure 1: (A) Axial enhanced CT image showing bilateral giant masses arising at the renal sinuses; (B) sagittal enhanced CT image showing masses displacing the kidneys superolaterally and lack of dilatation of the pelvis or ureter (arrow).

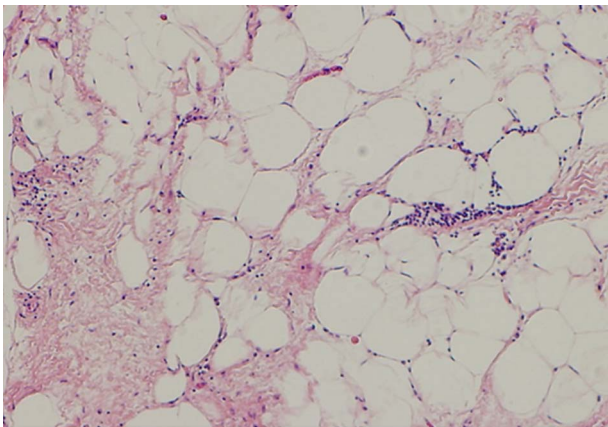


Figure 2: Histological findings showing fat tissue with CP (H&E stain, $\times 80$).

the volume of the mass was estimated by considering it as an ellipsoid and using the following formula: $\pi/6 \times \text{length (cm)} \times \text{width (cm)} \times \text{depth (cm)}$ [1]. Blind biopsy to enable differential diagnosis revealed fat tissue with CP (Fig. 2). To treat moderately severe Graves' ophthalmopathy, three courses of intravenous glucocorticoid pulse therapy were administered, followed by oral administration for 6 months. However, it was ineffective against ophthalmopathy and growth of the mass. Subtotal thyroidectomy was performed subsequently due to the lack of efficacy of thiomazole alone, and both FT3 and FT4 levels returned to normal. Figure 3 shows the time course of FT3 levels and the estimated volume of the mass over 20 years, before and after subtotal thyroidectomy combined with thiomazole treatment, indicating higher mass growth rate with a regimen of thiomazole than that after the thyroidectomy, at $\sim 30 \text{ cm}^3/\text{month}$ and $5 \text{ cm}^3/\text{month}$, respectively. During the course, we ascertained that the patient did not change in any aspect of his lifestyle including diet. Five years after subtotal thyroidectomy, a follow-up histological examination was performed using a surgically excised biopsy specimen. The result was similar to that of the initial biopsy. The patient is now stable on a low thiomazole dose at 2.5 mg/d.

DISCUSSION

During early CT of the current case, masses were observed to arise within the perirenal space, specifically at the renal

sinus, and develop outside it. Lipomatosis and cysts are common lesions of the renal sinus with little clinical significance [2]; to refine differential diagnosis, fat identification within a mass is useful. Lipogenic masses are commonly classified as lipoma, lipomatosis or liposarcoma, of which, liposarcomas are the most common sarcoma of the retroperitoneum, generally prevalent in the fifth and sixth decades of life [3]. CT predominantly demonstrated fat attenuation and irregular nodular tissue in the masses, leading us to suspect liposarcoma. Conversely, masses were found to develop symmetrically from the bilateral renal sinuses, and contrast-enhanced CT indicated no urine stream disturbance and a slightly strengthened density in the masses at a later phase, suggesting that the masses are characteristic of benign, soft and fibrous component-containing tissue, demonstrating that such images have limitations regarding their ability in diagnosis.

CP is a rare, benign, fibroinflammatory disorder of unknown aetiology, predominantly affecting mesenteric fat tissue of the small bowel. It is typically diagnosed via abdominal imaging, primarily CT, as an incidental finding. The prevalence of CP is $\sim 0.6\text{--}2.4\%$ [4]. The possible causative factors include autoimmune diseases, trauma, previous abdominal surgery and ischaemia [5]. Various anti-inflammatory and immunomodulatory agents have been reported for its treatment [6]; however, no consensus has yet been reached for an optimal treatment strategy. The possible causative factors in the current case were not found during the clinical course. Autoimmune mechanisms are suggested to contribute to Graves' ophthalmopathy; therefore, CP in the current case may be associated with this autoimmune ophthalmopathy. Any association remains uncertain because corticosteroid pulse treatment was ineffective and no previous cases of Graves' ophthalmopathy with subsequent CP have been reported.

Considering that triiodothyronine (T3), an activated thyroid hormone, mediates several hormone activities [7], FT3 was studied to assess the time course of thyroid hormone. FT3 lowering is suggestively related with mass volume attenuation in the later stage. We have been unsuccessful in finding any reports regarding the cause-and-effect relationships between Graves' disease and peritoneal masses, and only related results from clinical and experimental studies are available. Several clinical investigations have previously indicated that the presence of hyperthyroid might be a risk factor for the development of tumours of the liver, breast, colon, prostate and thyroid [8]. Furthermore, induced hypothyroidism could support extended survival in a range of cancers [9]. Experimental studies have

Time course of FT3 and mass volume

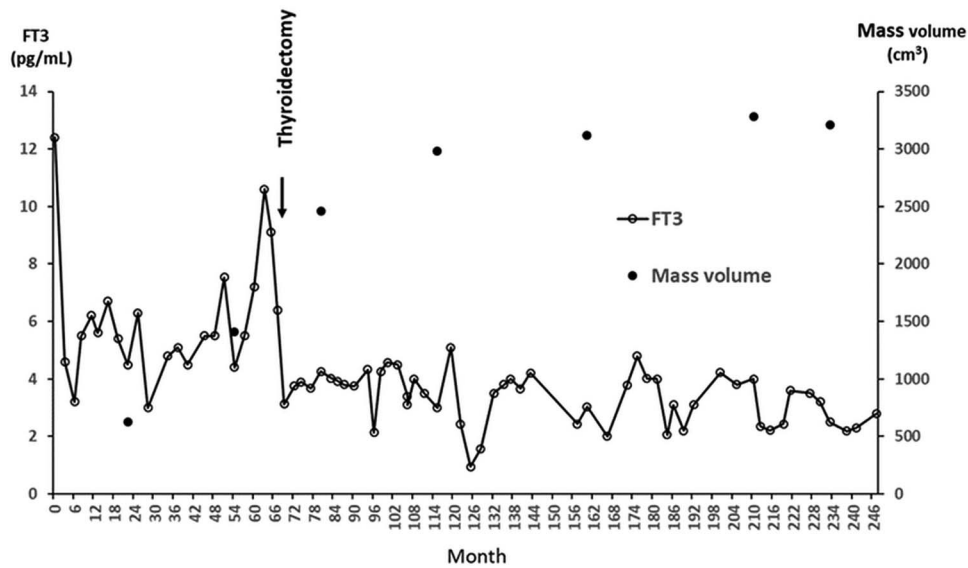


Figure 3: The time course of FT3 levels and total mass volume suggests a possible relationship between mass growth and thyroid hormone reductions after thyroidectomy.

shown that thyroid hormones (T3 and T4) regulate the expression of several genes involved in cell cycle control and cellular differentiation via nuclear receptor binding in various cell types [9]. These observations indicate the importance of thyroid hormones in key processes, such as tumour growth, especially in malignant tumours. Another interesting observation is that thyroid hormones affect body composition, including the proportions of fat and muscle determined using a body composition analyzer [10]. Patients enrolled for this investigation had Graves' disease treated with antithyroid hormone to achieve euthyroidism. Fat loss was observed at a later stage despite body weight gain, suggesting that fat loss was more effective after euthyroid had been attained. To our knowledge, this is the first report describing a case with giant fat-rich masses originating from the renal sinus accompanied by Graves' disease. Potential associations between thyroid hormone and CP should therefore be considered in future studies.

ACKNOWLEDGEMENTS

The authors would like to thank Enago for the English language review.

CONFLICT OF INTEREST STATEMENT

No conflicts of interest.

FUNDING

None.

ETHICAL APPROVAL

Not required.

CONSENT

Written informed consent was obtained from the patient for publication of this case report.

GUARANTOR

Hironmichi Yoshida.

REFERENCES

- O'Neill WC, Robbin ML, Bae KT, Chapman AB, Guay-Woodflord LM, Torres VE, et al. Sonographic assessment of the severity and progression of autosomal dominant polycystic kidney disease: the consortium of real imaging studies in polycystic kidney disease (CRISP). *Am J Kidney Dis* 2005;**46**:1058–64.
- Sung ER, Jae YB, Seung EJ, Soon NO, Yeong JC, Ahwon L, et al. The renal sinus: pathologic spectrum and multimodality imaging approach. *Radiographics* 2004;**24**:S117–31.
- Akram MS, Maryam R, Marc T, Khaled ME, Paula JW, Christine OM. Fat-containing retroperitoneal lesions: imaging characteristics, localization, and differential diagnosis. *Radiographics* 2016;**36**:710–34.
- Goegebakan OE, Osterhoff MA, Albrecht T. Mesenteric panniculitis (MP): a frequent coincidental CT finding of debatable clinical significance. *Roto* 2018;**190**:1044–50.
- Salma A, Darrell SP, John AS, Thomas CS. Sclerosing mesenteritis: clinical features, treatment, and outcome in ninety-two patients. *Clin Gastroenterol Hepatol* 2007;**5**:589–96.
- Josep MS, Sofia T, Joaquim M, Tomas F, Josep MM, Carmen P. Sclerosing mesenteritis: imaging findings in 17 patients. *Am J Roentgenol* 1999;**172**:625–9.

7. Luri MG, Mirian R, Erika LSM, Simone MW, Ana LM. Role of thyroid hormone in the neoplastic process: an overview. *Endocrine-Related Cancer* 2017;**24**:367–85.
8. Herchers A, Johnson RE, Ashur FO, Garfield DH, Davis PJ. Medically induced euthyroid hypothyroxinemia may extend survival in compassionate need cancer patients: an observational study. *Oncologist* 2015;**20**:72–6.
9. Pascual A, Aranda A. Thyroid hormone receptors, cell growth and differentiation. *Biochim Biophys Acta* 2013;**1830**: 3908–16.
10. Kim MJ, Cho SW, Choi S, Ju DL, Park DJ, Park YJ. Changes in body composition and basal metabolic rates during treatment of Graves' disease. *Int J Endocrinol* 2018;**2018**: 9863050.