



Case report

Catastrophic respiratory failure from tuberculosis pneumonia: Survival after prolonged extracorporeal membrane oxygenation support



Max Andresen, Pablo Tapia, Marcelo Mercado, Guillermo Bugedo, Sebastian Bravo, Tomas Regueira*

Facultad de Medicina, Pontificia Universidad Católica de Chile, Marcoleta 367, Santiago, Chile

ARTICLE INFO

Article history:

Received 5 November 2012

Received in revised form

28 May 2013

Accepted 3 June 2013

Keywords:

Tuberculosis

Extracorporeal membrane oxygenation

Mechanical ventilation

Acute respiratory failure

ABSTRACT

Tuberculosis (TB) is an uncommon cause of severe respiratory failure, even in highly endemic regions. Mortality in cases requiring mechanical ventilation (MV) varies between 60 and 90%. The use of extracorporeal membrane oxygenation (ECMO) is not frequently needed in TB. We report the case of a 24 year old woman diagnosed with bilateral pneumonia that required MV and intensive care, patient was managed with prone ventilation for 48 h, but persisted in refractory hypoxemia. Etiological study was only positive for mycobacterium tuberculosis. As a rescue therapy arterio-venous extracorporeal CO₂ removal was started and lasted for 4 days, but fails to support the patient due to greater impairment of oxygenation. Venovenous ECMO was then initiated, thus normalizes gas exchanged and allows lungs to rest. ECMO was maintained for 36 days, with two episodes of serious complication treated successfully. Given the absence of clinical improvement and the lack of nosocomial infection, at 42-day of ICU stay methylprednisolone 250 mg daily for 4 days was started, since secondary organizing pneumonia associated with TB was suspected. Thereafter progressive improvement in pulmonary mechanics and reduction of pulmonary opacities was observed, allowing the final withdrawal of ECMO. Percutaneous tracheostomy was performed and the patient remained connected until her transfer to her base hospital at day 59 of admission to our unit. The tracheostomy was removed prior to hospital discharge, and the patient is today at home. Prolonged ECMO support is a useful and potentially successful tool in catastrophic respiratory failure caused by TB.

© 2013 Published by Elsevier Ltd. Open access under [CC BY-NC-ND license](http://creativecommons.org/licenses/by-nc-nd/3.0/).

1. Introduction

Hypoxic acute respiratory failure (ARF) and acute respiratory distress syndrome (ARDS) are rare complications of pulmonary tuberculosis (TB) that can often be fatal, particularly in patients with extensive TB related lung damage. The reported mortality rate of TB associated with ARF requiring mechanical ventilation (MV) varies from 60 to 80% [1]. Factors independently associated with mortality in TB pneumonia are advanced age, the presence of shock unrelated to sepsis, poor nutritional status and delay in the establishment of diagnosis and institution of specific therapy [2].

Lung protective mechanical ventilatory support is the current standard of care for patients with ARF while venovenous extracorporeal membrane oxygenation (VV-ECMO) is an accepted alternative option in refractory hypoxemic respiratory failure. VV-ECMO ensures adequate oxygenation and CO₂ removal avoiding

ventilator induced lung injury. The decision to continue prolonged VV-ECMO support can be difficult and challenging as limited data are available. In particular, the healing rate of TB pulmonary lesions is characteristically slow and, thus, the need for prolonged ventilatory and non-ventilatory support modalities can be expected in cases of ARF secondary to TB. There are few reports of VV-ECMO for ARF due to TB [2–6], probably because the low frequency of this complication, but also due to cost and accessibility issues.

We describe the case of a young woman with refractory respiratory failure caused by pulmonary TB, which was unresponsive to conventional MV but was successfully managed with prolonged VV-ECMO support. To our knowledge, this is the second published case describing long-term EMCO in TB related ARF [5–7].

2. Clinical case

A 24-year old woman with a background of recently diagnosed laryngeal papilloma and active smoking, who had been previously treated at another hospital, was admitted to our unit with a rapidly

* Corresponding author. Tel.: +56 2 3543265.

E-mail addresses: regueira@med.puc.cl, tregueira@gmail.com (T. Regueira).

progressing ARF secondary to extensive bilateral pneumonia. She described a history of two months of fever, weight loss of 5 kg, cough and non-hemoptoic sputum.

Broad-spectrum intravenous antibiotics (Imipenem and Vancomycin) were started. Anti-TB treatment (Isoniazid 300 mg, Rifampicin 600 mg, Pyrazinamide 1500 mg and Ethambutol 1200 mg) was added shortly after when acid-fast bacilli were identified through sputum microscopy. Her respiratory condition worsened leading to intubation and MV within hours of admission.

Sedation, paralysis and lung protective ventilation (tidal volume 6 mL/kg ideal body weight) were provided. The PO_2/FiO_2 ratio remained below 90 while the oxygenation index was at 22. A chest radiograph showed diffuse bilateral alveolar opacities and right pleural effusion. Arterial blood gases showed a pCO_2 of 72.4 mmHg, a pH 7.26 and bicarbonate of 32 mEq/L. Lactate was 2.2 mmol/L and noradrenaline ($0.05\text{--}0.1 \mu\text{g}^{-1}\text{kg}^{-1}\text{min}$) was required to maintain a mean arterial pressure above 65 mmHg. The patient remained afebrile, C-reactive protein (CRP) was 22.3 mg/dl, and blood and urine cultures were negative. Her APACHE II and SOFA scores were 22 and 12, respectively. *Legionella pneumophila* urinary antigens, mycoplasma and Chlamydia pneumonia serology were all negative. Immunological screening was negative, with a complement C3 of 73 mg/dl and C4 of 17 mg/dl, the CD4 count was 252 and the CD8 was 97 cells/mm³ [3]. Serum cortisol, measured at two different intervals, was below detection limits and computed tomography (CT) scan of the abdomen was normal. At this point, adrenal insufficiency secondary to TB was diagnosed and an intravenous hydrocortisone 100 mg t.i.d. was started.

During the first four days in our ICU, the patient progressed with worsening respiratory failure despite receiving lung protective MV with recruitment maneuvers and high levels of PEEP, according to the "Lung Open Ventilation" protocol [8]. A trial of prone position ventilation, lasting a total of 48 h, was started on day 1 with no effect and persistence of refractory hypoxemia, secondary hypercapnic acidosis, airway plateau pressures >35 cmH₂O, and poor lung compliance.

On day 4, the patient developed a right pneumothorax, with complete lung re-expansion after the insertion of a pleural tube. A

small amount of pleural fluid was drained, which had the characteristics of an empyema. Tidal volumes were reduced to 4 mL/kg due to progressively higher airway pressures, and an arterio-venous carbon dioxide removal system (Novalung[®]), via cannulation of the femoral artery and vein, was used to control $PaCO_2$ and pH [9]. This system allowed adequate control of hypercapnia and permitted an increase of PEEP, with a moderate improvement in oxygenation. However, after four days of arterio-venous carbon dioxide removal, oxygenation worsened and a VV-ECMO was started on the ninth day after admission. Bilateral femoral drainage cannulas (21 and 15 F) and a return cannula (19 F) in the right jugular vein were inserted percutaneously and connected to a 1.8 M²Quadrox D oxygenator (Maquet) with blood flows between 3.5 and 5 l/min and 100% oxygen was provided at 6–8 l/min. Anticoagulation with unfractionated heparin infusion was started, aiming for an activated coagulation time between 180 and 200 s. Adequate gas exchange was achieved after initiation of VV-ECMO and the MV settings were adjusted to provide low tidal volumes and respiratory frequency (Fig. 1).

During the first two weeks of VV-ECMO, CRP and other inflammatory parameters decreased and the lungs were ventilated with very low tidal volumes (V_t 130 ml, RR 10, PEEP 10, FiO_2 0.4). However, poor oxygenation, elevated airway pressures and significant hypercapnic acidosis were observed during trials of VV-ECMO weaning. Throughout this period, two thoracic CT scans showed no significant improvement of the lung infiltrates (Fig. 2). Moreover, no clots were observed in the VV-ECMO circuit during this time.

On the 20th day, a life-threatening hemorrhagic complication occurred when the lectern supporting the oxygenator fell down and broke. The nurse in charge promptly clamped the cannulas and the oxygenator was replaced within the next 15 min. The patient, whom remained stable throughout the event, required a transfusion of 3 units of packed red blood cells. Later on, the patient presented one more episode of right pneumothorax which was successfully treated by pleural chest tubes (Fig. 1).

On the 28th day of VV-ECMO, a bronchoalveolar lavage was performed to rule out active infection prior to use high dose

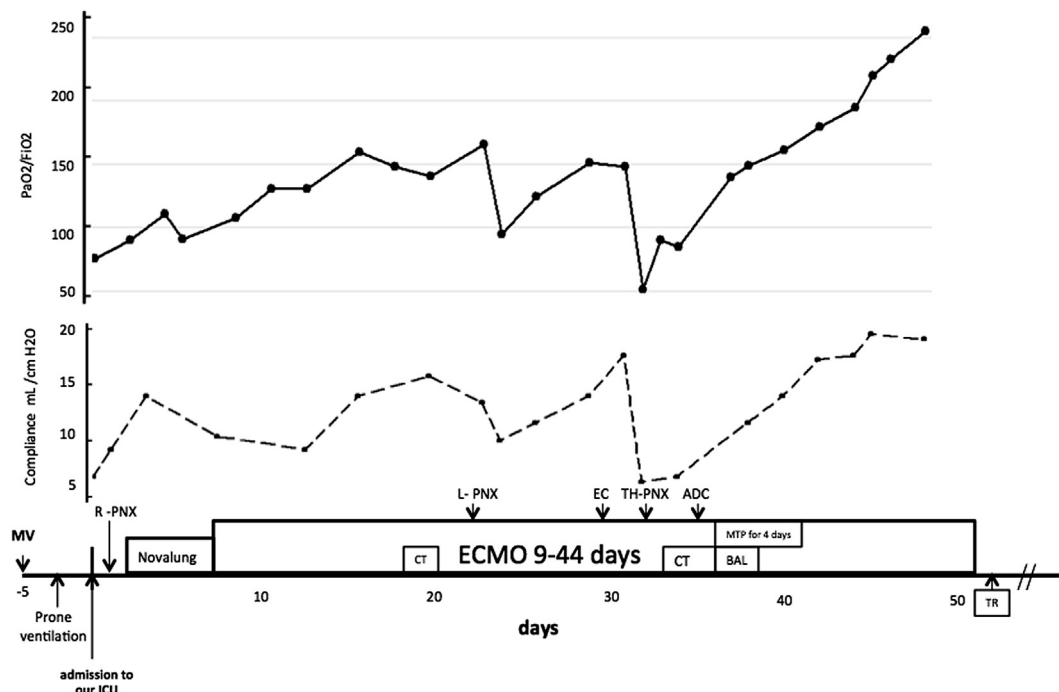


Fig. 1. Patient's clinical course.

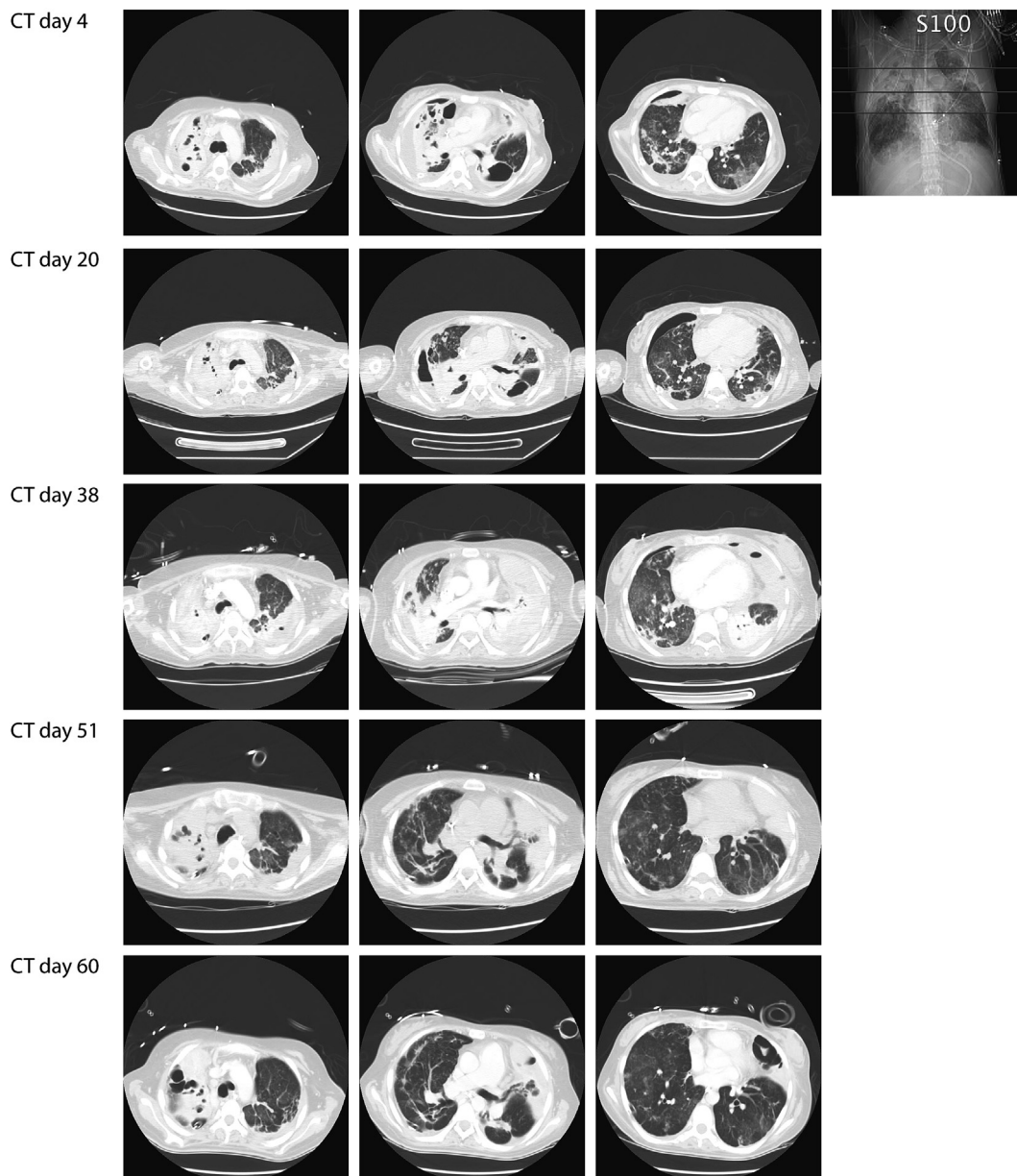


Fig. 2. Computed tomography scan progress.

steroids. The bronchial mucosa was unremarkable, cultures were negative and microscopy did not show acid-fast bacilli. Methylprednisolone was started at 250 mg/day for 4 days.

On the following days, an improvement in pulmonary compliance and gas exchange was progressively observed, with gradual resolution of lung infiltrates on chest radiograph. On the 36th day of VV-ECMO, lung compliance and gas exchange were good enough to resume conventional MV. ECMO was weaned and removed.

After decannulation, anticoagulation was stopped and a percutaneous tracheostomy was then performed. The patient was weaned off the ventilator with a gradual decrease in pressure support and intensive muscular and nutritional rehabilitation. On the 59th day since her admission to the unit, the patient was transferred back to her original hospital, from which she was discharged to her home 20 days later.

After nine months of being discharged from the hospital, she is at your home performing basic activities, both physically as cognitive nearly normal. Their only limitation is given by

persistence yet of using a tracheostomy with speaking valve due to subglottic stenosis. Also the diagnosis of laryngeal papilloma was rejected, since it was shown to correspond to TB.

3. Discussion

TB is an increasing global health issue, affecting a third of the world's population and causing significant morbidity and death. On rare occasions, TB can lead to ARDS. In one study of 187 patients admitted to an intensive care unit with ARDS, TB was found to be the cause in nine patients (4.9%) [1]. Over a 10-year period in the province of Manitoba in Canada, only 13 patients with TB requiring MV were identified, eight of which developed ARDS [10]. In-hospital mortality rate in 41 patients with ARDS caused by TB was 65.9%, a rate significantly higher than that in patients with ARDS caused by other diseases [11]. One possible explanation for the observed elevated mortality, besides the aggressive course of the disease, is the failure to recognize TB as a cause of severe

respiratory failure leading to delays in the initiation of specific treatment [11].

Conventional treatment of ARF includes protective MV by limiting tidal volume [12] and lung recruitment maneuvers [8], pursuing negative fluid balance [13] and adequately treating the cause. VV-ECMO is an alternative for management of catastrophic respiratory failure, which is indicated after high PEEP low Vt ventilation, prone positioning and paralysis have failed to control hypoxemia or hypercapnia.

Homan et al. reported the first case of ECMO associated with TB in 1975, but the patient died after only five days on ECMO [5]. However, the diagnosis of TB was done at autopsy and therefore no anti-TB drug treatment had been administered. From 1987 to 2012, several studies of TB-related ARF requiring VM, do not report extracorporeal pulmonary support [1,2,10,11,14,15].

In pediatric patients, two cases have been reported. The first case is of a fourteen-year old female patient with miliary TB who received extracorporeal CO₂ removed for 6 days, which survived and had a good pulmonary and cognitive functions evaluated at 18 months [16]. The second case was a 15-year old patient with TB pneumonia, which was successfully treated with VV-ECMO for a period of 6 days [6].

The longest reported period of extracorporeal support corresponds to a 20 year old female with TB pneumonia treated with VV-ECMO for 89 days [7]. A normal functional status was reported at 6 months of follow-up. In this case, as in ours, early anti-tuberculosis drug treatment in ICU and protective MV may have helped in resolution of the disease.

Complications of VV-ECMO can either be mechanical or medical. We use heparin-coated circuits and systemic anticoagulation to minimize the risk of clots, which can cause oxygenator failure, consumption coagulopathy, and pulmonary embolism. However, a life-threatening hemorrhagic complication occurred when the lectern where the oxygenator had been placed, fell down and broke. Fortunately, our staff resolved promptly this complication, emphasizing the importance of performing this procedure at technically trained centers.

Upon follow-up, our patient did not present any other major ECMO-related complications, such as neurologic deficit, metabolic derangements, myocardial stunning, arrhythmias, or other organ failures.

Intravenous methylprednisolone (total dose of 1 g) was started on day 37 and its use was temporarily associated with the progressive and steady improvement of the patient's respiratory function. If this therapy allowed us to wean off VV-ECMO two weeks later is debatable, as published data on the use of steroids in TB is scant and of poor quality. A retrospective study in patients with ARF secondary to miliary or TB pneumonia requiring MV could not identify a positive effect of steroids on mortality, days on MV or oxygenation [14].

The scarce literature regarding pulmonary TB related ARF, and pulmonary function and mechanics in these patients is noteworthy. This report suggests that VV-ECMO can be used as an alternative

therapy for refractory hypoxemia secondary to pulmonary TB. This is a potentially reversible condition, and the use of VV-ECMO plus anti-TB treatment was life-saving in this patient, while sparing the harmful effects of conventional mechanical ventilation.

ADC: accidental disconnection circuit ECMO; BAL: Bronchoalveolar lavage; EC: ECMO circuit exchange; CT: computed tomography scan; MTP: methylprednisolone; MV: mechanical ventilation PNX: pneumothorax; TB: Mycobacterium tuberculosis; TR: tracheostomy; TH-PNX: Tension hemo-pneumothorax.

References

- [1] Agarwal R, Gupta D, Aggarwal AN, Behera D, Jindal SK. Experience with ARDS caused by tuberculosis in a respiratory intensive care unit. *Intensive Care Med* 2005;31:1284–7.
- [2] Frame RN, Johnson MC, Eichenhorn MS, Bower GC, Popovich Jr J. Active tuberculosis in the medical intensive care unit: a 15-year retrospective analysis. *Crit Care Med* 1987;15:1012–4.
- [3] Peek GJ, Mugford M, Tiruvoipati R, Wilson A, Allen E, Thalanany M, et al. Efficacy and economic assessment of conventional ventilatory support versus extracorporeal membrane oxygenation for severe adult respiratory failure (CESAR): a multicentre randomised controlled trial. *Lancet* 2009;374:1351–63.
- [4] Davies A, Jones D, Bailey M, Beca J, Bellomo R, Blackwell N, et al. Extracorporeal membrane oxygenation for 2009 influenza A(H1N1) acute respiratory distress syndrome. *JAMA* 2009;302:1888–95.
- [5] Homan W, Harman E, Braun NM, Felton CP, King TK, Smith JP. Miliary tuberculosis presenting as acute respiratory failure: treatment by membrane oxygenator and ventricle pump. *Chest* 1975;67:366–9.
- [6] Petrillo TM, Heard ML, Fortenberry JD, Stockwell JA, Leonard Jr MK. Respiratory failure caused by tuberculous pneumonia requiring extracorporeal membrane oxygenation. *Perfusion* 2001;16:525–9.
- [7] Mauri T, Foti G, Zanella A, Bombino M, Confalonieri A, Patroniti N, et al. Long-term extracorporeal membrane oxygenation with minimal ventilatory support: a new paradigm for severe ARDS? *Minerva Anestesiol* 2012;78:385–9.
- [8] Meade MO, Cook DJ, Guyatt GH, et al. Ventilation strategy using low tidal volumes, recruitment maneuvers, and high positive end-expiratory pressure for acute lung injury and acute respiratory distress syndrome: a randomized controlled trial. *JAMA* 2008;299:637–45.
- [9] Bein T, Weber-Carstens S, Goldmann A, Müller T, Staudinger T, Brederlau J, et al. Lower tidal volume strategy (approximately 3 ml/kg) combined with extracorporeal CO₂ removal versus 'conventional' protective ventilation (6 ml/kg) in severe ARDS: the prospective randomized Xtravent-study. *Intensive Care Med* 2013;39:847–56.
- [10] Penner C, Roberts D, Kunimoto D, Manfreda J, Long R. Tuberculosis as a primary cause of respiratory failure requiring mechanical ventilation. *Am J Respir Crit Care Med* 1995;151:867–72.
- [11] Lee PL, Jerng JS, Chang YL, Chen CF, Hsueh PR, Yu CJ, et al. Patient mortality of active pulmonary tuberculosis requiring mechanical ventilation. *Eur Respir J* 2003;22:141–7.
- [12] Ventilation with lower tidal volumes as compared with traditional tidal volumes for acute lung injury and the acute respiratory distress syndrome. *N Engl J Med* 2000;342:1301–8.
- [13] Comparison of two fluid-management strategies in acute lung injury. *N Engl J Med* 2006;354:2564–75.
- [14] Kim YJ, Paek KM, Jeong E, Na JO, Oh YM, Lee SD, et al. Pulmonary tuberculosis with acute respiratory failure. *Eur Respir J* 2008;32:1625–30.
- [15] Befort P, Corne P, Godreuil S, Jung B, Jonquet O. Clinical review of eight patients with acute respiratory distress syndrome due to pulmonary tuberculosis. *Scand J Infect Dis* 2012;44:222–4.
- [16] Monier B, Fauroux B, Chevalier JY, Leverger G, Nathanson M, Costil J, et al. Miliary tuberculosis with acute respiratory failure and histiocytic hemophagocytosis. Successful treatment with extracorporeal lung support and epidophyllotoxin VP 16-213. *Acta Paediatr* 1992;81:725–7.