

# The role of mucin cell-free DNA detection as a new marker for the study of acellular pseudomyxoma peritonei of appendicular origin by liquid biopsy

Damián García-Olmo<sup>ID</sup>, Susana Olmedillas-López, Delia Cortés-Guiral, Pedro Villarejo, Irene López Rojo, Héctor Guadalajara, Soledad García Gómez-Heras and Mariano García-Arranz

## Abstract

**Background:** Acellular pseudomyxoma peritonei (aPMP) is a rare peritoneal malignancy characterized by the accumulation of large amounts of mucin (lacking tumor cells) in the peritoneum. Many cases account for several kilograms of mucin to be screened by the pathologist. This is a comprehensive study of three patients with aPMP, whose tumors showed *KRAS* mutation, allowing for the tracking of this marker by liquid biopsy.

**Methods:** Pre and post-surgery plasma, and mucin removed during cytoreductive surgery were collected from the patients. *KRAS* mutations were analyzed using droplet digital polymerase chain reaction (ddPCR). Mucin was injected in mice. *KRAS* and cytokine levels were measured in plasma of the mice using ddPCR and a magnetic bead-based assay. Mucin microbiome was analyzed by 16S rRNA sequencing.

**Results:** *KRAS* mutations were detected in mucin cell-free DNA (cfDNA) from the three patients but not in the pre or post-surgery plasma. Electron microscopy detected microparticles (diameter <0.4 μm) in mucin. Mucin from one patient grew up inside the peritoneal cavity of mice and human *KRAS* was identified in mucin cfDNA, but not in plasma. All mucins showed the same bacterial profile. Cytokine levels were slightly altered in mice.

**Conclusions:** The three aPMP patients included in this study shared some common aspects: the absence of tumor cells in mucin, the presence of *KRAS* mutated cfDNA in mucin, and the absence of this tumor-derived mutation in the bloodstream, providing additional information to the routine pathological examinations and suggesting that mucin cfDNA could potentially play a role in aPMP recurrence and prognosis.

**Keywords:** acellular pseudomyxoma peritonei, droplet digital PCR, *KRAS*, liquid biopsy, mucin

Received: 30 January 2020; revised manuscript accepted: 28 April 2020.

## Introduction

Pseudomyxoma peritonei (PMP) is an uncommon peritoneal malignancy characterized by the accumulation of large amounts of mucin in the abdominal cavity, associated with a perforated appendicular mucinous neoplasm.<sup>1</sup> PMP has been classified as a rare disease (ORPHA26790)<sup>2</sup> because its incidence is 1–2 per million per year,<sup>3</sup> and the proportion of PMP cases presenting

acellular mucin varies among different studies, ranging from 9.8 to 16.8%.<sup>4–8</sup> Although there are mucinous tumors with different origins which can resemble the clinical characteristics of PMP, such as those found in the ovary, colon, pancreas and urachus, currently this disorder is defined by its appendicular origin.<sup>9</sup> PMP does not follow the typical patterns of a malignant disease, it rarely invades the lymph nodes or metastasizes outside

*Ther Adv Med Oncol*

2020, Vol. 12: 1–12

DOI: 10.1177/  
1758835920928233

© The Author(s), 2020.  
Article reuse guidelines:  
sagepub.com/journals-  
permissions

Correspondence to:  
**Damián García-Olmo**  
Chief of the Department of  
Surgery, New Therapies  
Laboratory, Health  
Research Institute-  
Fundación Jiménez  
Díaz University Hospital  
(IIS-FJD), Avda. Reyes  
Católicos, 2, Madrid,  
28040, Spain

Department of Surgery,  
School of Medicine,  
Universidad Autónoma  
de Madrid (UAM), Madrid,  
Spain Department of  
Surgery, Fundación  
Jiménez Díaz University  
Hospital, Madrid, Spain  
[damián.garcía@uam.es](mailto:damián.garcía@uam.es)

**Susana Olmedillas-López**  
New Therapies Laboratory,  
Health Research Institute-  
Fundación Jiménez Díaz  
University Hospital (IIS-  
FJD), Madrid, Spain

**Delia Cortés-Guiral**  
**Pedro Villarejo**  
**Irene López Rojo**  
**Héctor Guadalajara**  
Department of Surgery,  
Fundación Jiménez Díaz  
University Hospital,  
Madrid, Spain

**Soledad García**  
**Gómez-Heras**  
Faculty of Health  
Science, Rey Juan Carlos  
University, Alcorcón,  
Madrid, Spain

**Mariano García-Arranz**  
New Therapies Laboratory,  
Health Research Institute-  
Fundación Jiménez Díaz  
University Hospital (IIS-  
FJD), Madrid, Spain

Department of Surgery,  
School of Medicine,  
Universidad Autónoma  
de Madrid (UAM), Madrid,  
Spain



of the abdominal cavity; however, it frequently results in a progressive disease and even death if untreated.

The term mucin without epithelial cells or acellular mucin was recently included in the classification of PMP provided by the Peritoneal Surface Oncology Group International (PSOGI).<sup>10</sup> For PMP with acellular mucin or acellular pseudomyxoma peritonei (*aPMP*), in spite of treating a tumor without cells, cytoreductive surgery (CRS) with hyperthermic intraperitoneal chemotherapy (HIPEC) has been established as the ‘up-front’ treatment.<sup>11,12</sup> If all the mucin is not removed, recurrence generally occurs, even though the mucin does not have cells.<sup>13</sup> Long-term follow-up peritoneal recurrences after surgical treatment are 4–20%,<sup>14,15</sup> systemic relapse is extremely infrequent in *aPMP*.<sup>8</sup> The reason why peritoneal recurrence occurs in the form of PMP after removal of the primary tumor, even after complete CRS and HIPEC remains unknown and it is a relevant question.<sup>16</sup>

How can a ‘tumor without cells’ grow? Liquid biopsy involves the detection of cancer-derived molecular biomarkers, such as tumor cells or cell-free nucleic acids (cfNA) in biological fluids, mainly blood.<sup>17,18</sup> It can be used to determine the histological properties of the original tumor as well as its genetic profile for diagnosis, prognosis and the prediction of the response to therapies. For *aPMP*, this procedure could be the only way to obtain information about the original tumors due to a lack of cells for analysis. Hence, liquid biopsy could constitute a way to understand the oncological progression of this intriguing tumor. *KRAS* mutations are frequent in the tumor tissue of all types of PMP and in the appendicular primary tumor.<sup>19,20</sup> The adverse impact of *KRAS* tissue mutations on the prognosis of PMP has been reported.<sup>21</sup> In addition, *KRAS* mutations of the tumor tissues have been associated with the existence of extracellular mucin,<sup>22–24</sup> although they have not yet been described in the mucin itself.

The goal of this study is to verify if it is possible to detect tumor cell-free DNA (*KRAS* mutation) in the acellular mucin of these patients by liquid biopsy, in order to add to the knowledge of this ‘cancer without cells’, to help understand its growth and potential therapeutic decisions. All tumors in these patients showed a *KRAS* mutation, allowing for the tracking of this marker by

liquid biopsy studies both in plasma and in mucin, including in animal models.

## Materials and methods

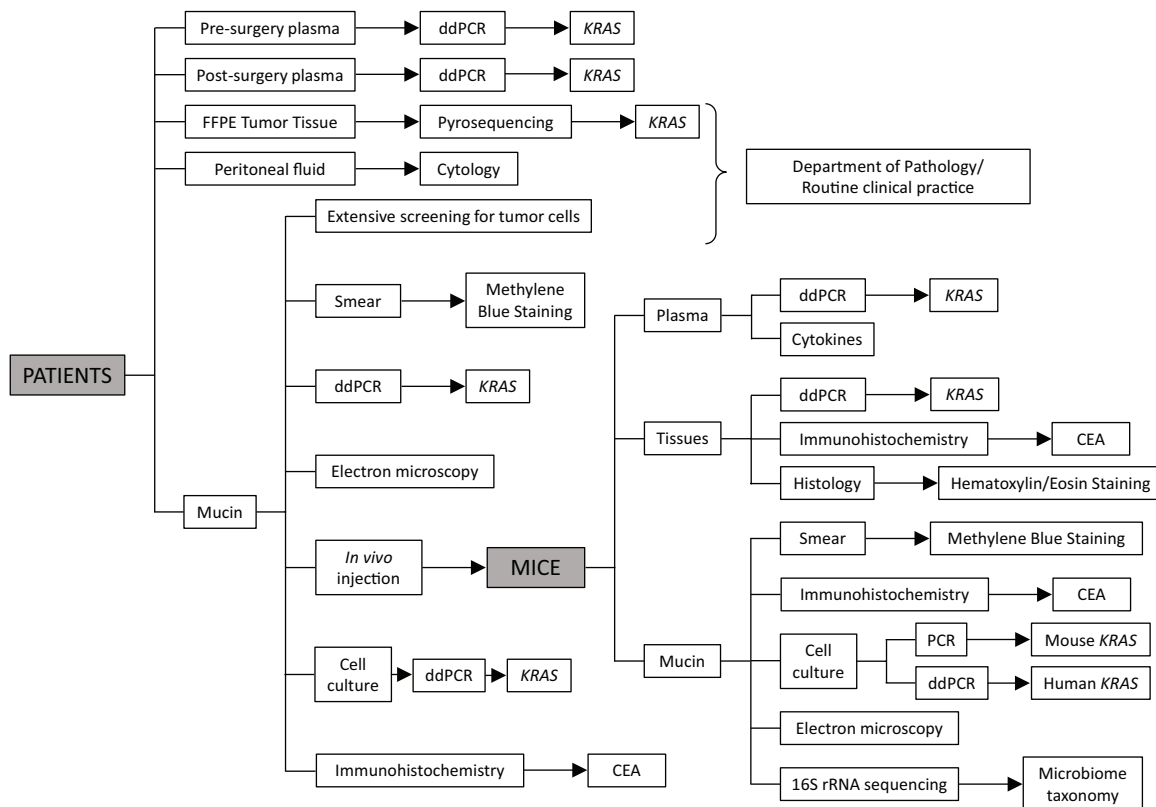
### Patients

Twenty-six patients underwent CRS with HIPEC between April 2016 and May 2017 at Fundación Jiménez Díaz University Hospital (FJD). Written informed consent was obtained from all patients included in this study. The Ethics Committee for Clinical Research of Fundación Jiménez Díaz University Hospital (FJD) reviewed and approved the protocol and the informed consent form for this study, with approval number PIC 75/2016\_FJD. Eleven patients showed the mutated *KRAS* gene. From this series, three patients were diagnosed as *aPMP*. Pathological analysis showed a low-grade appendiceal mucinous neoplasm (according to the PSOGI consensus for classification and pathological reporting of pseudomyxoma peritonei and associated appendiceal neoplasia)<sup>5,10</sup> and *aPMP* (see the section of *Clinical records* in the Supplemental Methods).

### Methods

**Human samples.** The analysis of *KRAS* mutations in formalin-fixed, paraffin embedded (FFPE) tumor tissue was performed in accordance with routine practice at the Department of Pathology at Fundación Jiménez Díaz University Hospital, by pyrosequencing in a PyroMark Q24 instrument (Qiagen, Hilden, Germany) using the Therascreen *KRAS* Pyro kit, according to the manufacturer’s protocols. Blood samples were collected in ethylenediamine tetraacetic acid (EDTA) tubes prior to and 48 hours after surgery. They were processed in less than 2 hours as previously described.<sup>25</sup> Blood was first centrifuged at 1800g for 10 minutes at room temperature, then the plasma fraction was transferred to a fresh tube without disturbing the cell fraction and it was further centrifuged at 3000g for 10 minutes. Plasma from the second centrifugation was aliquoted and stored at –80°C until analysis.

Peritoneal fluid recovered from abdominal lavage using saline solution immediately after laparotomy was examined by the pathologist looking for the presence of tumor cells (cytology) in accordance with the routine clinical practice at the Department of Pathology of our institution. Mucin samples were collected from the abdominal cavity during



**Figure 1.** Experimental workflow. Pre and post-surgery plasma and mucin were collected from the three patients. The Department of Pathology determined *KRAS* mutations in tumor tissue and screened mucin and peritoneal fluid for the presence of tumor cells according to the routine clinical practice in our hospital. The different detection techniques applied in the research lab to each sample are shown. Mucin collected from patients was injected in mice. Plasma, tissues and mucin were collected from mice at the end of the experiment and the analyses performed in these samples are also detailed in the scheme. CEA, carcinoembryonic antigen; ddPCR, droplet digital polymerase chain reaction; FFPE, formalin-fixed, paraffin-embedded.

the cytoreductive surgery in sterile containers and subjected to clinico-pathological examination accordingly. Part of the volume of mucin recovered was sent to the research lab for *in vitro* and *in vivo* assays (Figure 1). It was aliquoted to cryovials under sterile conditions; 3–7 ml of fresh mucin was processed for cell isolation and culture (see Supplemental Methods).

**Xenograft.** Eight to 9-week-old female C57BL/6J and NOD.Cg-Prkdc<sup>scid</sup>I12rg<sup>tm1Wjl</sup>/SzJ (NSG, JAX) mice were used. Mice were purchased from Charles River (Barcelona, Spain). The protocol was approved by the Ethics Committee for Animal Research of Fundación Jiménez Díaz University Hospital (FJD) and the Dirección General de Medio Ambiente, Comunidad de Madrid (PROEX 007/18). All experimental procedures were undertaken in the animal research facilities of FJD in compliance with European and Spanish laws for the use of laboratory animals (European

Union Directive 2010/63/UE and Real Decreto RD53/2013, respectively). Mice had free access to food and water *ad libitum*.

Mucin samples were injected in both mouse strains in duplicate ( $n=2$ ), with the exception of patient 23, from whom there was mucin available to be injected only in one mouse of each strain (see Supplemental Methods for details on injection procedure).

Mice were monitored until they were euthanized 3 weeks later (22–26 days). Then, plasma from mice was collected and a necropsy was performed to screen for the presence of mucin inside the abdominal cavity. In those cases where mucin was found, it was collected and divided into aliquots for cell culture, cryopreservation and fixation with glutaraldehyde for electron microscopy. Mucin and tissue biopsies from the abdominal wall, omentum and pancreatic tissues were processed

for histological analysis and immunohistochemistry for carcinoembryonic antigen (CEA) detection (Figure 1).

*Electron microscopy.* We analyzed mucins from patients, and from two immunocompetent mice and two immunosuppressed mice inoculated with the same sample of human mucin (the only patient who had experienced a recurrence). For the ultrastructural study, samples were cut into  $\leq 1 \text{ mm}^3$  blocks and immersed for 2 hours in 2% phosphate buffered glutaraldehyde. They were then washed in phosphate buffer and post-fixed with 2% osmium tetroxide for 1 hour. After dehydration in a graded acetone series, they were embedded in Spurr, cut into semithin slices (5.5–1 micron thick) using a LeicaUltra-cut R ultramicrotome, and stained with Richardson's methylene blue for light microscopy study. Likewise, ultrathin slices (70 nm thick) were stained with a water-based solution of 2% uranyl acetate and lead citrate for study under a JEOL (JEM-1010, JEOL Ltd., Tokyo, Japan) electron microscope.

*Histological and immunohistochemical analyses.* The first study was an extension or smear of human and mouse mucin. A small amount of mucin was subjected to a centrifugation at 2000 rpm for 10 minutes, a monolayer of cells was created on a slide and allowed to dry. Slides were observed in the optical microscope and to study the number of cells and formed elements present, a methylene blue staining was carried out.

For histological studies, tissue samples of  $5 \text{ mm}^3$  were fixed in 10% formaldehyde at room temperature, embedded in paraffin and cut into 5-micron-thick slices in a Micron HM360 microtome. Sections were stained with hematoxylin-eosin. All were studied under a Zeiss Axiophot 2 microscope and photographed with an AxiocamHRc camera.

In the immunohistochemistry of the mouse samples with human anti-CEA antibody, histology sections and smears were deparaffinized and rehydrated before the endogenous peroxidase activity was blocked with hydrogen peroxide  $\text{H}_2\text{O}_2$  (0.3%) in methanol. The slides were rinsed with phosphate buffered saline (PBS) and incubated with primary antibodies in a moist chamber at room temperature. The primary antibody used was anti-CEA human antibody (ref. MA5-15070; Thermo Fisher Scientific Waltham, MA, USA), 1/1000.

These sections were included with biotinylated anti-rabbit IgG (Dako, Agilent Technologies, Santa Clara, CA, USA) for 25 minutes at room temperature, rinsed with PBS and immersed for 25 minutes in avidin peroxidase. The immunostaining product was developed using di-aminobenzidine. Counter-staining was performed with hematoxylin. The specificity of the immunohistochemical procedure was checked by the incubation of sections with non-immune serum instead of primary antibody.

*DNA extraction.* DNA was extracted from human plasma with the QIAamp Circulating Nucleic Acid Kit (Qiagen), following the manufacturer's instructions with a minor modification: proteinase K incubation was prolonged to 1 hour instead of 30 minutes. The starting volume of plasma was 3 ml (except in case of the 48-hour plasma of patient 26, of which there was only 1 ml available). DNA was eluted in  $50 \mu\text{l}$  of buffer AVE (Qiagen). DNA extraction from the plasma of mice was performed using the Nucleospin Plasma XS kit (Macherey-Nagel GmbH & Co., KG, Düren, Germany). The starting volume of plasma ranged from 170 to  $240 \mu\text{l}$  and DNA was eluted in  $30 \mu\text{l}$  of elution buffer.

DNA was isolated from 2–4 ml mucin using two different protocols. The non-digestion protocol consisted of an initial homogenization of mucin in liquid nitrogen and DNA extraction using the DNeasy Blood and Tissue kit (Qiagen), following the manufacturer's protocol. The digestion protocol started with a 30-minute incubation with an equal volume of 0.2% (w/v) type I collagenase (Gibco, Invitrogen Life Technologies San Diego, CA, USA) at  $37^\circ\text{C}$ , with constant shaking. After enzyme inactivation and a PBS wash, mucin was resuspended in fresh medium and subjected to a density gradient centrifugation with Ficoll-Paque (Amersham Biosciences, Uppsala, Sweden) at  $400g$  for 40 minutes at room temperature. After washing, mucin was homogenized with liquid nitrogen for DNA extraction with the DNeasy Blood and Tissue kit (Qiagen), following the manufacturer's instructions. In both protocols, DNA from mucin was eluted in  $50 \mu\text{l}$  of buffer AE (Qiagen).

Isolation of DNA from mucin and tissue biopsies obtained from the mice was performed with the DNeasy Blood and Tissue kit (Qiagen), following the manufacturer's protocol.

**Table 1.** ddPCR custom assay designed for human *KRAS* G12D mutation detection in mouse samples.

Assay	Forward sequence	Reverse sequence	Probe sequence	Fluorophore
Mut	AAGGCCTGCTGAAAATGACTG	GGTCCTGCACCAGTAATATGCA	TGCCTACGCCATCAGCTCCAAC	FAM
WT	AAGGCCTGCTGAAAATGACTG	GGTCCTGCACCAGTAATATGCA	TGCCTACGCCACCAGCTCCAAC	HEX

Mut, mutation; WT, wild-type.

For taxonomic analysis, DNA from mucin microbiota was isolated using the QIAamp DNA Fast Stool Mini kit (Qiagen) following the manufacturer's protocol.

DNA was extracted from the cells with the DNeasy Blood and Tissue kit (Qiagen) following the manufacturer's instructions.

The DNA concentration and purity were measured using NanoDrop (ND-2000 UV-Vis Spectrophotometer; Nanodrop Technologies Inc., Waltham, MA, USA).

*Detection of KRAS mutations.* *KRAS* G12D and G13D mutations were analyzed in patient plasma pre and post-surgery, mucin (digested and non-digested), cells cultured from mucin, plasma from one immunocompetent and one immunocompromised mouse (both treated with mucin), cells cultured from mucin of treated mice, and tissue biopsies obtained from treated mice.

Droplet digital polymerase chain reaction (ddPCR) analyses were performed using the QX200 Droplet Digital PCR System (Bio-Rad, Hercules, CA, USA). *KRAS* G12D and G13D mutations were detected with their respective Prime-PCR ddPCR Mutation Detection Assays (Bio-Rad). Thermal cycling was performed in a C1000 Touch Thermal Cycler (Bio-Rad) running 40 cycles of 94°C for 30 seconds and 55°C for 1 minute. The maximal input volume of DNA was included in the ddPCR reaction mix for plasma samples and four replicates of each sample were assayed. Mucin samples were tested on different DNA input amounts. Four replicates of each sample were analyzed (except for patient 14, from whom there was sufficient amount only for two replicates).

DNA from LS-174T (heterozygous *KRAS* G12D) and HCT-116 (heterozygous *KRAS* G13D) human adenocarcinoma cell lines were used as positive controls. These cell lines were

kindly provided by the Translational Oncology Division, OncoHealth Institute, IIS-FJD, which had previously purchased them from American Type Culture Collection (ATCC) (ATCC, Manassas, VA, USA). The *KRAS* wild-type control DNA was obtained from healthy donor peripheral blood mononuclear cells.

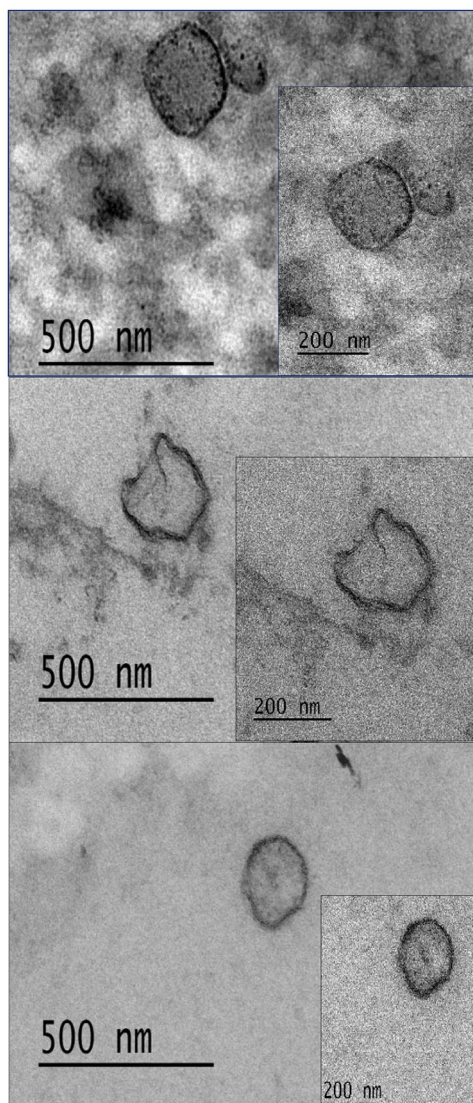
A custom assay was designed to detect human *KRAS* G12D mutation in samples obtained from mice in order to avoid the cross-reactivity of the commercially available Prime-PCR ddPCR Mutation Detection Assay (Bio-Rad) with mouse *KRAS* (see Table 1).

Thermal cycling was performed running 40 cycles of 94°C for 30 seconds and 62.8°C for 1 minute.

In the case of samples from mouse origin (except for plasmas, which were tested at maximal input volume of DNA in the ddPCR reaction mix), up to 500 ng of DNA were analyzed per ddPCR reaction. In these cases, a restriction enzyme (Hind III, Thermo Fisher Scientific) was included in the ddPCR reaction mix as recommended by the manufacturer. Two to four replicates of each sample were assayed.

Results were analyzed using the Quantasoft v.1.7 software (Bio-Rad). A *Z* test was used to compare the merged concentration of mutated copies/μl reaction between samples and wild-type controls assuming that concentrations follow a normal distribution. A *p*-value < 0.05 was considered statistically significant.

*Identification of murine cells cultured from mucin by conventional PCR.* Conventional PCR was used to identify the murine origin of cells isolated from mucin recovered from mice abdomen. Primers spanned a 140-bp region of murine *KRAS* gene and had the following sequences: 5'-CTTGTGGTG-GTTGGAGCTGG-3' for forward primer and 5'-CTGCCGTCCTTTACAAGCGCA-3' for the reverse primer. PCR was run for 35 cycles of 94°C



**Figure 2.** Three examples of different microparticles found in mucin. In all cases we observed  $<0.4\ \mu\text{m}$  microparticles that have a double membrane envelope. TEM,  $60,000\times$  and  $100,000\times$ .

for 1 minute and  $63^\circ\text{C}$  for 30 seconds. Peripheral blood mononuclear cells from a human healthy donor and NIH-3T3 cells (an immortalized cell line from mouse origin purchased from ATCC) were used as negative and positive controls of mouse *KRAS* amplification, respectively. The amplification was confirmed by electrophoresis on 2% agarose gel stained with RealSafe nucleic acid staining solution (Durviz S.L., Valencia, Spain).

**Taxonomic analysis of mucin microbiota.** A 16S Metagenomics Survey, sequencing on an Illumina's MiSeq system (Illumina, San Diego, CA, USA), was performed for human mucin and for

that recovered from inoculated immunocompetent and immunosuppressed mice.

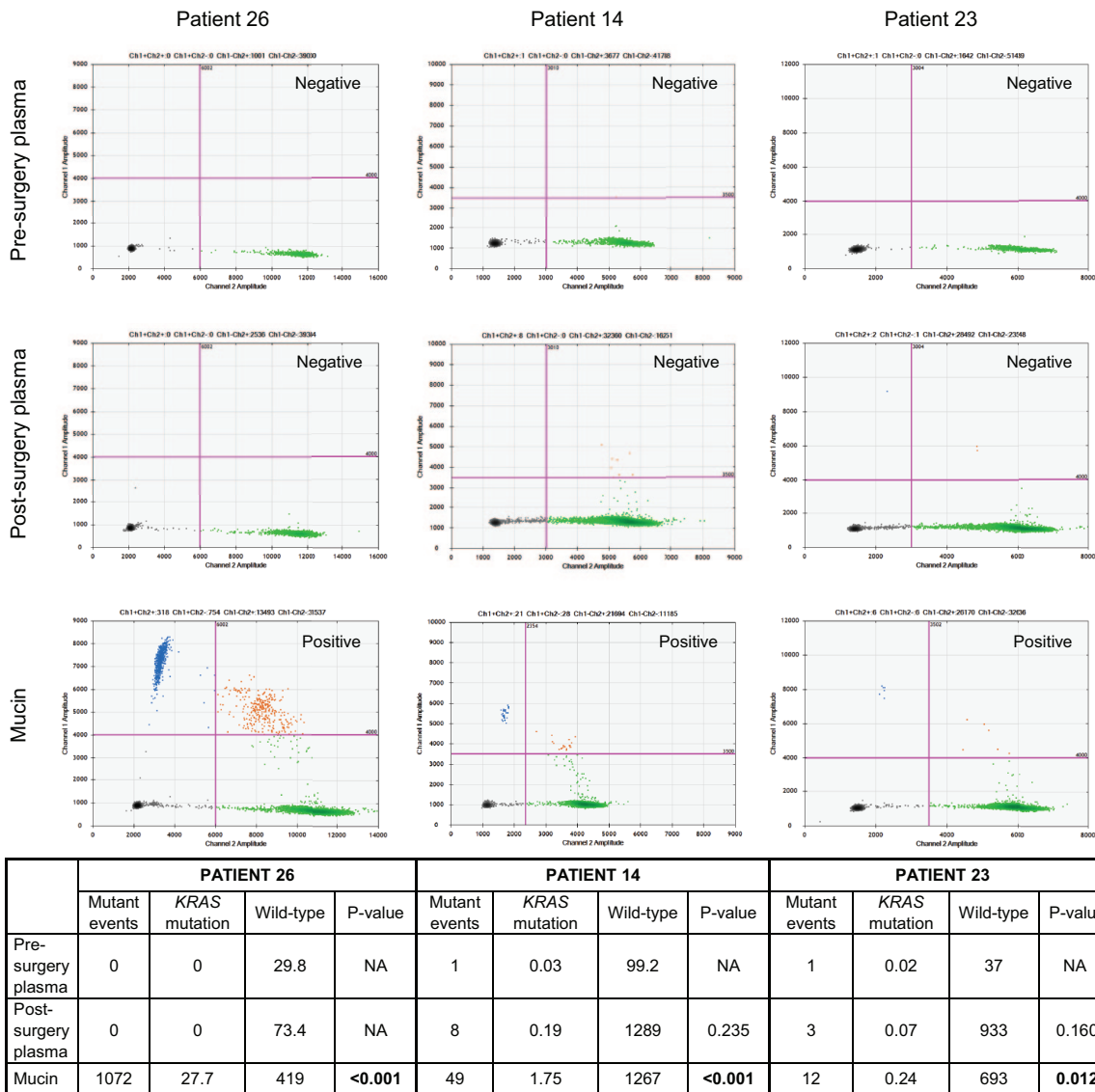
**Cytokine analysis.** For cytokine level analysis, plasmas from all mice were collected and processed as described above for human plasma samples. Finally, analysis was performed using the Bio-Plex Pro mouse cytokine, chemokine and growth factor magnetic bead-based assays (Bio-Rad) in a Luminex system (Milliplex MAP, Merck), according to the manufacturer's instructions.

## Results

The three patients included in this study had a low-grade appendiceal mucinous neoplasm as determined by the pathology. This mucin was classified as acellular by the pathologists in the three cases. A great amount of acellular mucin, both free and attached to abdominal structures, was also found in the samples of all patients. No malignant cells were found in the peritoneal fluid in any sample at the pathological examination by the Department of Pathology of our institution, in accordance with the routine clinical practice, and all analyzed samples were negative on the immunohistochemical screening for CEA. The electron microscopy of the mucins confirmed the absence of tumor cells. Only microparticles (diameter  $<0.4\ \mu\text{m}$ ), with the appearance of exosomes, were detected (Figure 2).

Pre and post-surgery plasma was negative in all cases; *KRAS* mutations were not detected circulating in the blood of any patient (Figure 3). Some positive events were detected in post-surgery plasma from patients 14 and 23, but the difference in concentration with respect to the WT-only control was not statistically significant ( $p=0.235$  and  $p=0.160$ , respectively). When mucin was used for cell culture during *in vitro* assays at our research lab, growth of the cells from the mucin samples was observed in two cases (patients 14 and 23); however, they did not contain a *KRAS* mutation. By contrast, the *KRAS* mutation was detected in mucin cfDNA from all patients, with an exact concordance with the mutation detected in the original tumor (Figure 3).


Regarding clinical evolution, no patient experienced either peritoneal relapse or systemic metastasis during the follow-up period (31–38 months) (see the section of *Clinical records* in the Supplemental Methods).



**Figure 3.** The ddPCR results of plasma and mucin samples from the three patients. Results shown are the merged values of all replicates performed from each sample (four wells per sample, except in the case of mucin from patient 14, with two replicates). Mutation-positive droplets (FAM, channel 1, upper-left corner), wild-type droplets (HEX, channel 2, bottom-right corner), double-positive droplets (upper-right corner), and double-negative droplets (bottom-left corner) are shown in the 2D-amplitude plots. The table below shows the total number of mutant events in the metawell, and *KRAS* mutation and wild-type values of concentration in copies/ $\mu$ l reaction. Pre and post-surgery plasma samples were negative in all cases. Some positive events were detected in post-surgery plasma from patients 14 and 23, but the difference in concentration with respect to the WT-only control was not statistically significant ( $p=0.235$  and  $p=0.160$ , respectively). Samples with less than three positive droplets in the merged replicates were classified as negative without the need for statistical analysis (indicated as 'NA'). The mutation was detected in cDNA extracted from mucin of the three patients. A  $p$ -value  $< 0.05$  was considered statistically significant. cDNA, cell-free DNA; ddPCR, droplet digital polymerase chain reaction; WT, wild-type.

All samples of mucin analyzed by 16S metagenomics showed the same bacterial profile at the phylum, class, order, and family levels (see Supplemental Figure 1).

The inoculation of mucin from the different patients in the immunocompetent mice did not generate significant changes in the majority of the cytokines and chemokines studied in the



**Figure 4.** (a) A photograph from the patient who showed peritoneal recurrence of aPMP. An implant of mucin in the dermis was also detected (upper right corner). Avatar model: injection of human mucin from aPMP patients in the abdominal cavity of (b) immunodeficient mice (NSG) and (c) immunocompetent mice (C57BL/6J). After 3 weeks, the mucin from the patient who experienced recurrence had grown up in both mouse strains inoculated (d–e).  
aPMP, acellular pseudomyxoma peritonei; NSG, NOD *scid* gamma.

plasma; the exception was a decrease in IL17; and a decrease in Eotaxin. The inoculation in NOD *scid* gamma (NSG) mice did not generate significant changes either, with a downward trend in the values of regulatory and proinflammatory cytokines, with the exception of IL17 that tended to increase. As for the chemokines, no differences were observed except for a slight increase in Eotaxin. When we injected mucin from the patient who had experienced a recurrence, a significant increase in all cytokines and chemokines was observed in the blood of the immunocompetent mice, but not in the NSG mice (raw data of each metabolite concentration are shown in Supplemental Table 1).

Mucin accumulated in the peritoneal cavity of both sets of mice (immunosuppressed and immunocompetent) inoculated with mucin from the recurrent patient (Figure 4). In these mice, cells were identified in the mucin that had grown into their peritoneum. These cells were from mouse origin, as they contained murine *KRAS*, which was amplified by conventional PCR. However, these cells did not contain the human *KRAS* gene, mutated or not. Remains of human *KRAS* were identified in the grown mucin. Human *KRAS* (mutated or not mutated) was not detected circulating in the blood of the mice. Histological studies in the peritoneal tissues did not show any alterations (Supplemental Figure 2).

## Discussion

aPMP is an intriguing tumor due to its trend to peritoneal recurrence despite the inability to detect tumor cells.<sup>15</sup> As such, it is a mystery as to how this mucinous tumor grows. Even so, there are some facts that help us to understand this phenomenon and that could suggest novel strategies of treatment.

The first main fact is that, despite the absence of tumor cells, if all mucinous material is not removed during surgical treatment, the tumor eventually recurs.<sup>2</sup> All samples of acellular mucin from the three patients included in this study bear oncogenic markers (*KRAS* mutations) that are probably transported by exosomes (Figure 2). Moreover, the highest presence of tumor particles in mucin was detected in the only patient who had experienced a recurrence, and her mucin grew up in a peritoneal xenograft. It might be inferred that these ‘tumor mucin microparticles’ could signal the peritoneal tissue to produce mucin. Therefore, if mucin is allowed to remain at the peritoneum it will continue to accumulate, including in a xenograft model. The aPMP microenvironment (particularly stromal tissue) plays a major role in disease progression.<sup>26</sup> This fact could explain why patients with aPMP, who have undergone limited surgery, have a high risk of tumor recurrence.<sup>27</sup> In our study, *KRAS* mutations were only detected in the extracellular mucin of patients, and hence we could infer that



this genetic material acted as an intercellular messenger.

In order to assess if the microbiota could influence the persistence of mucin, we performed a metagenomic analysis of mucin DNA; however, no differences were found. Gilbreath *et al.*<sup>28</sup> reported the presence of a ‘core microbiome’ in the mucin of 11 patients with PMP. In our study, all mucins, from mice and humans, shared a common microbiome with the same dominant phyla previously described. Whether these bacteria have a role in PMP carcinogenesis is still unknown; however, it has been hypothesized that they could contribute to create an intense and sustained inflammation that promotes malignancy.<sup>29,30</sup> Notably, antibiotic treatment has been shown to reduce bacterial density and improve survival in peritoneal mucinous carcinomatosis (PMCA) patients without affected lymph nodes.<sup>28</sup> High levels of cytokines in the mice with mucin from the recurrent patient might be associated with mucin mass; in NSG mice elevated levels of Eotaxin might be implicated in the neutrophil cell recruitment into mucin observed in smears.

The second main fact in this study was that *KRAS* mutations were not found in the bloodstream of patients. These are the only mutations that have been analyzed in this study. It would be of great interest to perform a comprehensive characterization of the whole molecular profile of *aPMP*, specially using ultra-deep next-generation sequencing techniques, as these patients may probably harbor many molecular alterations other than *KRAS* that could potentially be monitored by liquid biopsy. It has previously been reported (using both *in vitro* and in mouse models) that multiple control gateways selectively regulate the release of specific circulating tumor DNA (ctDNA) species in the blood regardless of their variant allele frequencies in tissue.<sup>31</sup> Thus, although *KRAS* mutations have not been detected in plasma of any of our patients, we cannot exclude the possibility that other tumor-related molecular aberrations may be present in the bloodstream. However, we hypothesize that detection of cell-free DNA in mucin together with the observation of exosome-like structures in this fluid by electron microscopy might point to a local character of *aPMP*, rather than being a systemic disease, which may be more linked to the presence of ctDNA in plasma. In fact, as part of this suggestion of a local disease, we have detected *KRAS* mutated cfDNA in peritoneal fluid (in the abdominal lavage performed

prior to HIPEC) in two out of the three patients included in this study (data not shown). Hence, in accordance with the genomestasis theory,<sup>32</sup> distant metastases should not develop, and indeed, metastatic events have not been recorded in our patients during the follow-up period ( $34.6 \pm 3.5$  months, mean  $\pm$  standard deviation). In agreement with these results, van Eden *et al.* recently showed that serum protein tumor markers (CEA and CA19-9) are not usually increased in patients with acellular mucin.<sup>8</sup>

Our results showed that the three *aPMP* patients included in this study shared some common aspects, such as the absence of tumor cells in the mucin, both by pathology and *in vitro* studies, the presence of *KRAS* mutated cfDNA in mucin, and the absence of this tumor-derived mutation in the bloodstream. The data presented here regarding liquid biopsy in patients bearing *aPMP* are thought-provoking but still preliminary. We had a limited number of cases due to the rare disorder nature of this malignancy and, particularly, because of the low incidence of acellular mucin in PMP. Furthermore, patients should also bear specific *KRAS* mutations to be eligible for analysis by our method. For all these reasons, this work was not intended to conclude any general molecular/cellular features of *aPMP*. Further studies should be performed by multicenter collaboration to corroborate these preliminary results.

If these results are validated in a larger cohort of patients, including a broader spectrum of tumor-derived molecular alterations, different lines of action could be suggested to optimize the treatment and follow-up of these patients. First, complementary analyses of cell-free DNA in mucin by ddPCR and/or by high-throughput next-generation sequencing methods could be added to the pathology examinations routinely performed in clinical practice. The absence of cells in the peritoneal mucin has been identified as a favorable prognosis factor; however, cases of locoregional recurrence and death are still reported among these patients. Baratti *et al.*<sup>5</sup> suggested in a previous study that neoplastic elements could have remained unnoticed during pathological examination. This possibility seems feasible if we consider that, in many cases, surgical specimens account for several kilograms of mucin to be screened by the pathologist. Here we propose that, even when tumor cells are undetectable, liquid biopsy from mucin could be more representative of the whole mucin contained in the peritoneal

cavity, and it might provide a sensitive tool for detection of potential recurrence triggering factors.

Second, as tumor cells are presumably not involved in the growth of acellular mucin in sight of our results, it might be suggested that intraperitoneal chemotherapy could be considered as inappropriate, although the results of this study are insufficient to draw any conclusion in this regard. Additional experiments in animal models comparing HIPEC *versus* non-HIPEC treatment are needed in order to address this point specifically. However, it should be noted that there is an increasing concern about the efficacy of HIPEC, in particular, oxaliplatin-based HIPEC.<sup>33</sup> In two abstracts presented at ASCO and ESSO 2018 conferences from the PRODIGE7 trial, it has been shown that the addition of this chemotherapeutic agent did not improve survival but it did increase complication rates.<sup>34,35</sup> Similar results have been reported for ProphyloChip<sup>36</sup> and COLOPEC<sup>37</sup> trials. Thus, one could hypothesize that future treatment in *aPMP* cases might preferentially be aimed at destroying cell-free DNA in mucin. Further studies should be specifically designed to test this hypothesis. Third, we could also infer that the hyperthermic lavage at the end of peritonectomy may be beneficial, as it could contribute to reduce the load of tumor cell-free DNA in the peritoneal cavity, and hence interfere with the action of oncogenes in extracellular vesicles. The molecular mechanisms by which these tumor mucin microparticles could trigger PMP recurrence, if so, still need to be elucidated.

To our knowledge, this is the first time that an oncogenic mutation (*KRAS*) has been detected in mucin cell-free DNA of *aPMP* patients but not in plasma. No patients experienced recurrence during the follow-up period in this study. However, the persistence of mucin in the peritoneal cavity of xenografted mice suggests that mucin cfDNA could potentially play a role in *aPMP* recurrence. The potential clinical value of mucin cfDNA as a prognostic biomarker in this disease might deserve further investigation.

### Acknowledgments

The authors would like to acknowledge the OncoHealth Institute at Fundación Jiménez Díaz University Hospital, directed by Prof Jesús García-Foncillas. The authors would also like to thank Luz Vega-Clemente for her assistance in the xenograft model and Ana Díez for her

technical support. The authors would also like to acknowledge Dr Ignacio Mahillo-Fernández for his help on statistical analysis.

### Conflict of interest

The authors declare that there is no conflict of interest.

### Funding

The authors disclosed receipt of the following financial support for the research, authorship, and/or publication of this article: This study was funded by a grant from the 'FIS-ISCI-III-FEDER' [Fondo de Investigaciones Sanitarias-Instituto de Salud Carlos III-Fondo Europeo de Desarrollo Regional (European Regional Development Fund)], Ministry of Health, Spain (grant number PI17/01233).

### ORCID iD

Damián García-Olmo  <https://orcid.org/0000-0002-9369-2338>

### Supplemental material

Supplemental material for this article is available online.

### References

1. Rizvi SA, Syed W and Shergill R. Approach to pseudomyxoma peritonei. *World J Gastrointest Surg* 2018; 10: 49–56.
2. Amini A, Masoumi-Moghaddam S, Ehteda A, *et al.* Secreted mucins in pseudomyxoma peritonei: pathophysiological significance and potential therapeutic prospects. *Orphanet J Rare Dis* 2014; 9: 71.
3. Smeenk RM, van Velthuysen ML, Verwaal VJ, *et al.* Appendiceal neoplasms and pseudomyxoma peritonei: a population based study. *Eur J Surg Oncol* 2008; 34: 196–201.
4. Huang Y, Alzahrani NA, Chua TC, *et al.* Histological subtype remains a significant prognostic factor for survival outcomes in patients with appendiceal mucinous neoplasm with peritoneal dissemination. *Dis Colon Rectum* 2017; 60: 360–367.
5. Baratti D, Kusamura S, Milione M, *et al.* Validation of the recent SOGI pathological classification of pseudomyxoma peritonei in a single-center series of 265 patients treated by cytoreductive surgery and hyperthermic intraperitoneal chemotherapy. *Ann Surg Oncol* 2018; 25: 404–413.

6. Reghunathan M, Kelly KJ, Valasek MA, *et al.* Histologic predictors of recurrence in mucinous appendiceal tumors with peritoneal dissemination after HIPEC. *Ann Surg Oncol* 2018; 25: 702–708.
7. Solomon D, Bekhor E, Leigh N, *et al.* Surveillance of low-grade appendiceal mucinous neoplasms with peritoneal metastases after cytoreductive surgery and hyperthermic intraperitoneal chemotherapy: are 5 years enough? A multisite experience. *Ann Surg Oncol* 2020; 27: 147–153.
8. van Eden WJ, Kok NFM, Snaebjornsson P, *et al.* Factors influencing long-term survival after cytoreductive surgery and hyperthermic intraperitoneal chemotherapy for pseudomyxoma peritonei originating from appendiceal neoplasms. *BJS Open* 2019; 3: 376–386.
9. Carr NJ, Bibeau F, Bradley RF, *et al.* The histopathological classification, diagnosis and differential diagnosis of mucinous appendiceal neoplasms, appendiceal adenocarcinomas and pseudomyxoma peritonei. *Histopathology* 2017; 71: 847–858.
10. Carr NJ, Cecil TD, Mohamed F, *et al.* A consensus for classification and pathologic reporting of pseudomyxoma peritonei and associated appendiceal neoplasia: the results of the peritoneal surface oncology group international (PSOGI) modified Delphi process. *Am J Surg Pathol* 2016; 40: 14–26.
11. Horvath P, Yurttas C, Birk P, *et al.* Cellularity in low-grade pseudomyxoma peritonei impacts recurrence-free survival following cytoreductive surgery and hyperthermic intraperitoneal chemotherapy. *Langenbecks Arch Surg* 2018; 403: 985–990.
12. Bouquot M, Dohan A, Gayat E, *et al.* Prediction of resectability in pseudomyxoma peritonei with a new CT score. *Ann Surg Oncol* 2018; 25: 694–701.
13. Sugarbaker PH, Fernández-Trigo V and Shamsa F. Clinical determinants of treatment failure in patients with pseudomyxoma peritonei. *Cancer Treat Res* 1996; 81: 121–132.
14. Yantiss RK, Shia J, Klimstra DS, *et al.* Prognostic significance of localized extra-appendiceal mucin deposition in appendiceal mucinous neoplasms. *Am J Surg Pathol* 2009; 33: 248–255.
15. Young RH, Gilks CB and Scully RE. Mucinous tumors of the appendix associated with mucinous tumors of the ovary and pseudomyxoma peritonei. A clinicopathological analysis of 22 cases supporting an origin in the appendix. *Am J Surg Pathol* 1991; 15: 415–429.
16. Yan TD, Bijelic L and Sugarbaker PH. Critical analysis of treatment failure after complete cytoreductive surgery and perioperative intraperitoneal chemotherapy for peritoneal dissemination from appendiceal mucinous neoplasms. *Ann Surg Oncol* 2007; 14: 2289–2299.
17. Siravegna G, Marsoni S, Siena S, *et al.* Integrating liquid biopsies into the management of cancer. *Nat Rev Clin Oncol* 2017; 14: 531–548.
18. García-Casas A, García-Olmo DC and García-Olmo D. Further the liquid biopsy: gathering pieces of the puzzle of genomestasis theory. *World J Clin Oncol* 2017; 8: 378–388.
19. Hara K, Saito T, Hayashi T, *et al.* A mutation spectrum that includes GNAS, KRAS and TP53 may be shared by mucinous neoplasms of the appendix. *Pathol Res Pract* 2015; 211: 657–664.
20. Nummela P, Saarinen L, Thiel A, *et al.* Genomic profile of pseudomyxoma peritonei analyzed using next-generation sequencing and immunohistochemistry. *Int J Cancer* 2015; 136: E282–E289.
21. Pietrantonio F, Perrone F, Mennitto A, *et al.* Toward the molecular dissection of peritoneal pseudomyxoma. *Ann Oncol* 2016; 27: 2097–2103.
22. Kadota K, Yeh YC, D'Angelo SP, *et al.* Associations between mutations and histologic patterns of mucin in lung adenocarcinoma: invasive mucinous pattern and extracellular mucin are associated with KRAS mutation. *Am J Surg Pathol* 2014; 38: 1118–1127.
23. Shibata H, Ohike N, Norose T, *et al.* Mucinous cystic neoplasms lined by abundant mucinous epithelium frequently involve KRAS mutations and malignant progression. *Anticancer Res* 2017; 37: 7063–7068.
24. Gemignani ML, Schlaerth AC, Bogomolny F, *et al.* Role of KRAS and BRAF gene mutations in mucinous ovarian carcinoma. *Gynecol Oncol* 2003; 90: 378–381.
25. Olmedillas-López S, García-Olmo DC, García-Arranz M, *et al.* KRAS G12V mutation detection by droplet digital PCR in circulating cell-free DNA of colorectal cancer patients. *Int J Mol Sci* 2016; 17: 484.
26. Lohani K, Shetty S, Sharma P, *et al.* Pseudomyxoma peritonei: inflammatory responses in the peritoneal microenvironment. *Ann Surg Oncol* 2014; 21: 1441–1447.
27. Honoré C, Caruso F, Dartigues P, *et al.* Strategies for preventing pseudomyxoma peritonei after resection of a mucinous neoplasm

- of the appendix. *Anticancer Res* 2015; 35: 4943–4947.
28. Gilbreath JJ, Semino-Mora C, Friedline CJ, *et al.* A core microbiome associated with the peritoneal tumors of pseudomyxoma peritonei. *Orphanet J Rare Dis* 2013; 8: 105.
29. Semino-Mora C, Liu H, McAvoy T, *et al.* Pseudomyxoma peritonei: is disease progression related to microbial agents? A study of bacteria, MUC2 AND MUC5AC expression in disseminated peritoneal adenomucinosis and peritoneal mucinous carcinomatosis. *Ann Surg Oncol* 2008; 15: 1414–1423.
30. Semino-Mora C, Testerman TL, Liu H, *et al.* Antibiotic treatment decreases microbial burden associated with pseudomyxoma peritonei and affects  $\beta$ -catenin distribution. *Clin Cancer Res* 2013; 19: 3966–3976.
31. Gasparello J, Allegretti M, Tremante E, *et al.* Liquid biopsy in mice bearing colorectal carcinoma xenografts: gateways regulating the levels of circulating tumor DNA (ctDNA) and miRNA (ctmiRNA). *J Exp Clin Cancer Res* 2018; 37: 124.
32. García-Olmo DC, Domínguez C, García-Arranz M, *et al.* Cell-free nucleic acids circulating in the plasma of colorectal cancer patients induce the oncogenic transformation of susceptible cultured cells. *Cancer Res* 2010; 70: 560–567.
33. Narasimhan V, Ooi G, Michael M, *et al.* Colorectal peritoneal metastases: pathogenesis, diagnosis and treatment options – an evidence-based update. *ANZ J Surg*. Epub ahead of print 4 March 2020. DOI: 10.1111/ans.15796.
34. Quenet F, Elias D, Roca L, *et al.* A UNICANCER phase III trial of hyperthermic intra-peritoneal chemotherapy (HIPEC) for colorectal peritoneal carcinomatosis (PC): PRODIGE 7. *J Clin Oncol* 2018; 36 (Suppl. 18): Abstract LBA3503.
35. Quenet F, Elias D, Roca L, *et al.* A UNICANCER phase III trial of hyperthermic intra-peritoneal chemotherapy (HIPEC) for colorectal peritoneal carcinomatosis. PRODIGE 7. *Eur J Surg Oncol* 2019; 45: e17.
36. Goere D, Glehen O, Quenet F, *et al.* Results of a randomized phase 3 study evaluating the potential benefit of a second-look surgery plus HIPEC in patients at high risk of developing colorectal peritoneal metastases (PROPHYLOCHIP-NTC01226394). *J Clin Oncol* 2018; 36 (Suppl. 15): Abstract 3531.
37. Klaver CE, Wisselink DD, Punt CJ, *et al.* Adjuvant HIPEC in patients with colon cancer at high risk of peritoneal metastases: primary outcome of the COLOPEC multicenter randomized trial. *J Clin Oncol* 2019; 37 (Suppl. 4): Abstract 482.