

Haemorrhagic Brain Metastasis From Malignant Pleural Mesothelioma: A Rare Case

Review began 10/06/2022

Review ended 10/12/2022

Published 10/16/2022

© Copyright 2022

Furtado et al. This is an open access article distributed under the terms of the Creative Commons Attribution License CC-BY 4.0., which permits unrestricted use, distribution, and reproduction in any medium, provided the original author and source are credited.

Cleofina Furtado¹, Sachin Srivastava¹, Sanjeev Nayak¹, Changrez Jadun¹, Zafar Hashim¹

1. Department of Diagnostic and Interventional Radiology, University Hospitals of North Midlands NHS Trust, Stoke On Trent, GBR

Corresponding author: Cleofina Furtado, cleofinafurtado@gmail.com

Abstract

Malignant pleural mesothelioma (MPM) typically has a short median survival of only a few months from diagnosis, with death usually due to thoracic disease. This has led to the belief in the past that mesothelioma rarely has distant metastasis, with cerebral metastasis accounting for only 3%. The multiple cases of brain metastasis from MPM recorded so far were discovered after death at autopsy. This report describes a rare case of known malignant mesothelioma with distant haemorrhagic metastasis to the brain, reviews current literature about its metastatic potential to the brain and discusses prognosis and management. We also review the imaging evaluation in known MPM patients with suspected intracranial involvement and describe typical imaging findings of parenchymal brain metastasis on computed tomography (CT) and magnetic resonance imaging (MRI).

Categories: Cardiac/Thoracic/Vascular Surgery, Radiology, Oncology

Keywords: computed tomography (ct), metastasis, cerebral, haemorrhagic, malignant pleural mesothelioma (mpm)

Introduction

Malignant pleural mesothelioma (MPM) is a rare, highly invasive tumour that arises from the mesothelial cells of the pleura or peritoneum and is associated with a bad prognosis [1]. The liver, adrenal gland, kidney, and bone are the most common metastatic locations [2]. Although MPM is known to spread hematogenously, intracranial metastases are rare to the brain [3]. This is due to the short survival clinical course of MPM [4]. The multiple cases of brain metastasis from MPM recorded were discovered after death [5-7].

This is a rare case of known MPM with distant brain metastases, which encourages further radiological investigations in the presence of symptoms. The incidence of haemorrhagic brain metastasis from known MPM, histological features, treatment options, prognosis and imaging findings are also briefly discussed.

Case Presentation

A 67-year-old female patient presented to the emergency department with progressive bilateral lower limb weakness and unsteadiness for a few days, followed by a recent episode of loss of consciousness.

She was known to have malignant pleural mesothelioma (MPM) of the biphasic histologic subtype for which she underwent five cycles of chemotherapy (carboplatin and pemetrexed). It was discontinued due to toxicity and poor performance status, following which her disease progressed. The original pleural biopsy showed strong expression of Cam 5.2, MNF 116 and calretinin within epithelioid and spindle cells. CK5/6 was positive in the epithelioid tumour cell population, with WT-1 showing similar expression and additional focal expression in spindle cells. See Figure 1 for chest radiographs.

How to cite this article

Furtado C, Srivastava S, Nayak S, et al. (October 16, 2022) Haemorrhagic Brain Metastasis From Malignant Pleural Mesothelioma: A Rare Case. Cureus 14(10): e30345. DOI 10.7759/cureus.30345

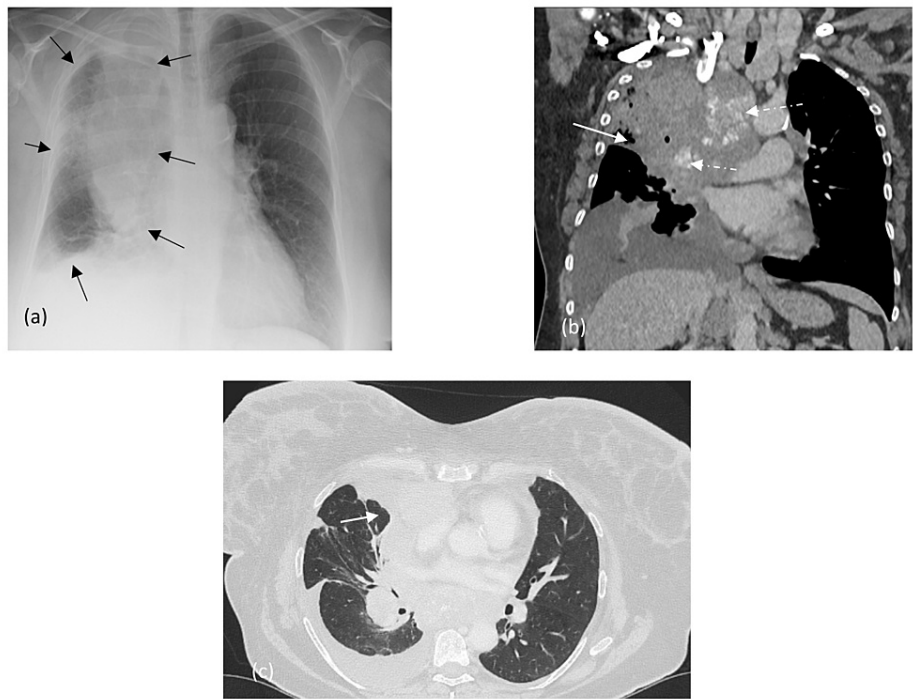

FIGURE 1: Chest radiographs

(a): Circumferential pleural thickening of the right lung (within black arrows) with decreased lung volume. CT chest with contrast (b) and (c): nodular pleural thickening that encases the right lung with extension onto the mediastinal pleura (white solid arrows) and into the fissures. Large calcified pathologically enlarged mediastinal and hilar lymph nodes (white dashed arrows) are seen.

Plain computed tomography (CT) head (Figure 2) performed for neurological impairment demonstrated two discrete supra and infratentorial hyperdense lesions with surrounding oedema. The subsequent magnetic resonance imaging (MRI) (Figure 3) demonstrated well-defined, intra-axial mass lesions in the left parietal and posterior fossa cerebellar hemisphere. It contained blood products with T1 hyperintensity on T1-weighted imaging (T1WI). The lesions depicted peripheral contrast enhancement with blooming artefact on gradient echo (GRE) sequence reflecting haemorrhagic nature.

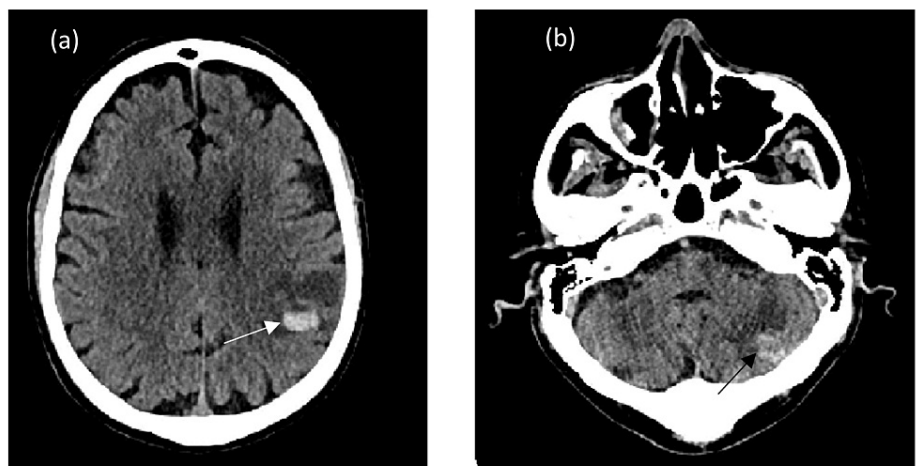


FIGURE 2: Plain axial CT demonstrating left posterior parietal (white solid arrow in (a)) and left cerebellar hemisphere (black arrow in (b)) with high attenuating haemorrhagic metastatic deposits and surrounding oedema

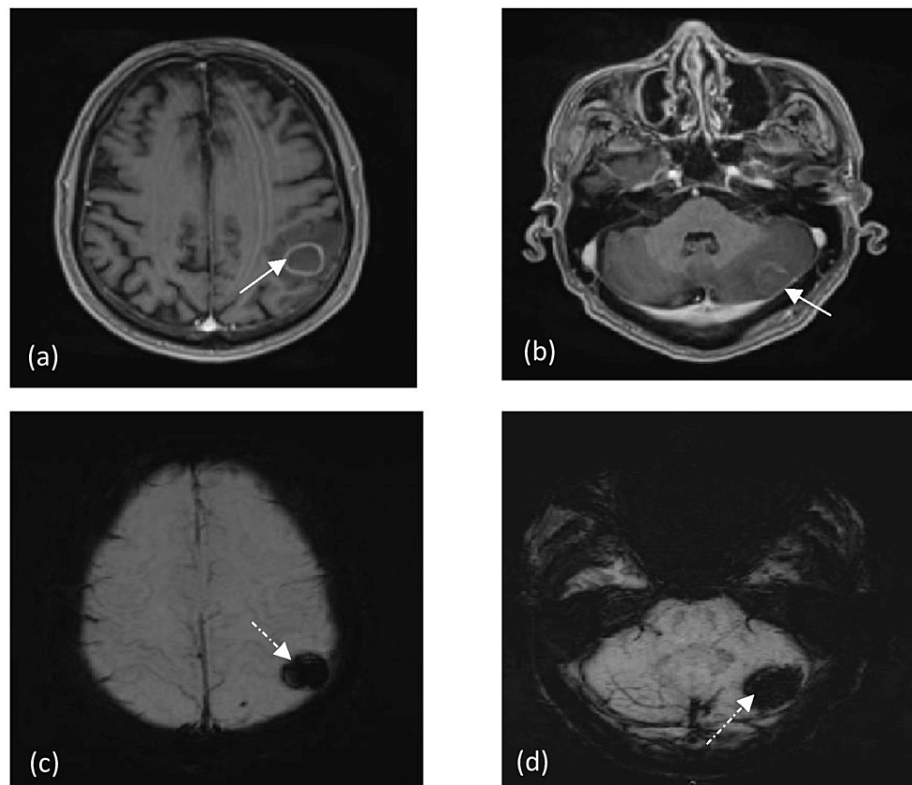


FIGURE 3: MRI brain

T1WI axial contrast MRI (a and b) images depicting supra and infratentorial brain metastases with peripheral contrast enhancement and surrounding oedema (white solid arrows). Susceptibility weight imaging (SWI) (c and d) demonstrating corresponding blooming artefact (white dashed arrows) keeping with hemosiderin deposition.

Staging CT (chest, abdomen and pelvis) did not show any other synchronous primary tumour. Hence, a diagnosis of intracranial metastasis was made secondary to the known pleural mesothelioma. Given her primary malignancy progression, intolerance to chemotherapy and the multiplicity of brain metastasis, a discussion about prognosis and care was held with her and her family. The patient refused any aggressive treatment. Palliative radiation therapy and dexamethasone were administered in order to minimize oedema around the tumour and thereby relieve symptoms. The patient passed away eight months later.

Discussion

Perineural spread, leptomeningeal carcinomatosis and, most commonly, haematogenous spread leading to parenchymal deposits are all possible mechanisms for central nervous system (CNS) metastases from MPM [8]. The clinical characteristics differ depending on the CNS area involved, with the cerebral cortex, cerebellum, intracranial meninges and spinal cord being the most commonly involved regions, and the midbrain, pons, or brainstem being less common [9].

In a retrospective analysis of 164 MPM patients, 67% were diagnosed with distant metastatic disease, with the highest frequency involving bone (19%), viscera (14%), contralateral lung (35%) and peritoneum (22%), and only (5%) with brain metastases [10]. A further case series from post-mortem examinations of 318 patients quantified brain metastases at 3% [11], whilst another systematic review reported a very low incidence of only 2.7% in autopsy patients [9].

The histologic appearance of MPM brain metastases may be comparable to glioblastoma multiforme [12]. There are three histological kinds of MPM: sarcomatous, epithelial and biphasic [2]. Patients with sarcomatous histology have the poorest prognosis, and conventional treatments, such as surgery or chemotherapy, are ineffective [13]. According to the existing research, in one review study, 11% of patients with cerebral metastases exhibited histological differences from the initial tumour, indicating histological differentiation into a more aggressive histological subtype [10].

CT is the first-line imaging modality in patients with new neurological impairments and known primary malignancy [14]. Acute haemorrhagic metastases to the brain appear hyperdense on non-contrast CT and are surrounded by varying vasogenic oedema [15]. Contrast-enhanced CT and MRI have higher sensitivity,

demonstrating T1WI hyperintensity, depending on the age of haemorrhage associated with diffusion restriction and peripheral enhancement on contrast administration [15]. T2*-weighted GRE MRI is a sensitive tool for the early detection of metastases displaying haemorrhagic changes [16]. Our case demonstrates these typical features, indicating that brain metastases from MPM are typically haemorrhagic. Similar findings of brain metastasis with intratumoral haemorrhage secondary to MPM as a primary have been reported by Ishikawa et al. [3]. When haemorrhagic brain metastasis is the initial presentation, radiologists and clinicians should be aware of this pattern of brain metastasis and consider MPM as a differential when looking for the primary.

MPM with brain metastasis is considered a fatal disease [17], with most patients discharged without therapy or with only anti-oedema medication [18]. Other treatment options include resection, whole-brain radiation, stereotactic radiotherapy, systemic corticosteroids, intrathecal or systemic chemotherapy, and immunotherapy, but only a few instances have shown a therapeutic response [10]. Moreover, it is noted that brain metastasis can reappear within five to seven months following surgical or after regression in response to systemic treatment [3,19].

Local disease progression rather than distant metastasis is the most common cause of death [20]. The overall survival of patients with brain metastases is noted to be worse than that of patients without brain metastases with a mean survival of three months [3,18].

Conclusions

MPM patients will continue to live longer as a consequence of newer, more advanced treatments, and hence more individuals will be diagnosed with metastatic disease. Therefore, it is critical to recognise mesothelioma's metastatic potential, particularly cerebral metastasis, which was previously only an autopsy finding. In patients presenting with neurological symptoms, haemorrhagic brain metastases should be considered as one of the differential diagnoses with known background history. At the same time, MPM should be included as a differential when brain metastasis with intratumoral haemorrhage is the initial presentation. The prognosis for malignant mesothelioma remains clinical and tumour histology-dependent.

Additional Information

Disclosures

Human subjects: Consent was obtained or waived by all participants in this study. **Conflicts of interest:** In compliance with the ICMJE uniform disclosure form, all authors declare the following: **Payment/services info:** All authors have declared that no financial support was received from any organization for the submitted work. **Financial relationships:** All authors have declared that they have no financial relationships at present or within the previous three years with any organizations that might have an interest in the submitted work. **Other relationships:** All authors have declared that there are no other relationships or activities that could appear to have influenced the submitted work.

References

1. El Molla M, Gragnaniello C, Al-Khawaja D, Chiribao-Negri C, Eftekhari B: Cerebral metastasis from malignant pleural mesothelioma. *J Surg Case Rep*. 2013, 2013:rjt087. [10.1093/jscr/rjt087](https://doi.org/10.1093/jscr/rjt087)
2. Kitai R, Kabuto M, Kawano H, Uno H, Kobayashi H, Kubota T: Brain metastasis from malignant mesothelioma—case report. *Neurol Med Chir (Tokyo)*. 1995, 35:172-4. [10.2176/nmc.35.172](https://doi.org/10.2176/nmc.35.172)
3. Ishikawa T, Wanifuchi H, Abe K, Kato K, Watanabe A, Okada Y: Brain metastasis in malignant pleural mesothelioma presenting as intratumoral hemorrhage. *Neurol Med Chir (Tokyo)*. 2010, 50:1027-30. [10.2176/nmc.50.1027](https://doi.org/10.2176/nmc.50.1027)
4. Kaye JA, Wang AM, Joachim CL, Seltzer SE, Cibas E, Skarin A, Antman KH: Malignant mesothelioma with brain metastases. *Am J Med*. 1986, 80:95-7. [10.1016/0002-9343\(86\)90054-9](https://doi.org/10.1016/0002-9343(86)90054-9)
5. Thimmareddygar DM, Ramahi A, Singh B, Chan KH, Kaur P: A biphasic malignant pleural mesothelioma with intracranial metastasis. *Chest*. 2020, 158:1263. [10.1016/j.chest.2020.08.1150](https://doi.org/10.1016/j.chest.2020.08.1150)
6. Falconieri G, Grandi G, DiBonito L, Bonifacio-Gori D, Giarelli L: Intracranial metastases from malignant pleural mesothelioma. Report of three autopsy cases and review of the literature. *Arch Pathol Lab Med*. 1991, 115:591-5.
7. Cheeseman SL, Ranson MR: Cerebral metastases in malignant mesothelioma: a case report. *Eur J Cancer Care (Engl)*. 1999, 8:104-6. [10.1046/j.1365-2354.1999.00146.x](https://doi.org/10.1046/j.1365-2354.1999.00146.x)
8. Chari A, Koliass AG, Allinson K, Santarius T: Cerebral metastasis of a malignant pleural mesothelioma: a case report and review of the literature. *Cureus*. 2015, 7:e241. [10.7759/cureus.241](https://doi.org/10.7759/cureus.241)
9. Miller AC, Miettinen M, Schrupp DS, Hassan R: Malignant mesothelioma and central nervous system metastases. Report of two cases, pooled analysis, and systematic review. *Ann Am Thorac Soc*. 2014, 11:1075-81. [10.1513/AnnalsATS.201404-165BC](https://doi.org/10.1513/AnnalsATS.201404-165BC)
10. Collins DC, Sundar R, Constantinidou A, et al.: Radiological evaluation of malignant pleural mesothelioma - defining distant metastatic disease. *BMC Cancer*. 2020, 20:1210. [10.1186/s12885-020-07662-y](https://doi.org/10.1186/s12885-020-07662-y)
11. Finn RS, Brims FJ, Gandhi A, Olsen N, Musk AW, Maskell NA, Lee YC: Postmortem findings of malignant pleural mesothelioma: a two-center study of 518 patients. *Chest*. 2012, 142:1267-75. [10.1378/chest.11-3204](https://doi.org/10.1378/chest.11-3204)
12. Wroński M, Burt M: Cerebral metastases in pleural mesothelioma: case report and review of the literature. *J Neurooncol*. 1993, 17:21-6. [10.1007/BF01054270](https://doi.org/10.1007/BF01054270)
13. Ray M, Kindler HL: Malignant pleural mesothelioma: an update on biomarkers and treatment. *Chest*. 2009,

- 136:888-96. [10.1378/chest.08-2665](https://doi.org/10.1378/chest.08-2665)
14. Barajas RF Jr, Cha S: Imaging diagnosis of brain metastasis. *Prog Neurol Surg.* 2012, 25:55-73. [10.1159/000331174](https://doi.org/10.1159/000331174)
 15. Ginaldi S, Wallace S, Shalen P, Luna M, Handel S: Cranial computed tomography of malignant melanoma. *AJR Am J Roentgenol.* 1981, 136:145-9. [10.2214/ajr.136.1.145](https://doi.org/10.2214/ajr.136.1.145)
 16. Murata Y, Itoh S, Morio K, Sasaki T, Mizobuchi H, Shimizu K, Yoshida S: Hemorrhagic cerebral metastases from thyroid cancer on T2*-weighted gradient echo MRI. *Magn Reson Imaging.* 2004, 22:435-9. [10.1016/j.mri.2004.01.017](https://doi.org/10.1016/j.mri.2004.01.017)
 17. Yamagishi T, Fujimoto N, Miyamoto Y, et al.: Brain metastases in malignant pleural mesothelioma. *Clin Exp Metastasis.* 2016, 33:231-7. [10.1007/s10585-015-9772-8](https://doi.org/10.1007/s10585-015-9772-8)
 18. Akıncı Özyürek B, Erdoğan Y, Ünver M, Şahin Özdemirel T, Demirağ F, Kaya S: Malignant pleural mesothelioma and central nervous system metastases: report of two cases. *Respir Case Rep.* 2018, 7:9-12. [10.5505/respircase.2018.82687](https://doi.org/10.5505/respircase.2018.82687)
 19. Colleoni M, Liessi G, Avventi C, Pancheri F, Sgarbossa G, Vicario G, Manente P: Response to chemotherapy of brain metastases from malignant pleural mesothelioma. *Tumori.* 1996, 82:456-8. [10.1177/030089169608200509](https://doi.org/10.1177/030089169608200509)
 20. Hurmuz P, Zorlu F, Cansız C, Emri S: Malignant pleural mesothelioma with brain metastasis. *J BUON.* 2009, 14:123-5.