

Gliosarcoma: a study of four cases

Yildiz Güney, Ayşe Hiçsönmez, Sercan Yılmaz, Yasemin Güzle Adas, Meltem Nalca Andrieu

Department of Radiation Oncology,
Faculty of Medicine, Ankara University,
Turkey

Abstract

Gliosarcomas (GS) are highly malignant and rare tumors of the central nervous system with a poor prognosis. We report here on four patients with GS, the median survival for whom was 9.25 months. Prognosis of GS remains poor, and a multidisciplinary approach (surgery, radiation therapy, and chemotherapy) seems to be associated with slightly more prolonged survival times.

Introduction

Gliosarcomas (GS) are highly malignant and rare tumors of the central nervous system with a poor prognosis. They account for 2-8% of all glioblastoma multiforme (GBM), and 0.48% of all intracranial tumors.^{1,4} They are primary brain tumors characterized by a biphasic pattern displaying both glial and mesenchymal components.⁵ GS are predominant in males, and usually affect patients in the fifth to sixth decades of life. The clinical presentation, natural history, and radiologic profile are similar to those of primary glioblastoma.^{2,6,7}

The clinical presentation varies according to location and tumor size. The most common symptoms are seizures, focal neurological deficits, headache, and other symptoms related to increased intracranial pressure.^{7,8} Treatment includes tumor resection, postoperative radiation therapy, and sometimes chemotherapy.^{4,8} At present, radiation therapy (60-66 Gy in 30 fractions) and chemotherapy are the standard of care for GB and, consequently, for GS.^{9,10}

Between January 1999 and October 2004, 66 patients underwent radiation therapy for newly diagnosed GBM at the Department of Radiation Therapy, University of Ankara. We report here on four patients with GS, retrieved from this series. The aim of this retrospective study is to analyze clinical features, treatment, and survival.

Materials and Methods

Patients

In the GS group, two patients were male and two were female. The mean age was 56.5 ± 4.65 years (range, 50-61 years). Three of the patients had headache, one had motor deficit, and all were on steroid medication during treatment. Preoperative computed tomography (CT) scans or magnetic resonance imaging (MRI) was performed in all patients (Figure 1). The locations, all supratentorial, included left temporal in one, left frontoparietal in two, and right frontoparietal areas and corpus callosum in one patient (Figure 2). Midline shift was not observed.

Treatment

All of the patients underwent tumor resection, which was classified as gross total. The median interval between surgery and the initiation of radiation therapy was 29.5 days (range, 19-38 days). All patients were treated with Cobalt.⁶⁰ Clinical Target Volume (CTV) was established as Gross Tumor Volume (GTV) plus 2-2.5 cm, and 0.5 cm was added as a safety margin for Planning Target Volume (PTV). All of the patients in the GS group received 60 Gy in 30 fractions. Three patients had chemotherapy with temozolomide. All cases tolerated radiation therapy well, without interruption of their treatment because of side effects.

Statistics

Survival was calculated from the first day of radiation therapy, using the method of Kaplan and Meier.¹¹

Results

Clinical features

Patient characteristics are shown in Table 1.

Survival

All patients in the GS group had died at the time of analysis. The median survival was 9.25 months.

Discussion

In our present report, GS accounted for 5.5% of all GBM, with a mean age of 56.5 ± 4.65 years. The age distribution was similar to that of GBM patients. Other reported series determined that GS account for 2-8% of all GBM with ages ranging from the fifth to the sixth decades.^{1,4,12,13} This is in accordance with our

Correspondence: Ayşe Hiçsönmez, Ankara University School of Medicine, Department of Radiation Oncology, Cebeci Hospital, Ankara, Turkey. E-mail: asonmez@medicine.ankara.edu.tr

Key words: gliosarcoma, radiation therapy, survival.

Received for publication: 18 June 2009;

Revision received: 10 May 2010.

Accepted for publication: 11 May 2010.

This work is licensed under a Creative Commons Attribution 3.0 License (by-nc 3.0).

©Copyright Y. Güney et al., 2010
Licensee PAGEPress, Italy
Rare Tumors 2010; 2:e37
doi:10.4081/rt.2010.e37

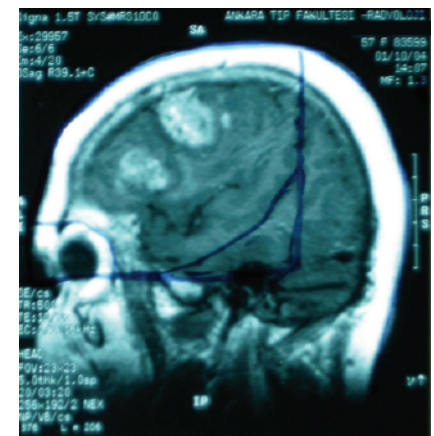


Figure 1. Cranial magnetic resonance image of Case #1.

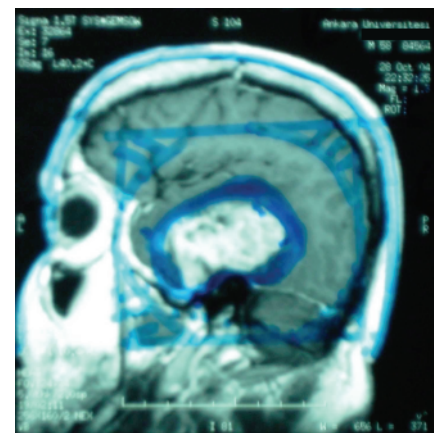


Figure 2. Cranial magnetic resonance image of Case #3.

Table 1. Characteristics, treatment, and survival of patients in the gliosarcoma group.

Case	Age	Sex	Presenting symptoms	Site of lesion	Tumor size (cm)	Resection	S-RT (days)	RT	CT	Survival (months)
1	58	Male	Headache	Left temporal	Unknown	Gross	38	+	+	6 months
2	50	Female	Headache	Left frontoparietal	3×3×4	Gross	27	+	–	2.5 months
3	57	Female	Motor deficit	Right frontoparietal and corpus callosum	3.5×2.8×3.2 1.8×1×1	Gross	32	+	+	12.5 months
4	61	Male	Headache	Left frontoparietal	6.5×3.5×3	Gross	19	+	+	22 months

S, surgery; RT, radiation therapy; CT, chemotherapy; S-RT, interval surgery-radiation therapy; Gross, gross total resection.

authors,^{2,13} the majority of our GS patients presented with frontoparietal lesions, but the small numbers in our study make this difficult to interpret. In spite of some reports of metastatic spread,^{13,14} none of the tumors of our patients evolved with systemic dissemination.

Several authors reported significant biological similarities in the behavior of GS and GBM,^{2,4,6,13} suggesting that the same treatment should be applied for these two kinds of tumor. On the basis of this observation, we have treated patients with GS as those with GBM. All of our GS patients underwent gross total resection and all had postoperative radiation therapy. The median interval between surgery and the initiation of radiation therapy was 29.5 days (range, 19-38 days). Three of the four patients received chemotherapy with temozolomide, and one had no chemotherapy because of her poor clinical condition (Karnofsky Performance Status 40).

Morantz *et al.*³ commented on the effect of chemotherapy on the outcome. They found a mild increase in survival in GS patients with additional chemotherapy (36 weeks) compared with radiation therapy alone (33 weeks). In our study, median survival was 9.25 months for our patients. The median survival in GS patients ranges from 6 to 14.8 months in the reported studies.^{1,3,4,13,15,16} It has to be noted that survival times were calculated from different points of time: date of onset, diagnosis, surgery, or first day of radiation therapy. Heesters *et al.*¹⁷ reported a median survival of seven months for their six GS patients. Lutterbach *et al.*⁴ analyzed 12 GS patients and 410 GBM patients and found that the median survival was 11.5 months for the GS patients compared with 8.1 months for the entire GBM group. Perry *et al.*¹³ analyzed 25 GS patients and reported a median survival of six months. Meis *et al.*² analyzed 26 GS patients and 1453 GBM patients and report a median survival of 8.3 months for GS patients compared with 9.6 months for the GBM patients; their findings were contrary to the other reports.

In the reported studies,^{3,4,13} all patients died within 20 months. In the study of Galanis *et*

al.,¹² only one of 18 patients survived for 29 months. Winkler *et al.*¹⁸ presented a rare case of GS in a 61-year-old woman who was stable over 22 years. We concluded that despite the fact that our cases were very few, the presenting clinical features, treatment, and survival of GS are similar to that of GBM. Although the prognosis of GS remains poor, a multidisciplinary approach (surgery, radiation therapy, and chemotherapy) seems to be associated with slightly more prolonged survival times.

References

1. Meis JM, Ho KL, Nelson JS. Gliosarcoma: a histologic and immunohistochemical reaffirmation. *Mod Pathol* 1990;3:19-24.
2. Meis JM, Martz KL, Nelson JS. Mixed glioblastoma multiforme and sarcoma: a clinicopathologic study of 26 Radiation Therapy Oncology Group cases. *Cancer* 1991;67:2342-9.
3. Morantz RA, Feigin I, Ransohoff J. Clinical and pathological study of 24 cases of gliosarcoma. *J Neurosurg* 1976;45:398-408.
4. Lutterbach J, Guttenberger R, Pagenstecher A. Gliosarcoma: a clinical study. *Radiother Oncol* 2001;61:57-64.
5. Boerman RH, Anderl K, Herath J, et al. The glial and mesenchymal elements of gliosarcomas share similar genetic alterations. *J Neuropathol Exp Neurol* 1996; 55:973-81.
6. Ohgaki H, Biernat W, Reis R, et al. Gliosarcoma. In: *Pathology and genetics of tumors of the nervous system*. Kleihues P, Cavenee WK, eds. Lyon: IARC Press; 2000, pp 42-4.
7. Maiuri F, Stella L, Benvenuti D, et al. Cerebral gliosarcomas: correlation of computed tomographic findings, surgical aspect, pathological features, and prognosis. *Neurosurgery* 1990;26:261-7.
8. Pakos EE, Goussia AC, Zina VP, et al. Multifocal gliosarcoma: a case report and review of the literature. *J Neurooncol* 2005;74:301-4.
9. Laperriere N, Zuraw L, Cairncross G. Cancer Care Ontario Practice Guidelines Initiative Neuro-Oncology Disease Site Group. Radiotherapy for newly diagnosed malignant glioma in adults: a systematic review. *Radiother Oncol* 2002;64:259-73.
10. Stupp R, Mason WP, van den Bent MJ, et al. Radiotherapy plus concomitant and adjuvant temozolomide for glioblastoma. *European Organisation for Research and Treatment of Cancer Brain Tumor and Radiotherapy Groups; National Cancer Institute of Canada Clinical Trials Group*. *N Engl J Med* 2005;352:987-96.
11. Kaplan ES, Meier PJ. Non-parametric estimation from incomplete observations. *J Am Stat Assoc* 1958;53:457-81.
12. Galanis E, Buckner JC, Dinapoli RP, et al. Clinical outcome of gliosarcoma compared with glioblastoma multiforme: North Central Cancer Treatment Group results. *J Neurosurg* 1998;89:425-30.
13. Perry JR, Ang LC, Bilbao JM, et al. Clinicopathologic features of primary and post-radiation cerebral gliosarcoma. *Cancer* 1995;75:2910-8.
14. Smith DR, Hardman IM, Earle KM. Contiguous glioblastoma multiforme and fibrosarcoma with extracranial metastasis. *Cancer* 1969;24:270-6.
15. Salvati M, Caroli E, Raco A, et al. Gliosarcomas: analysis of 11 cases; do two subtypes exist? *J Neurooncol* 2005;74:59-63.
16. Cervoni L, Celli P. Cerebral gliosarcoma: prognostic factors. *Neurosurg Rev* 1996; 19:93-6.
17. Heesters MA, Wijrdeman HK, Struikmans H, et al. Brain tumor delineation based on CT and MR imaging. Implications for radiotherapy treatment planning. *Strahlenther Onkol* 1993;169:729-33.
18. Winkler PA, Büttner A, Tomezzoli A, et al. Histologically repeatedly confirmed gliosarcoma with long survival: review of the literature and report of a case. *Acta Neurochir (Wien)* 2000;142:91-5.