


3.0 T MRI findings of 104 hips of asymptomatic adults: from non-runners to ultra-distance runners

Laura Maria Horga ¹, Johann Henckel,² Anastasia Fotiadou,² Anna Di Laura,² Anna Hirschmann,³ Alister Hart^{1,2}

To cite: Horga LM, Henckel J, Fotiadou A, *et al.* 3.0 T MRI findings of 104 hips of asymptomatic adults: from non-runners to ultra-distance runners. *BMJ Open Sport & Exercise Medicine* 2021;**7**:e000997. doi:10.1136/bmjsem-2020-000997

Accepted 10 May 2021

ABSTRACT

Objectives To determine and compare the health status of hip joints of individuals undertaking various lengths of long-distance running and of those who are not running.

Methods Fifty-two asymptomatic volunteers underwent bilateral hip 3.0 Tesla MRI: (1) 8 inactive non-runners; (2) 28 moderately active runners (average half a marathon (21 km)/week) and (3) 16 highly active runners (\geq marathon (42 km)/week). Two musculoskeletal radiologists reported the hip MRI findings using validated scoring systems. Study participants completed a Hip disability and Osteoarthritis Outcome Score (HOOS) questionnaire to indicate their perceived hip function.

Results The MRI findings show that there were no significant differences among inactive non-runners, moderately active runners and highly active runners in the amount of labral abnormalities ($p=0.327$), articular cartilage lesions ($p=0.270$), tendon abnormalities ($p=0.141$), ligament abnormalities ($p=0.519$). Bone marrow oedema was significantly more common in moderately active runners than in non-runners and highly active runners ($p=0.025$), while small subchondral cysts were more common in runners than in non-runners ($p=0.017$), but these were minor/of small size, asymptomatic and did not indicate specific exercise-related strain. Articular cartilage lesions and bone marrow oedema were not found in highly active runners. HOOS scores indicate no hip symptoms or functional problems among the three groups.

Conclusion The imaging findings were not significantly different among inactive non-runners, moderately active runners and highly active runners, in most hip structures, suggesting that long-distance running may not add further damage to the hip joints.

INTRODUCTION

Running races longer than 21 km, including marathons (42 km) and ultramarathons (>42 km), have steadily grown in popularity over the last three decades.^{1 2} Both recreational and competitive running has been on the rise, with the average age of runners being over mid-30 years old and >40% women.³ Despite its multiple cardiorespiratory benefits, long-distance running has been reportedly linked with a concerning risk of

What are the new findings

- ▶ The number of hip joint MRI abnormalities was not significantly different among inactive non-runners, moderately active runners and highly active runners in most structures, including the labrum, articular cartilage, ligaments, tendons. This is the first study on runners' hips of this kind.
- ▶ No chondral defects or bone marrow oedema were found in highly active runners.
- ▶ Only minor non-specific bone marrow abnormalities were more common in runners than in non-runners.

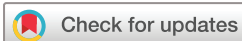How might it impact clinical practice in the future

- ▶ The findings help correct popular misconceptions that long-distance running damages the hip joints, and therefore should be taken into account when making health recommendations.
- ▶ The findings could help reassure individuals who are interested in getting into long-distance running that running is proven to be non-detrimental to hip joints.

lower extremity injuries, ranging from 19% to 80%.⁴ However, this wide range is controversial, considering that scientific evidence remains very limited.⁴

While the knee has received more research attention in the past, as a presumably common site of running-related injuries,⁴⁻¹² very little is known about the health status of runners' hips.⁷ Moreover, it is yet unclear what is the optimal dose of exercise and which running intensity is appropriate to the hip joints. Hip injury rate varies from 3% to 12%,^{4 13-15} due to differences in the definition of injury, type of study population, diagnosis tools.

Historically, specific diagnostic criteria and management tools with regards to hip injuries in athletes have been limited.^{16 17} Recent developments in MRI and hip arthroscopic surgery have resulted in increasing progress in the diagnosis and treatment of non-arthritic hips.¹⁶ In particular, the high resolution



© Author(s) (or their employer(s)) 2021. Re-use permitted under CC BY-NC. No commercial re-use. See rights and permissions. Published by BMJ.

¹Department of Orthopaedics and Musculoskeletal Science, University College London, Stanmore, London, UK

²Royal National Orthopaedic Hospital, Stanmore, London, UK

³Department of Radiology and Nuclear Medicine, University Hospital Basel, Basel, Switzerland

Correspondence to

Dr Laura Maria Horga; laura.horga.17@ucl.ac.uk

3.0 Tesla (T) MRI technology offers clinical benefits in comparison to 1.5 T^{18 19} due to the high sensitivity and specificity in detecting early signs of pathologies.^{20–23}

So far, only a few studies used MRI to document the prevalence of hip abnormalities in asymptomatic individuals^{24–28}; only one study did MRI analysis of runners' hips; however, this focused primarily on MRI changes after a marathon run, included small cohort (n=8), all professional and semi-professional long-distance runners, and used low-resolution unilateral MRI.⁷

The objective of this study was to assess and compare, for the first time, between the hip joint findings of inactive non-runners, moderately active runners and highly active runners on 3.0 T MRI scans. We believe that this assessment will provide a better understanding of whether undertaking various lengths of long-distance running is detrimental to the hips in comparison to inactive non-runners.

METHODS

Study design and participants

This was a prospective cohort study of long-distance runners. The volunteers were recruited from the community of runners in the Greater London area. The study was a collaboration with the organisers of the Richmond Running Festival (Richmond Runfest), who advertised our study on their regular newsletters and included a contact email address for our study. Non-runners were recruited from University College London (UCL) by word of mouth and digital advertising channels. The study was advertised among UCL students and staff through regular newsletters and social media groups. All volunteers were screened with a questionnaire of our inclusion criteria: adults (aged ≥ 18 years old), with neither health nor hip problems and specifically absence of hip pain, hip injury, hip surgery or MRI contraindications. Exclusion criteria were: pregnancy or breast feeding, individuals aged < 18 years, claustrophobia, history of anxiety, panic attacks or known hip problems. All volunteers provided written informed consent before participation.

Fifty-two volunteers met the inclusion criteria and were recruited to the study to undergo a hip MRI. The volunteers ranged from non-runners to ultra-distance runners. The volunteers were divided into three groups: (1) 'inactive non-runners': < 1 hour physical activity, maximum 2 km walking/week; (2) 'moderately active runners': average running activity of half a marathon (21 km)/week; and (3) 'highly active runners: running activity \geq a marathon (42 km)/week.

The final cohort included 8 inactive non-runners, 28 moderately active runners and 16 highly active runners. Moderately active runners reported a running activity of an average of 21 km/week (varying from 17 to 36 km/week), for a total of 3–4 hours of running/week, and never ran a marathon. Highly active runners reported a running activity ≥ 42 km/week (varying from 50 to 85 km/week), for a total amount of median 6 hours of running per week (range: 4–10 hours).

Table 1 Baseline characteristics of study participants

Characteristics	Inactive non-runners (n=8)	Moderately active runners (n=28)	Highly active runners (n=16)
Age (years)*†	25.5 (20–45)	30 (18–58)	34.5 (21–59)
Male:female	5:3	14:14	12:4
Weight (kg)	66.9 \pm 7.2	70.4 \pm 9.6	73 \pm 11.8
Height (cm)	174.5 \pm 9.6	174 \pm 10.2	175.6 \pm 11.1
BMI (kg/m ²)‡	22 \pm 2.6	23.2 \pm 2.3	23.8 \pm 3.5

Values are reported as mean \pm SD for weight, height and BMI.

*Median (range) is reported for age and running experience.

†1/8 (13%) inactive non-runners, 5/28 (18%) moderately active runners and 6/16 (38%) highly active runners were aged ≥ 40 years old, while the rest were aged < 40 years old.

‡1/8 (13%) inactive non-runners, 8/28 (29%) moderately active runners and 4/16 (25%) highly active runners had BMI ≥ 25 kg/m² respectively, and the rest had BMI < 25 kg/m².

BMI, body mass index.

Volunteer characteristics were summarised in [table 1](#).

Participant self-assessment questionnaire

The Hip disability and Osteoarthritis Outcome Score (HOOS) questionnaire²⁹ was completed by volunteers to self-assess their perceived hip joint condition and associated injuries that can result in osteoarthritis at study recruitment. The questionnaire is divided into five sets of questions based on key hip outcomes: pain, other symptoms, function in daily living, hip-related quality of life and function in sport and recreation.

MRI protocol

All volunteers underwent hip 3.0 T non-contrast MRI scans of both hips (Siemens Magnetom Vida Healthineers, Erlangen, Germany) with a dedicated 18 channel ultraflex coil. The imaging protocol was the following: proton density-weighted fat-suppressed (FS) sequences in coronal (repetition time (TR): 4190 ms/echo time (TE): 44 ms; image size/acquisition matrix: 512 \times 512 pixels) and sagittal bilateral planes proton density (FS turbo spin-echo (TSE) TR: 4420/TE: 35 (320 \times 320 pixels)); axial (T1 TSE TR: 27/TE: 10); coronal proton density TSE (TR: 3290/TE: 39); axial proton density (FS TSE TR: 4400/TE: 36 (384 \times 384 pixels)) and Dixon axial four phases TR: 4220/TE: 45; T1 VIBE 3D coronal: TR: 0.1/TE: 4.92. The optimised protocol included Dixon sequences in four phases: in-phase, out-of-phase, water phase and fat phase. The thickness of all slices was 3 mm, and the total acquisition time per scan was 30 min (for both hips).

Imaging analysis

The bilateral MRI scans were evaluated and reported by a senior musculoskeletal radiologist using a picture archiving and communications system workstation. The MR images of a subset of volunteers, that is, 20% of the cohort, were randomly selected for an additional independent evaluation by a second senior musculoskeletal radiologist to assess the reproducibility of the readings. Previous imaging studies included a 10% subset of the

Table 2 Grading systems

Hip feature	Scale of grading system	Reference	
Labrum	0=normal variant such as aplasia or hypoplasia 1=abnormal signal and/or fraying 2=simple tear 3=labrocartilage separation 4=complex tear 5=maceration	SHOMRI ³¹	
Articular cartilage (acetabular, femoral)	0=no loss 1=partial thickness 2=full thickness loss	SHOMRI ³¹	
Subchondral bone marrow (acetabular, femoral)	Oedema 0=no lesion is present 1≤0.5 cm in size 2>0.5 cm but ≤1.5 cm 3>1.5 cm in size	Cysts 0=absent lesion 1≤0.5 cm in size 2>0.5 cm in size	SHOMRI ³¹
Tendons	0=normal 1=tendinosis (intermediate signal, not fluid) 2=low-grade partial thickness tear (<50% tendon fluid signal) 3=high-grade partial thickness tear (≥50% tendon fluid signal) 4=full thickness tear (complete fluid signal)	Chi <i>et al</i> ³²	
Ligaments	0=normal 1=signal abnormalities or fraying 2=partial tear 3=complete tear	SHOMRI ³¹	
Other findings	Binary (present/absent)	–	

Note: SHOMRI, scoring hip osteoarthritis with MRI. The labrum was assessed in four subregions: anterior, posterior, anterosuperior and superior. The articular cartilage and bone marrow were each divided in the acetabular region (four subregions: anterior, posterior, superolateral and superomedial) and femoral region (six subregions: anterior, posterior, lateral, superolateral, superomedial and inferior).

total number of participants in double-reporting³⁰; we doubled this to a 20% subset to increase reliability.

In cases of disagreement between the radiologists' reports, the final score (agreement score) was achieved with consensus reading in a second MRI reporting session.

Validated scoring systems were used for MRI reporting, indicating the presence of lesions of different grades/sizes for a number of hip joint structures: labrum, articular cartilage, bone marrow, tendons, ligaments (table 2).^{31 32} Any other findings, such as trochanteric bursitis or effusion, were specified.

Statistical analysis

Comparisons between the groups of volunteers were made using the unpaired t-test or Mann-Whitney U test (when two groups were compared) and analysis of variance test or Kruskal-Wallis (when more than two subgroups were compared). A χ^2 test was used for gender comparisons between groups. Correlations between baseline demographics (age, gender or body mass index (BMI)) and each type of MRI abnormality were assessed using a χ^2 test, respectively. Possible associations were checked by making calculations of ORs with 95% CIs. Inter-reader agreement was calculated based on kappa statistics: kappa values between 0.610 and 0.800 indicate substantial agreement, while values between 0.810 and 1 indicate

almost perfect agreement.³³ Statistical significance was considered for p values <0.05 (GraphPad Prism, V.6.0c).

Patient and public involvement

This research would not have been possible without the contribution of our study participants, including runners and non-runners who agreed to volunteer as subjects in our study. The participants were not involved in the design or conduct of the study, but they were involved in the dissemination of our study findings across social media and conference presentations. They were informed about the use of their data through consent sheets. Also, a summary report was given to the participants informing them about their results and any health implications.

RESULTS

Participant characteristics

There were no significant differences among inactive non-runners, moderately active runners and highly active runners in terms of baseline demographics: age (p=0.069), gender (p=0.269), BMI (p=0.409).

Mean HOOS scores were ≥90/100 in inactive non-runners (98.8±2), moderately active runners (96.2±5.7) and highly active runners (97.9±3.2).

Also, mean HOOS scores for each individual item were ≥90/100 in inactive non-runners: symptoms (95.6±6.8); pain (100); function in daily living (100); function in

Table 3 Prevalence of MRI findings in the hips of inactive non-runners, moderately active runners and highly active runners

Hip feature	Number (%) of hips with grade ≥ 1 per hip feature			Change among groups (P value)
	Inactive non-runners, n=16 hips	Moderately active runners, n=56 hips	Highly active runners, n=32 hips	
Labrum	1 (6)	12 (21)	5 (16)	0.327
Cartilage	0 (0)	3 (6)	0 (0)	0.270
BME	0 (0)	7 (13)	0 (0)	0.025*
BMC	0 (0)	2 (4)	6 (19)	0.017*
Tendons	0 (0)	9 (16)	9 (28)	0.141
Ligaments	0 (0)	6 (11)	2 (6)	0.519

*significant difference: P value <0.05.

BMC, subchondral cyst; BME, bone marrow oedema.

sport and recreation (98.4 ± 2.9) and knee-related quality of life (97.7 ± 3.2); in moderately active runners: symptoms (92.6 ± 9.9); pain (97.5 ± 4.5); function in daily living (98.7 ± 2.7); function in sport and recreation (96.1 ± 7.3) and knee-related quality of life (94.3 ± 11.5); in highly active runners: symptoms (92.5 ± 11.2); pain (97.3 ± 4.8); function in daily living (99.3 ± 2.3); function in sport and recreation (98.8 ± 2.6) and knee-related quality of life (96.9 ± 7.6).

MRI findings

Our analysis of MRI findings was done per all hips of study participants. The agreement between the scores assigned by the two radiologists for the double-reported scans was very good (kappa 0.850).

Labrum

Labrum abnormalities were found in one (6%) hip of a non-runner, 12 (21%) hips of moderately active runners, 5 (16%) hips of highly active runners (table 3; figure 1). There were no significant differences among groups ($p=0.327$).

The non-runner's labrum signal was found in the anterior side. In the moderately active runners' group, abnormalities of the labrum were found most frequently in the anterosuperior location, followed by superior, anterior and superior locations. In the highly active runners' group, the majority of labral findings were also detected in the anterosuperior and superior subregions, but no MRI signal was detected in other locations.

Articular cartilage

Abnormalities of the acetabular cartilage were identified in three (5%) hips of moderately active runners, while in highly active runners and inactive non-runners no lesions were detected ($p=0.270$).

All were found in the acetabular region; none was detected in the femoral region (see table 3; figure 1).

Bone marrow

Bone marrow oedema was detected in seven (13%) hips of moderately active runners only (see table 3; figure 1). No lesions were detected in highly active runners nor

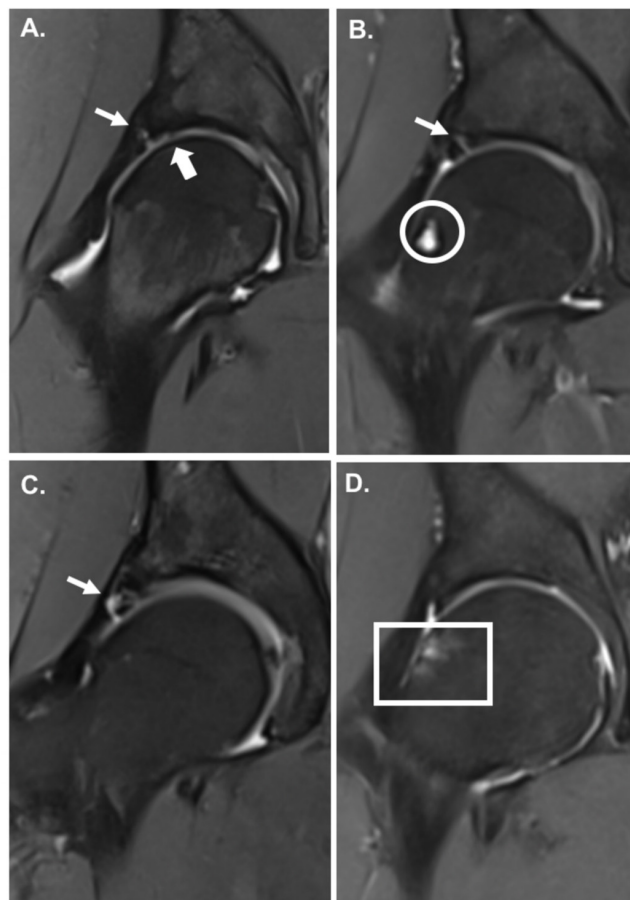


Figure 1 Coronal Dixon MR images showing intra-articular abnormalities in four volunteers, in 'in-phase' MRI sequences: (A) Moderately active runner 1 with labrocartilage separation (small arrow) and full thickness cartilage defect (big arrow); (B) moderately active runner 2 with simple labral tear (small arrow) and subcortical cyst (circle); (C) highly active runner 1 with complex labral tear (small arrow); (D) moderately active runner 3 with subchondral bone marrow oedema (square); SHOMRI grading system was used in the assessment of labrum, cartilage and bone marrow (see table 2); SHOMRI, scoring hip osteoarthritis with MRI.

inactive non-runners, and significant differences among the three groups were identified ($p=0.025$).

Structurally, four were found in the femoral region and three in the acetabular region.

Additionally, both hips of one moderately active runner (4% hips) and six (19%) hips of highly active runners had subchondral cysts, while inactive non-runners had no cysts. Non-runners had a significantly lower prevalence than the other groups ($p=0.017$).

They were all minor MRI abnormalities.

Tendons

Moderately active runners presented with small MRI signal in tendons (tendinosis) in nine (16%) hips (table 3). Highly active runners had tendinosis in nine (28%) hips. No signal was detected in inactive non-runners; however, differences between groups were not significant ($p=0.141$).

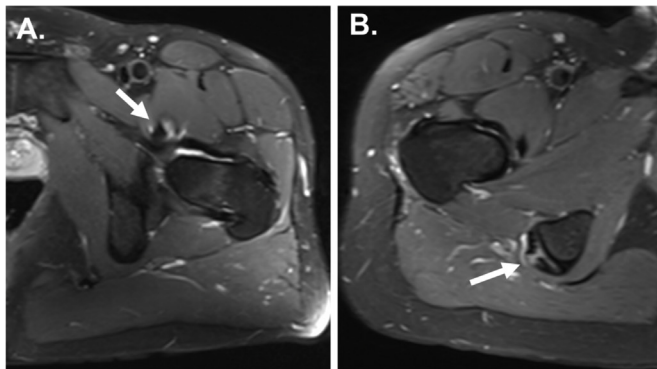


Figure 2 Axial Dixon MR images showing tendinosis, in ‘water phase’ sequences in two volunteers, respectively; (A) moderately active runner 1 with psoas tendinosis (arrow); (B) highly active runner with hamstring tendinosis (arrow). Arrows indicated the specific MRI findings. Grading systems developed by Chi *et al* were used in the assessment of tendons. Tendinosis is low-grade abnormality (see table 2).

Tendinosis was characteristic to the following tendons: gluteus medius, minimus; tensor fascia latae, psoas and hamstring (figure 2).

Ligaments

Abnormal ligament signal on MRI was found in six (11%) hips of moderately active runners and in two (6%) hips of highly active runners (table 3). There was no MRI signal in inactive non-runners’ hips, and differences between groups were not statistically significant ($p=0.519$).

Other findings

Small joint effusion was present in three (9%) hips of highly active runners. Trochanteric bursitis was found in seven (13%) hips of moderately active runners, five (16%) hips of highly active runners and one (6%) hip of an inactive non-runner.

Associations between MRI findings and demographics

There were no statistically significant differences between men and women for any type of lesion.

The BMI of volunteers presenting with MRI abnormalities was not significantly different from those without abnormalities, except for tendinosis ($p=0.053$) in moderately active runners; this was not the case in highly active runners or inactive non-runners. A moderately active runner with BMI ≥ 25 kg/m² (overweight) was 5.7 more likely to present with tendinosis (95% CI, 0.9 to 36.1).

The prevalence of lesions was generally not associated with age. Only in moderately active runners, the mean age for those with tendinosis was slightly higher than those without it (37.7 \pm 12.1 years ($n=7$) vs 30.6 \pm 6.5 ($n=21$)). Moderate dose runners aged ≥ 40 years old were 7.1 times more likely to have tendinosis (95% CI, 0.9 to 57.6; $p=0.046$).

There were no statistically significant associations between the presence of labral tears and other findings or other associations between the presence of different types of MRI abnormalities.

DISCUSSION

Summary of findings

Generally, significant differences were not found among inactive non-runners, moderately active runners and highly active runners for most hip structures. Only bone marrow oedema was significantly more common in moderately active runners than in inactive non-runners and highly active runners ($p=0.025$), while subchondral cysts were significantly more common in runners than non-runners ($p=0.017$)—however, these were minor/small in size and all asymptomatic, non-specific, thus not indicating specific exercise-related strain. No clinical correlations could be made with HOOS self-reported questionnaire scores, which suggested no hip symptoms or functional limitations. No cartilage defects or bone marrow oedema were detected in highly active runners.

Comparison with previous studies

Other studies have already analysed asymptomatic hips of adults to look at incidental findings/potential clinically (in)significant ones at their early stages, using high-resolution MRI equipment, which is highly sensitive in detecting subtle early signs of lesions.^{24–28} However, this has not been done in asymptomatic runners, and it is yet not fully understood whether running is good or bad for the hips.

Literature on MRI-based running research on hip joints is extremely limited. No direct comparisons with other previous studies can be made. So far, only one study assessed the hip joints of runners on MRI⁷; however, it was focused on monitoring the impact of a single marathon run on their hips and knees instead of a comprehensive analysis of the general prevalence of asymptomatic hip MRI findings. Contrary to our findings, no abnormalities were found before or after the marathon; however, limitations of the study include a small sample size ($n=8$), the inclusion of professional and semi-professional runners only (achieving 60–150 km/week) unilateral scans, low-resolution MRI.

Also, there is no clear evidence to suggest that BMI is a key factor associated with running-related injuries. In our study, we found that participants with BMI ≥ 25 kg/m² (overweight) were more likely to have tendinosis on MRI, although they were asymptomatic. Long-term monitoring is required to assess the clinical significance of these findings.

Previous studies have not monitored the asymptomatic hips of participants over a long period of time. Existing long-term studies only assessed recovery levels or long-term consequences of patients with hip pathologies or hip surgeries, respectively.^{34–36}

Clinical significance and future research

First, our study provides a better understanding of the potential impact of varying levels of exercise beyond small amounts on hip joint health. Second, the findings may help in improving management and physicians’ decision-making in patients with symptomatic hips, given the

asymptomatic nature of intra-articular pathologies.^{24 37} Currently, indications for hip arthroscopy include labral tears, articular cartilage and bone marrow lesions, ligamentum teres disorders.^{38–41} However, symptoms of hip pain in an individual cannot immediately be associated with a labral tear or other related findings on MRI. The decision to conduct hip arthroscopy should not be based solely on the presence of a labral pathology on MRI but also on symptoms and further investigations.²⁷

Future studies are needed to clarify how much exercise is optimal in the long-term, whether symptoms develop over time or whether MRI findings progress further in inactive non-runners, moderately active runners and highly active runners.

Strengths and weaknesses

The main study strengths are the large sample size, the use of high-resolution MRI technology (3.0 T MRI and multichannel coil) and optimised MRI protocol (including Dixon sequences⁴²) for good visualisation and comprehensive analysis of all hip joint structures. This is the first study assessing specifically the prevalence of baseline findings in the hip joints of runners using 3.0 T MRI and the first one to compare between the outcomes of inactive non-runners, moderately active runners and highly active runners.

We acknowledge a number of limitations: (1) Radiological assessment may involve a certain degree of bias; however, to reduce this, two senior musculoskeletal radiologists were involved in reporting the scans: one radiologist reported all images, then a subset of images was co-reported by a second radiologist; (2) The male to female ratio between groups is different (including lower number of female participants than male participants in the highly active runners than in non-runners). Moreover, women are known to be more prone to degenerative joint disease. Therefore having equal gender distribution would have improved the analysis; (3) The BMI and age ranges are wide, and the distribution of ages included in a small number of subjects varies between groups. Also, the majority of participants were young, aged <40 years old and only a few older individuals were included in the study. Inactive non-runners were younger than runners; therefore, despite non-runners' low physical activity levels, their young age might have played in their favour when it comes to their hip joint MRI outcomes. Therefore this needs to be considered when interpreting their MRI findings in comparison to slightly older cohorts of runners; (4) The study population is quite heterogeneous for a study with a relatively small number of subjects; (5) The sample size is relatively small (and not equal between groups), and further studies are required to confirm the findings; (6) Other confounding factors may need to be considered, that is, running surface, biomechanics, leg alignment; (7) Follow-up studies are required to assess the clinical relevance of the results over time, including potential progression/regression of current findings along with monitoring changes in symptoms over time.

Acknowledgements We thank all study participants who allowed their clinical details to be used for research and educational purposes.

Contributors LMH, JH, AF, ADL, AHir and AHar developed the study concept and design. LMH, JH, AF, ADL and AHar contributed to the acquisition of data. LMH, JH, AF, ADL, AHir and AHar contributed to the analysis of data. LMH, JH, AF, AHir and AHar contributed to the interpretation of data. LMH conducted the statistical analysis. All authors were involved in writing the manuscript. AHar obtained the funding for the study data and analysis. LMH, JH and ADL provided administrative, technical and material support for the study analysis. AHar is the study supervisor. All authors had full access to the data in the study and can take responsibility for the integrity of the data and the accuracy of the data analysis. All scans were conducted at The London Clinic. AHar is the guarantor. The corresponding author LMH attests that all listed authors meet authorship criteria and that no others meeting the criteria have been omitted.

Funding This research study was funded by patient donations, Trustees of The London Clinic Charity, the Maurice Hatter Foundation, the Rosetrees & Stonegate Trusts, the RNOH Charity and supported by researchers at the National Institute for Health Research University College London Hospitals Biomedical Research Centre.

Competing interests None declared.

Patient and public involvement Patients and/or the public were involved in the design, or conduct, or reporting, or dissemination plans of this research. Refer to the Methods section for further details.

Patient consent for publication Obtained.

Ethics approval The study was approved by University College London Research Ethics Committee (UCL REC Reference Number 13823/001). All participants gave informed consent before taking part.

Provenance and peer review Not commissioned; externally peer reviewed.

Data availability statement Data are available upon reasonable request. Requests for access to data from the study should be addressed to the corresponding author at laura.horga.17@ucl.ac.uk. All proposals requesting data access will need to specify how it is planned to use the data, and all proposals will need approval of the study co-investigator team before data release.

Open access This is an open access article distributed in accordance with the Creative Commons Attribution Non Commercial (CC BY-NC 4.0) license, which permits others to distribute, remix, adapt, build upon this work non-commercially, and license their derivative works on different terms, provided the original work is properly cited, appropriate credit is given, any changes made indicated, and the use is non-commercial. See: <http://creativecommons.org/licenses/by-nc/4.0/>.

ORCID iD

Laura Maria Horga <http://orcid.org/0000-0003-1244-2140>

REFERENCES

- Cejka N, Rüst CA, Lepers R, *et al*. Participation and performance trends in 100-km ultra-marathons worldwide. *J Sports Sci* 2014;32:354–66.
- Vitti A, Nikolaidis PT, Villiger E, *et al*. The “New York City Marathon”: participation and performance trends of 1.2M runners during half-century. *Res Sports Med* 2020;28:121–37.
- Andersen JJ. The state of running 2019. RunRepeat, 2019. Available: www.runrepeat.com/state-of-running [Accessed 8 Feb 2021].
- van Gent RN, Siem D, van Middelkoop M, *et al*. Incidence and determinants of lower extremity running injuries in long distance runners: a systematic review. *Br J Sports Med* 2007;41:469–80.
- Kursunoglu-Brahme S, Schwaighofer B, Gundry C, *et al*. Jogging causes acute changes in the knee joint: an Mr study in normal volunteers. *AJR Am J Roentgenol* 1990;154:1233–5.
- Shellock FG, Deutsch AL, Mink JH, *et al*. Do asymptomatic marathon runners have an increased prevalence of meniscal abnormalities? an Mr study of the knee in 23 volunteers. *AJR Am J Roentgenol* 1991;157:1239–41.
- Hohmann E, Wörtler K, Imhoff AB. Mr imaging of the hip and knee before and after marathon running. *Am J Sports Med* 2004;32:55–9.
- Schueler-Weidekamm C, Schueler G, Uffmann M, *et al*. Does marathon running cause acute lesions of the knee? evaluation with magnetic resonance imaging. *Eur Radiol* 2006;16:2179–85.
- Stahl R, Luke A, Ma CB, *et al*. Prevalence of pathologic findings in asymptomatic knees of marathon runners before and after a competition in comparison with physically active subjects—a 3.0 T magnetic resonance imaging study. *Skeletal Radiol* 2008;37:627–38.

- 10 Luke AC, Stehling C, Stahl R, *et al.* High-field magnetic resonance imaging assessment of articular cartilage before and after marathon running: does long-distance running lead to cartilage damage? *Am J Sports Med* 2010;38:2273–80.
- 11 Horga LM, Henckel J, Fotiadou A, *et al.* Can marathon running improve knee damage of middle-aged adults? A prospective cohort study. *BMJ Open Sport Exerc Med* 2019;5:e000586.
- 12 Horga LM, Henckel J, Fotiadou A, *et al.* Is the immediate effect of marathon running on novice runners' knee joints sustained within 6 months after the run? A follow-up 3.0 T MRI study. *Skeletal Radiol* 2020;49:1221–9.
- 13 Wen DY, Puffer JC, Schmalzried TP. Lower extremity alignment and risk of overuse injuries in runners. *Med Sci Sports Exerc* 1997;29:1291–8.
- 14 Buist I, Bredeweg SW, Bessem B, *et al.* Incidence and risk factors of running-related injuries during preparation for a 4-mile recreational running event. *Br J Sports Med* 2010;44:598–604.
- 15 Hespanhol Junior LC, Pena Costa LO, Lopes AD. Previous injuries and some training characteristics predict running-related injuries in recreational runners: a prospective cohort study. *J Physiother* 2013;59:263–9.
- 16 Domb BG, Brooks AG, Byrd JW. Clinical examination of the hip joint in athletes. *J Sport Rehabil* 2009;18:3–23.
- 17 Kerbel YE, Smith CM, Prodomo JP, *et al.* Epidemiology of hip and groin injuries in collegiate athletes in the United States. *Orthop J Sports Med* 2018;6:1–8.
- 18 Wong S, Steinbach L, Zhao J, *et al.* Comparative study of imaging at 3.0 T versus 1.5 T of the knee. *Skeletal Radiol* 2009;38:761–9.
- 19 Fischbach F, Bruhn H, Unterhauser F, *et al.* Magnetic resonance imaging of hyaline cartilage defects at 1.5T and 3.0T: comparison of medium T2-weighted fast spin echo, T1-weighted two-dimensional and three-dimensional gradient echo pulse sequences. *Acta Radiol* 2005;46:67–73.
- 20 Kijowski R, Blankenbaker DG, Davis KW, *et al.* Comparison of 1.5- and 3.0-T MR imaging for evaluating the articular cartilage of the knee joint. *Radiology* 2009;250:839–48.
- 21 Magee T. Three-tesla MR imaging of the knee. *Magn Reson Imaging Clin N Am* 2007;15:125–32.
- 22 Magee T, Williams D. 3.0-T MRI of meniscal tears. *AJR Am J Roentgenol* 2006;187:371–5.
- 23 Ramnath RR, Magee T, Wasudev N, *et al.* Accuracy of 3-T MRI using fast spin-echo technique to detect meniscal tears of the knee. *AJR Am J Roentgenol* 2006;187:221–5.
- 24 Abe I, Harada Y, Oinuma K, *et al.* Acetabular labrum: abnormal findings at MR imaging in asymptomatic hips. *Radiology* 2000;216:576–81.
- 25 Tresch F, Dietrich TJ, Pfirmann CWA, *et al.* Hip MRI: prevalence of articular cartilage defects and labral tears in asymptomatic volunteers. A comparison with a matched population of patients with femoroacetabular impingement. *J Magn Reson Imaging* 2017;46:440–51.
- 26 Briggs K, Philippon M, Ho C, *et al.* Prevalence of acetabular labral tears in asymptomatic young athletes. *Br J Sports Med* 2017;51:303.1–303.
- 27 AJJ L, Armour P, Thind D. The prevalence of acetabular labral tears and associated pathology in a young asymptomatic population. *Bone Jt J* 2015;97-B:623–7.
- 28 Register B, Pennock AT, Ho CP, *et al.* Prevalence of abnormal hip findings in asymptomatic participants: a prospective, blinded study. *Am J Sports Med* 2012;40:2720–4.
- 29 Nilsson AK, Lohmander LS, Klässbo M, *et al.* Hip disability and osteoarthritis outcome score (HOOS)--validity and responsiveness in total hip replacement. *BMC Musculoskelet Disord* 2003;4:10–17.
- 30 Cuzick J, Warwick J, Pinney E, *et al.* Tamoxifen and breast density in women at increased risk of breast cancer. *J Natl Cancer Inst* 2004;96:621–8.
- 31 Lee S, Nardo L, Kumar D, *et al.* Scoring hip osteoarthritis with MRI (SHOMRI): a whole joint osteoarthritis evaluation system. *J Magn Reson Imaging* 2015;41:1549–57.
- 32 Chi AS, Long SS, Zoga AC, *et al.* Prevalence and pattern of gluteus medius and minimus tendon pathology and muscle atrophy in older individuals using MRI. *Skeletal Radiol* 2015;44:1727–33.
- 33 Viera AJ, Garrett JM. Understanding interobserver agreement: the kappa statistic. *Fam Med* 2005;37:360–3.
- 34 Severt R, Wood R, Cracchiolo A, *et al.* Long-Term follow-up of cemented total hip arthroplasty in rheumatoid arthritis. *Clin Orthop Relat Res* 1991;265:137–45.
- 35 Mei XY, Gong YJ, Safir O, *et al.* Long-Term outcomes of total hip arthroplasty in patients younger than 55 years: a systematic review of the contemporary literature. *Can J Surg* 2019;62:249–58.
- 36 Thomas SRYW. A review of long-term outcomes for late presenting developmental hip dysplasia. *Bone Joint J* 2015;97-B:729–33.
- 37 Schmitz MR, Campbell SE, Fajardo RS, *et al.* Identification of acetabular labral pathological changes in asymptomatic volunteers using optimized, noncontrast 1.5-T magnetic resonance imaging. *Am J Sports Med* 2012;40:1337–41.
- 38 Robertson WJ, Kadrmaz WR, Kelly BT. Arthroscopic management of labral tears in the hip: a systematic review of the literature. *Clin Orthop Relat Res* 2007;455:88–92.
- 39 Guevara CJ, Pietrobon R, Carothers JT, *et al.* Comprehensive morphologic evaluation of the hip in patients with symptomatic labral tear. *Clin Orthop Relat Res* 2006;453:277–85.
- 40 Byrd JWT, Jones KS. Diagnostic accuracy of clinical assessment, magnetic resonance imaging, magnetic resonance arthrography, and intra-articular injection in hip arthroscopy patients. *Am J Sports Med* 2004;32:1668–74.
- 41 Kelly BT, Williams RJ, Philippon MJ. Hip arthroscopy: current indications, treatment options, and management issues. *Am J Sports Med* 2003;31:1020–37.
- 42 Dixon WT. Simple proton spectroscopic imaging. *Radiology* 1984;153:189–94.