

Unusual interventional treatment of a complex calcified coronary artery lesion in a child with Kawasaki disease: a case report

Anthony Mézier *, Claire Dauphin, Géraud Souteyrand, and Pascal Motreff

Department of Cardiology, Gabriel Montpied University Hospital, 63000 Clermont-Ferrand, France

Received 12 November 2021; first decision 10 January 2022; accepted 9 August 2022

For the podcast associated with this article, please visit '<https://academic.oup.com/ehjcr/pages/podcast>'

Background

Kawasaki disease (KD) is a medium vessel vasculitis occurring in children, as yet of undetermined aetiology. KD can lead to severe complications such as coronary artery aneurysms, thrombosis, and sudden death. Monitoring of coronary anomalies is an important issue in the early phase of the disease, and their follow-up is based on different imaging methods. The interventional treatment of these coronary anomalies, which is often complex, is a therapeutic challenge.

Case summary

We are reporting the case of a four-year-old child who presented KD which was complicated by coronary aneurysm of the proximal left anterior descending artery and ectasia of the right coronary artery (RCA). These lesions progressively calcified and resulted at the age of 13 in chronic occlusion of the RCA. After confirmation of myocardial viability and myocardial ischaemia, a complex angioplasty guided by intracoronary imaging was performed using rotational atherectomy, a cutting balloon, and a high pressure balloon. The control coronary angiography performed 1 year later revealed two false aneurysm on the RCA at the angioplasty site, which were successfully treated with a covered stent.

Discussion

This case report describes the challenges of treating coronary artery abnormalities such as calcified coronary lesions in children with KD. The coronary intervention of these lesions remains complex and may lead to coronary rupture. We highlight the advantage of using intracoronary imaging in the management of these calcified lesions for successful revascularization, and to assess the complications of percutaneous coronary intervention.

Keywords

Kawasaki disease • Coronary false aneurysm • Coronary calcification • Chronic total occlusion (CTO) • Optical coherence tomography (OCT) • Case report

ESC Curriculum 3.1 Coronary artery disease • 3.4 Coronary

Learning points

- Coronary artery lesions in Kawasaki disease (KD) may cause significant ischaemic heart disease in children, the assessment of such lesions can be difficult and usually requires close follow-up with imaging and functional studies.
- The percutaneous management of complex and calcified coronary lesions in KD is usually challenging and can be associated with acute and long-term complication such as false coronary aneurysm formation.
- Intravascular imaging can help to diagnose false coronary aneurysm. Covered stents can be deployed to exclude the neck of false coronary aneurysm. It is essential to know the specificities and indications of this stent to be able to manage some complications during PCI.

* Corresponding author. Tel: +33 614877181, Email: amezier@chu-clermontferrand.fr

Handling Editor: Michel Corban

Peer-reviewers: Milenko Zoran Cankovic; Mohammed Al-Hijji; Sab eeda Kadavath

Compliance Editor: Gal Tsaban

Supplementary Material Editor: Anthony Paulo Sunjaya

© The Author(s) 2022. Published by Oxford University Press on behalf of the European Society of Cardiology.

This is an Open Access article distributed under the terms of the Creative Commons Attribution-NonCommercial License (<https://creativecommons.org/licenses/by-nc/4.0/>), which permits non-commercial re-use, distribution, and reproduction in any medium, provided the original work is properly cited. For commercial re-use, please contact journals.permissions@oup.com

Introduction

Kawasaki disease (KD) is an acute febrile vasculitis that affects children and can cause coronary injuries.¹ KD has been known to be the leading cause of acquired heart disease in children in developed countries.² The diagnosis is based on clinical criteria.^{2,3} The vascular inflammation can cause destruction of the arterial architecture, and the formation of coronary aneurysms (CAs) and ectasia. These lesions do not heal *ad integrum*, which can lead to calcified stenoses.^{2,4} In total, 15–25% of children with untreated KD develop CA or ectasias. Treatment with intravenous immunoglobulin (IVIG) in the early phase of the disease (<10 days) reduces the incidence by 80%.⁵

Among complex coronary lesions, calcified lesions following KD represent an ongoing challenge for interventional cardiology. The treatment of this coronary artery calcification by percutaneous coronary intervention (PCI) requires meticulous preparation before stenting, and it may need intravascular imaging and specific interventional techniques.⁶

We report the case of a child with KD who had underwent revascularization by PCI on calcified chronic total occlusion (CTO) of the right coronary artery (RCA) and the management of complications.

Timeline

2007 (Age 4)	Resistant Kawasaki disease (KD), treated with immunoglobulins, diagnosis by transthoracic echocardiography of giant coronary aneurysm of the left anterior descending artery (LAD) and ectasia of right coronary artery (RCA).
2008 (Age 5)	Coronary angiography confirming giant aneurysm of proximal LAD, megadolicho RCA.
2008–2014	Asymptomatic patient, negatives stress testing.
2014 (Age 11)	Coronary computed coronary angiography (CCTA) performed at the age of 11 showed a calcified CA of the proximal LAD (10 mm in diameter, 11 mm long) and the RCA (7 mm in diameter, 25 mm long).
2016 (Age 13)	Positive stress echocardiography, coronary angiography showing a calcified proximal LAD aneurysm with intermediate stenosis. Chronic total occlusion (CTO) of the RCA. Negative-FFR on LAD. Complex angioplasty of CTO of RCA.
2017 (Age 14)	Systematic angiography control at 1 year after PCI showed a stable lesion on LAD and RCA without in-stent restenosis. However two false aneurysms developed at the site of intervention and required a covered stent
2021 (Age 18)	Asymptomatic active patient. Normal Ekg. Normal left ventricular function on echocardiography with negative functional test.

Case summary

In 2007, a four-year-old Caucasian boy with no medical history was hospitalized for fever and asthenia. Clinical examination showed rash, enanther, cervical adenopathy, and elevated inflammatory markers. KD was rapidly diagnosed but he presented a resistant KD requiring

two courses of IVIG (at Day 7 and Day 19 after the onset of symptoms). The echocardiography showed a CA of the proximal left anterior descending artery (LAD) of 8.9 mm, and coronary ectasia of the RCA of 6.8 mm, which was confirmed by coronary angiography. Maximal aneurysm diameter was up to 9.5 mm for LAD and up to 7 mm for RCA. The patient remained asymptomatic. A treatment by aspirin 75 mg and vitamin K antagonist (VKA) (Previscan®, for an international normalized ratio range: 2,0 to 3,0) was initiated.

Coronary computed coronary angiography (CCTA) performed at the age of 11 showed a calcified CA of the proximal LAD (10 mm in diameter, 11 mm long) and the RCA (7 mm in diameter, 25 mm long). The presence of calcification caused difficulties in analysis with CCTA, for this reason the follow-up could not be continued using this method.

At the age of 13, the patient was asymptomatic, with normal left ventricular function, but a stress echocardiography test demonstrated ischaemia in large inferior territory of the left ventricle. We observed the CA of the LAD with intermediate stenosis upstream of the aneurysm and chronic total occlusion (CTO) of the RCA (Figure 1, Supplementary material online, Video S1, S2 and 3). The assessment of the LAD lesion was evaluated by fractional flow reserve (FFR), which was negative (0.86 under hyperaemia). After evaluation and discussion by the heart team regarding the management of RCA CTO with large inferior ischaemia, we performed a monotruncal endoluminal recanalization of the RCA. The lesion was pre-dilated with a 2.5 × 15 mm Euphora semi-compliant balloon (Medtronic, Minneapolis, Minnesota, USA). Owing to under-expansion, a 3 × 15 mm Accuforce non-compliant balloon (Terumo, Tokyo, Japan) was used (Figure 2). The optical coherence tomography (OCT) showed a dissection flap over a long calcified segment and extensive annular calcification. Dissection flap was seen at the junction between the calcification and the healthy arch of the artery (Figure 3). The preparation of the lesion was then optimized by a cutting AngioSculpt 3 × 15 mm balloon (Biotronik, Berlin, Germany) and a 1.5 mm Rotablator (Rotalink® plus, Boston Scientific, Marlborough, MA, USA). Additional pre-dilatation with an Accuforce 3 × 15 mm non-compliant balloon (Terumo, Tokyo, Japan) was performed. Despite this treatment, focal balloon under-expansion remained at the level of the proximal RCA (Figure 2). A drug-eluting stent (DES) XIENCE Alpine 3 × 38 mm (Abbott Cardiovascular, Plymouth, Minnesota, USA) was deployed with persisting focal under-expansion of the stent at the site of occlusion (Figure 2). OCT showed

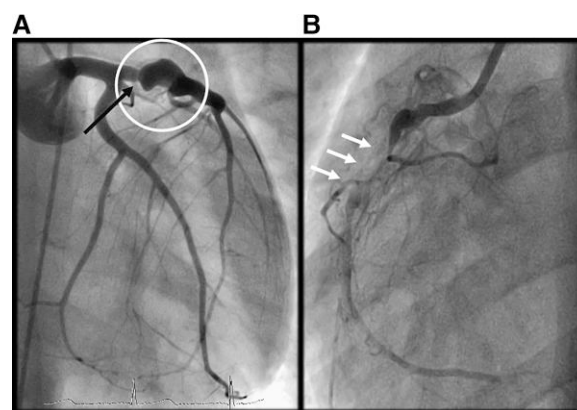


Figure 1 Coronary angiography of a 13-year-old boy with calcified coronary aneurysm of the left anterior descending artery (LAD) (A, circle) associated with an intermediate non-ischaemic lesion upstream of the aneurysm (A, black arrow) and chronic total occlusion (CTO) of right coronary artery (RCA) (B, white arrows).

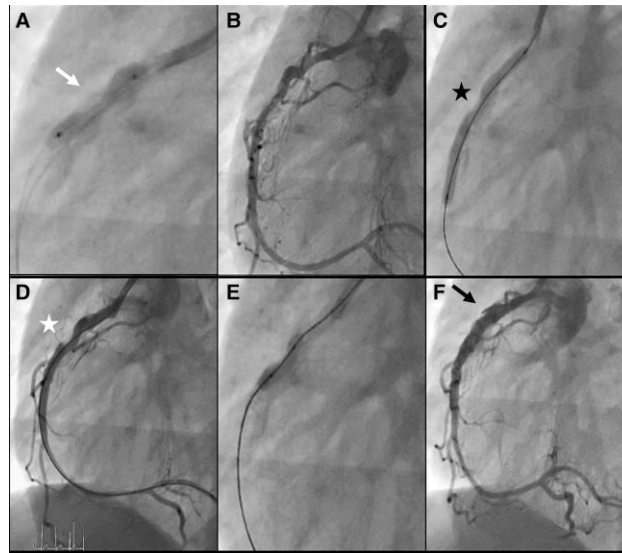


Figure 2 Coronary artery angiography of the RCA. The artery was prepared with a semi-compliant and a non-compliant balloon, non-homogeneous balloon inflation (A). RCA after use of a cutting balloon and rotablator (B), DES implantation with stent under-expansion (C, black star). After stenting, under-expansion of the stent at the level of the calcified resistant lesion (D, white star). Post-dilation with a high pressure OPN balloon (E). After post-dilation, successful stent expansion but there is an additional image at the angioplasty site (F, black arrow).

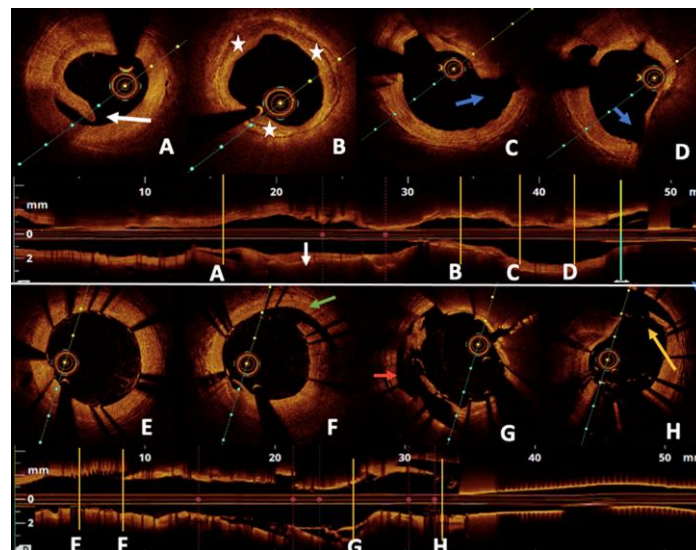


Figure 3 Optical coherence tomography (OCT) of the RCA performed after preparation of the artery by successive pre-dilatations with compliant and non-compliant balloons (A, B, C, and D): long extensive calcified lesion, distal to the pullback, with dissection flap (A, white arrow); median pullback with extensive annular calcifications (B, white star); proximal pullback finds noncircumferential calcifications with dissection flap at the junction between the calcification and the healthy arch (C and D, blue arrow). OCT performed after DES implantation (E, F, G, and H): good stent apposition at the distal pullback (E), dissection flap is visualized (F, green arrow), under-expansion of the stent at the proximal pullback with regard to calcifications (G, red arrow), as well as a sub-adventitial coronary rupture (H, yellow arrow).

dissection flap to part of the distal stent, stent under-expansion, and coronary rupture to proximal stent (appearing sub-adventitial) (Figure 3). Post-dilation with a 3×10 mm non-compliant high pressure balloon inflation of 40 atm (OPN NC, Sis medical AG, Frauenfeld, Switzerland) was useful to treat this resistant lesion. Luminal gain was

observed on the control angiography without extravasation (Figure 2). The patient remained asymptomatic with no EKG-changes and the haemodynamic was stable. Suboptimal outcome of this complex angioplasty was respected. Clopidogrel 75 mg, in addition to aspirin and VKA was added for 6 months.

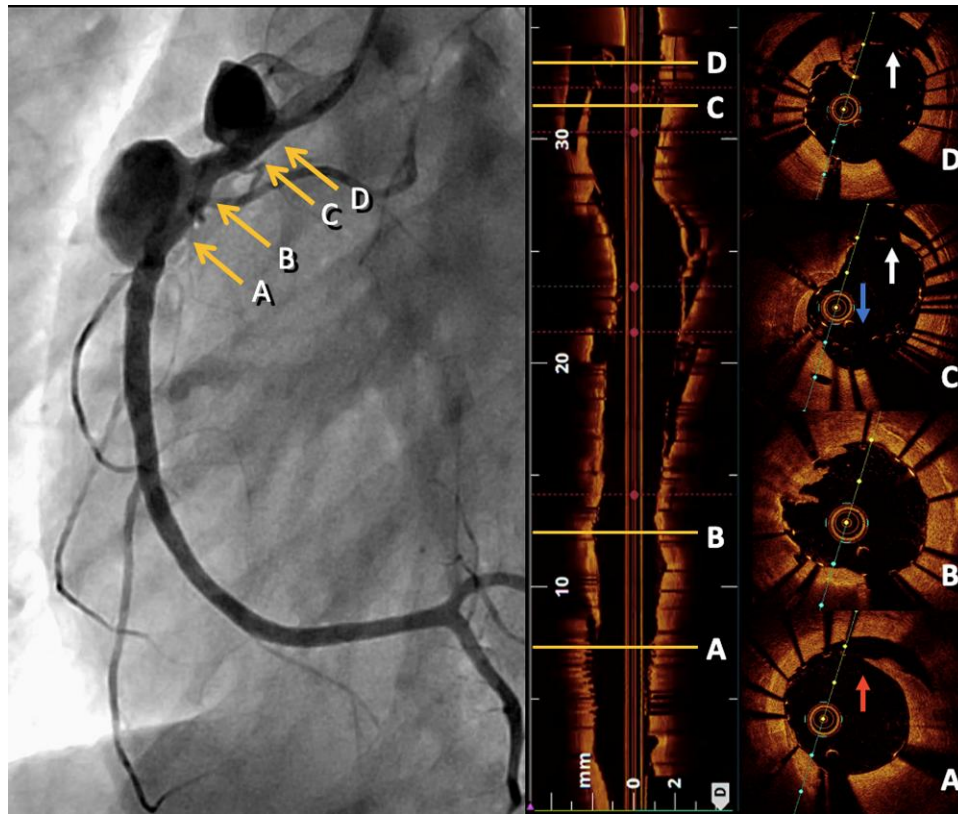


Figure 4 Right coronary angiography and OCT imaging performed on the RCA at 1 year follow-up after angioplasty. Two false aneurysms of the proximal RCA are shown, which developed at the level of the partial coronary ruptures previously described. OCT images: distal pullback visualizing the neck of the distal false aneurysm (A, red arrow), in-stent proliferation (B), proximal pullback reveals the neck of the proximal false aneurysm (C and D, white arrows), as well as proximal stent under-expansion (C, blue arrow).

At the age of 14, the patient remained asymptomatic, stress echocardiography performed 6 months after PCI was negative. Systematic angiography control at 1 year after PCI showed a stable lesion without in-stent restenosis. However, two false aneurysms developed at the site of intervention and required stenting with a 3.5 × 26 mm PAPYRUS PK covered stent (Biotronik AG, Bülach, Switzerland), a procedure guided and optimized by OCT (Figure 4). The covered stent effectively treated these two false aneurysms (Figure 5). Owing to the covered stent implantation, prolonged DAPT (dual antiplatelet therapy) was decided and VKA was discontinued to limit the risk of bleeding.

Systematic angiography control 6 months after the covered stent implantation was performed. The intermediate coronary stenosis of LAD remained similar. The aneurysms of RCA were completely excluded. OCT showed almost complete neointimal overlay of the covered stent (Figure 5) with moderate in-stent proliferation, without thrombosis or restenosis.

The dual antiplatelet therapy is still ongoing after 4 years, and the 18-year-old patient has remained asymptomatic, with no physical limitation, and regular negative stress echocardiography.

Discussion

KD is rare, and the diagnosis is a clinical challenge, given the wide clinical presentations. Delayed diagnosis and treatment can lead to serious coronary arteries complications.^{1,2} More than 80% of small and medium-sized aneurysms regress within 5 years, without healing ad integrum, but giant

aneurysms rarely regress.² Coronary angiography is recommended for giant coronary artery aneurysms within the first year after KD diagnosis, with periodic surveillance every 1–5 years to monitor the evolution of coronary anomalies.² These coronary lesions are fibrotic and calcified. Angioplasty of these lesions is often complex, whatever the technique used, and is exposed to immediate complications (coronary rupture, cardiac tamponade, death) or delayed complications (false aneurysms, restenosis or thrombosis related to under-expansion and/or malapposition).⁷ Detailed evaluation of the severity of calcifications is important to adapt to the right therapeutic strategy before stenting.⁶ These structural characteristic details are revealed and quantified only by using intravascular imaging.⁶ Rotational atherectomy, a cutting balloon, and a very high pressure non-compliant balloon were used to treat chronic calcified occlusion but could not prevent the delayed formation of false aneurysms. At the time, we did not have alternative techniques for the treatment of resistant lesions, such as coronary lithotripsy or orbital atherectomy. OCT imaging allowed the sizing of the tools used and also guided the strategy and helped to decide the best technique according to the morphology and extension of the calcifications.⁸ We preferred to use OCT over IVUS for its better performance in analyzing calcified lesions and stent malapposition.⁹ The decision to treat with coronary artery bypass grafting (CABG) or PCI should be discussed by the heart team.² CABG is the main treatment for complex coronary artery sequelae of KD. Indeed, although CABG does not significantly improve death or acute myocardial infarction rate compared to PCI, more repeated revascularization would be required following PCI.¹⁰

However, taking into account inferior ischaemia due to RCA CTO and absence of ischaemia in the LAD coronary territory assessed by

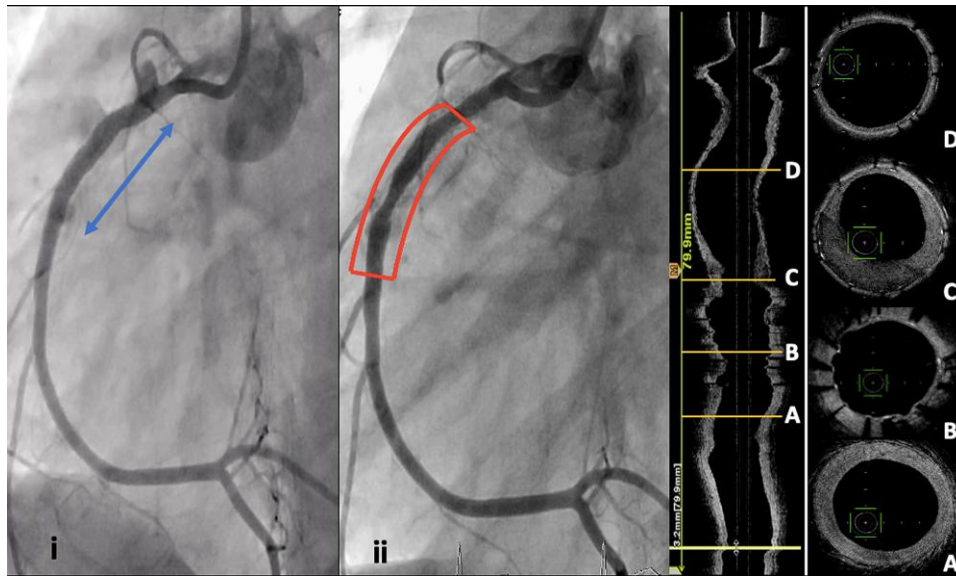


Figure 5 Right coronary angiography after implantation of a covered stent shows exclusion of the two false aneurysms (i, blue arrow). Right coronary angiography performed at the age of 14, 6 months after angioplasty (ii): the two aneurysms were totally excluded with an excellent final result (ii, red rectangle). OCT showed moderate in-stent proliferation (C) without significant stenosis. Almost complete neointimal overlay of the covered stent.

FFR, the heart team decided to opt for PCI as a first step. In case of poor evolution of the calcified LAD stenosis and ischaemia in the anterior territory, this patient could benefit from CABG. Long-term outcomes for patient receiving a covered stent are worse compared with other PCI stented patients (based on in-stent restenosis, target lesion revascularization, stent thrombosis rate),¹¹ and considering his low bleeding risk, we rather continue long-term DAPT.¹²

Conclusion

Our patient presented complex and calcified coronary artery lesions due to KD. After evaluation by the heart team, we performed an endoluminal revascularization on CTO of the RCA, guided by intravascular imaging. A year later, we discovered two false aneurysms at the site of intervention that required covered stenting after intravascular imaging.

Lead author biography



A. Mézier is a cardiologist to the University Hospital Gabriel Montpied in Clermont-Ferrand, France. Actually junior doctor, undergoing training in interventional cardiology.

Supplementary material

Supplementary material is available at *European Heart Journal – Case Reports* online.

Slide sets: A fully edited slide set detailing this case and suitable for local presentation is available online as Supplementary data.

Consent: The authors confirm that written consent for submission and publication of this case report including images and associated text has been obtained from the patient in line with COPE guidelines.

Conflict of interest: None declared.

Funding: None declared.

References

- Bin Jawaid Z, Du JL, Iqbal S, Zhang L. Kawasaki disease: case report of a diagnostic dilemma and often a missed diagnosis. *Eur Heart J Case Rep* 2021;**5**:ytta263.
- McCrindle BW, Rowley AH, Newburger JW, Burns JC, Bolger AF, Gewitz M, et al. Diagnosis, treatment, and long-term management of kawasaki disease: a scientific statement for health professionals from the American heart association. *Circulation* 2017; **135**:e927–e999.
- Agarwal S, Agrawal DK. Kawasaki disease: etiopathogenesis and novel treatment strategies. *Expert Rev Clin Immunol* 2017 Mar;**13**(3):247–258
- Brogan P, Burns JC, Cornish J, Diwakar V, Eleftheriou D, Gordon JB, et al. Lifetime cardiovascular management of patients with previous kawasaki disease. *Heart*. 2020;**106**:411–420.
- Weiss PF. Pediatric vasculitis. *Pediatr Clin North Am* 2012;**59**:407–423.
- Zhu X, Zhou Q, Tong S, Zhou Y. Challenges and strategies in the management of coronary artery aneurysms. *Hellenic J Cardiol*. 2021;**62**:112–120.
- Shi Y, Li L, Liu M, Song C, Wu J, Liu B. Coronary sequelae of kawasaki disease treated with rotational atherectomy and drug coated balloon: a case report. *Medicine (Baltimore)* 2020;**99**:e18371.
- De Maria GL, Scarsini R, Banning AP. Management of calcific coronary artery lesions. *JACC Cardiovasc Interv* 2019;**12**:1465–1478.
- Maehara A, Matsumura M, Ali ZA, Mintz GS, Stone GW. IVUS-Guided Versus OCT-guided coronary stent implantation. *JACC Cardiovasc Imaging* 2017;**10**:1487–1503.
- Muta H, Ishii M. Percutaneous coronary intervention versus coronary artery bypass grafting for stenotic lesions after kawasaki disease. *J Pediatr* 2010;**157**:120–126.
- HarnekJ, James SK, Lagerqvist B. Very long-term outcome of coronary covered stents. a report from the SCAAR registry. *EuroIntervention* 2019;**20**:1660–1667.
- Hernández-Enríquez M, Belle L, Madiot H, Pansieri M, Souteyrand G, Poli F, et al. Use and outcomes of the PK Papyrus covered stent in France: SOS PK Papyrus registry. *Cathet Cardio Intervent* 2021;**98**:874–881.