




10. Knudsen K, Fedorova TD, Hansen AK, et al. In-vivo staging of pathology in REM sleep behaviour disorder: a multimodality imaging case-control study [internet]. *Lancet Neurol* 2018;17(7):618–628.
11. Sulzer D, Cassidy C, Horga G, et al. Neuromelanin detection by magnetic resonance imaging (MRI) and its promise as a biomarker for Parkinson's disease [internet]. *NPJ Park Dis* 2018;4(1):11
12. Sasaki M, Shibata E, Tohyama K, et al. Neuromelanin magnetic resonance imaging of locus ceruleus and substantia nigra in Parkinson's disease. *Neuroreport* 2006;17(11):1215–1218.
13. Schwarz ST, Rittman T, Gontu V, et al. T1-weighted MRI shows stage-dependent substantia nigra signal loss in Parkinson's disease. *Mov Disord* 2011;26(9):1633–1638.
14. Castellanos G, Fernández-Seara MA, Lorenzo-Betancor O, et al. Automated Neuromelanin imaging as a diagnostic biomarker for Parkinson's disease [internet]. *Mov. Disord* 2015;30(7):945–952.
15. Cassidy CM, Zucca FA, Girgis RR, et al. Neuromelanin-sensitive MRI as a noninvasive proxy measure of dopamine function in the human brain [internet]. *Proc Natl Acad Sci USA* 2019;116(11):5108–5117.
16. Biondetti E, Gaurav R, Yahia-Cherif L, et al. Spatiotemporal changes in substantia nigra neuromelanin content in Parkinson's disease. *Brain* 2020;143(9):2757–2770.
17. Ronneberger O, Fischer P, Brox T. U-net: convolutional networks for biomedical image segmentation. *Lect Notes Comput Sci* 2015; 9351:234–241. https://doi.org/10.1007/978-3-319-24574-4_28
18. American Academy of Sleep Medicine. The International Classification of Sleep Disorders (ICSD-3). American Academy of Sleep Medicine; 2014.
19. Hughes AJ, Daniel SE, Kilford L, Lees AJ. Accuracy of clinical diagnosis of idiopathic Parkinson's disease: a clinico-pathological study of 100 cases. *J Neurol Neurosurg Psychiatry* 1992;55(3):181–184.
20. Gaurav R, Yahia-Cherif L, Pyatigorskaya N, et al. Longitudinal changes in Neuromelanin MRI signal in Parkinson's disease. *Mov Disord* 2021;2:9–10.
21. Nichols TE, Holmes AP. Nonparametric permutation tests for functional neuroimaging: a primer with examples. *Hum Brain Mapp* 2002;15(1):1–25.
22. Xing Y, Sapuan A, Dineen RA, Auer DP. Life span pigmentation changes of the substantia nigra detected by neuromelanin-sensitive MRI. *Mov Disord* 2018;33(11):1792–1799.
23. Reimão S, Pita Lobo P, Neutel D, et al. Substantia nigra neuromelanin-MR imaging differentiates essential tremor from Parkinson's disease [internet]. *Mov. Disord* 2015;30(7):953–959.
24. Reimão S, Ferreira S, Nunes RG, et al. Magnetic resonance correlation of iron content with neuromelanin in the substantia nigra of early-stage Parkinson's disease. *Eur J Neurol* 2016;23(2):368–374.
25. Wang J, Huang Z, Li Y, et al. Neuromelanin-sensitive MRI of the substantia nigra: an imaging biomarker to differentiate essential tremor from tremor-dominant Parkinson's disease. *Parkinson's Relat Disord* 2019;58:3–8.
26. Wang J, Li Y, Huang Z, et al. Neuromelanin-sensitive magnetic resonance imaging features of the substantia nigra and locus coeruleus in de novo Parkinson's disease and its phenotypes. *Eur J Neurol* 2018;25(7):949–955.
27. Shinde S, Prasad S, Saboo Y, et al. Predictive markers for Parkinson's disease using deep neural nets on neuromelanin sensitive MRI [internet]. *NeuroImage Clin* 2019;22:101748
28. Le Berre A, Kamagata K, Otsuka Y, et al. Convolutional neural network-based segmentation can help in assessing the substantia nigra in neuromelanin MRI. *Neuroradiology* 2019;61(12):1387–1395.
29. Krupička R, Mareček S, Malá C, et al. Automatic substantia nigra segmentation in neuromelanin-sensitive MRI by deep neural network in patients with prodromal and manifest synucleinopathy. *Physiol Res* 2019;68:S453–S458.
30. Vila M. Neuromelanin, aging, and neuronal vulnerability in Parkinson's disease. *Mov Disord* 2019;34(10):1440–1451.
31. Prasad S, Stezin A, Lenka A, et al. Three-dimensional neuromelanin-sensitive magnetic resonance imaging of the substantia nigra in Parkinson's disease. *Eur J Neurol* 2018;25(4):680–686.
32. Isaias IU, Trujillo P, Summers P, et al. Neuromelanin imaging and dopaminergic loss in parkinson's disease. *Front Aging Neurosci* 2016;8:196
33. Schwarz ST, Xing Y, Tomar P, et al. In vivo assessment of brainstem depigmentation in Parkinson disease: potential as a severity marker for multicenter studies. *Radiology* 2017;283(3):789–798.
34. Kawaguchi H, Shimada H, Kodaka F, et al. Principal component analysis of multimodal neuromelanin MRI and dopamine transporter PET data provides a specific metric for the nigral dopaminergic neuronal density. *PLoS One* 2016;11(3):1–13.
35. Okuzumi A, Hatano T, Kamagata K, et al. Neuromelanin or DaT-SPECT: which is the better marker for discriminating advanced Parkinson's disease? *Eur J Neurol* 2019;26(11):1408–1416.
36. Taniguchi D, Hatano T, Kamagata K, et al. Neuromelanin imaging and midbrain volumetry in progressive supranuclear palsy and Parkinson's disease. *Mov Disord* 2018;33(9):1488–1492.
37. Ohtsuka C, Sasaki M, Konno K, et al. Changes in substantia nigra and locus coeruleus in patients with early-stage Parkinson's disease using neuromelanin-sensitive MR imaging [internet]. *Neurosci. Lett* 2013;541:93–98.
38. Pyatigorskaya N, Magnin B, Mongin M, et al. Comparative study of MRI biomarkers in the substantia nigra to discriminate idiopathic Parkinson disease. *Am J Neuroradiol* 2018;39(8):1460–1467.
39. Oshima S, Fushimi Y, Okada T, et al. Neuromelanin-sensitive magnetic resonance imaging using DANTE pulse. *Mov Disord* 2021; 36(4):874–882.

Supporting Data

Additional Supporting Information may be found in the online version of this article at the publisher's web-site.

Diagnostic and Prognostic Value of External Anal Sphincter EMG Patterns in Multiple System Atrophy

Massimiliano Todisco, MD,^{1,2,3*}  Giuseppe Cosentino, MD, PhD,^{1,3}  Serena Scardina, MD,⁴ Mauro Fresia, BSc,¹ Paolo Prunetti, MD,¹ Antonio Pisani, MD, PhD,^{2,3}  and Enrico Alfonsi, MD¹

This is an open access article under the terms of the Creative Commons Attribution License, which permits use, distribution and reproduction in any medium, provided the original work is properly cited.

*Correspondence to: Dr. Massimiliano Todisco, Translational Neurophysiology Research Unit, IRCCS Mondino Foundation, Via Mondino 2, 27100 Pavia, Italy; E-mail: massimiliano.todisco@mondino.it

Financial disclosures/conflicts of interest: Nothing to report.

Received: 2 November 2021; **Revised:** 6 January 2022; **Accepted:** 9 January 2022

Published online 4 February 2022 in Wiley Online Library (wileyonlinelibrary.com). DOI: 10.1002/mds.28938

¹Translational Neurophysiology Research Unit, IRCCS Mondino Foundation, Pavia, Italy ²Movement Disorders Research Center, IRCCS Mondino Foundation, Pavia, Italy ³Department of Brain and Behavioral Sciences, University of Pavia, Pavia, Italy ⁴Department of Biomedicine, Neuroscience and advanced Diagnostics (BIND), University of Palermo, Palermo, Italy

ABSTRACT: Background: It is debated whether external anal sphincter (EAS) electromyography can distinguish between multiple system atrophy (MSA) and Parkinson's disease (PD), whereas its usefulness for MSA prognosis is unknown.

Objectives: We explored the diagnostic and prognostic value and clinical correlations of EAS electromyography patterns in MSA.

Methods: We collected clinical data and EAS electromyography findings in 72 patients with MSA and 21 with PD.

Results: We identified four EAS patterns. The normal pattern was frequently observed in PD and associated with prolonged survival when identified in MSA. Abnormal patterns were predominant in MSA. The most severe pattern was associated with the highest likelihood of MSA diagnosis and with the worst prognosis in the MSA cohort. MSA patients with EAS abnormalities often showed urogenital symptoms and fecal incontinence.

Conclusions: The increasing severity of EAS electromyography patterns paralleled diagnostic accuracy and survival in MSA, and correlated with prevalence of bladder and bowel symptoms. © 2022 The Authors. *Movement Disorders* published by Wiley Periodicals LLC on behalf of International Parkinson and Movement Disorder Society

Key Words: diagnosis; EMG; multiple system atrophy; Parkinson's disease; prognosis

Multiple system atrophy (MSA) is a sporadic neurodegenerative disorder characterized by autonomic failure and parkinsonian or cerebellar syndrome.¹ Early-onset severe autonomic symptoms diminish the quality of life and are associated with poor prognosis in MSA.²⁻⁸ A prompt diagnosis is therefore crucial to prevent potentially life-threatening complications. However, the clinical presentation of MSA sometimes overlaps with the phenomenology of Parkinson's disease (PD), especially in MSA patients showing levodopa-responsive parkinsonism without overt cerebellar involvement in the early stages.⁹ Evidence that PD patients can also show autonomic symptoms further complicates the diagnostic picture.¹⁰⁻¹²

Several authors suggested that electromyography (EMG) of the external anal sphincter (EAS) may help in

the differential diagnosis, particularly within the first 5 years of symptom onset.¹³⁻²³ Indeed, in contrast with normal findings in PD patients, most subjects with MSA show EAS neurogenic abnormalities that are considered an electrophysiological correlate of Onuf's nucleus degeneration, a pathological hallmark of MSA.²⁴ Despite the suggestion to include EAS EMG in the diagnostic workup of MSA,²⁵ some authors questioned its diagnostic value,²⁶⁻²⁹ and current diagnostic criteria do not acknowledge this investigation as part of the instrumental toolbox.¹

Here, we identified four EAS EMG patterns, aiming to explore their usefulness in the differential diagnosis between MSA and PD, their association with clinical features, and their role as prognostic predictors in MSA.

Patients and Methods

Study Design

In this retrospective study, we consecutively enrolled 72 patients with probable MSA and 21 with PD between 2003 and 2019. The local ethics committee approved the study, and participants gave written informed consent. MSA was diagnosed according to current international criteria,¹ and PD in accordance with the Movement Disorder Society criteria.³⁰ Diagnosis was ascertained at last available follow-up. We applied the following exclusion criteria: history of lumbosacral radiculopathy, lumbar spinal stenosis, pelvic irradiation, lumbar spine or pelvic surgery; diagnosis of diabetes mellitus, polyneuropathy, pudendal nerve injuries, cauda equine or conus medullaris syndrome; presence of severe hemorrhoids or previous hemorrhoidectomy. Diagnosis was unclear at hospital admission, during which patients underwent clinical and instrumental evaluations, including brain magnetic resonance imaging and EAS EMG, routinely performed at our institute to assist the diagnostic process. MSA patients or their caregivers were then contacted by phone, allowing us to ascertain the survival times of 49 MSA patients who died by 2021.

Clinical Assessment

Motor impairment in MSA patients was assessed by means of the Unified Multiple System Atrophy Rating Scale, motor section (UMSARS II). Levodopa equivalent daily dose (LEDD) was calculated. The parkinsonian (MSA-P) and cerebellar (MSA-C) variants of MSA were identified based on the predominant motor phenotype. We also established the symptom type at disease onset and the presence of urogenital symptoms or fecal incontinence at hospital admission. Urogenital symptoms included storage disturbances (ie, urinary urgency or incontinence), voiding disorders (ie, incomplete

bladder emptying or urinary retention), and erectile dysfunction in males. Orthostatic symptoms meant disturbances deriving from orthostatic hypotension, such as dizziness or blurred vision only on standing. Motor disturbances referred to symptoms due to parkinsonian or cerebellar syndrome.

EMG Investigation

Detailed EMG description is reported in Appendix S1. Based on presence and severity of the underlying neurogenic damage, we identified four EAS EMG patterns (Fig. S1):

- I. no pathological spontaneous activity, normal duration and recruitment of motor unit action potentials (MUAPs) (normal findings);
- II. neurogenic MUAPs, normal recruitment of MUAPs, with/without pathological spontaneous activity (mild neurogenic damage);
- III. neurogenic MUAPs, reduced recruitment of MUAPs, with/without pathological spontaneous activity (moderate neurogenic damage);
- IV. absent recruitment of MUAPs, with/without pathological spontaneous activity (severe neurogenic damage).

Statistical Analysis

Patients' groups were compared using the χ^2 test, *t* test, or Wilcoxon rank-sum test. Differences based on EAS EMG patterns in the MSA cohort were explored by means of the χ^2 test or Kruskal-Wallis test. Bonferroni correction for multiple comparisons was applied. Nominal logistic regression analyses were performed to test whether EAS EMG patterns were diagnostic predictors. Receiver operating characteristic curves and odds ratio (OR) values were then calculated. Survival was defined as time from symptom onset to death. Differences in survival based on EAS EMG patterns were explored by means of the Kruskal-Wallis test and post-hoc Dunn's test. Survival analysis was carried out using Kaplan-

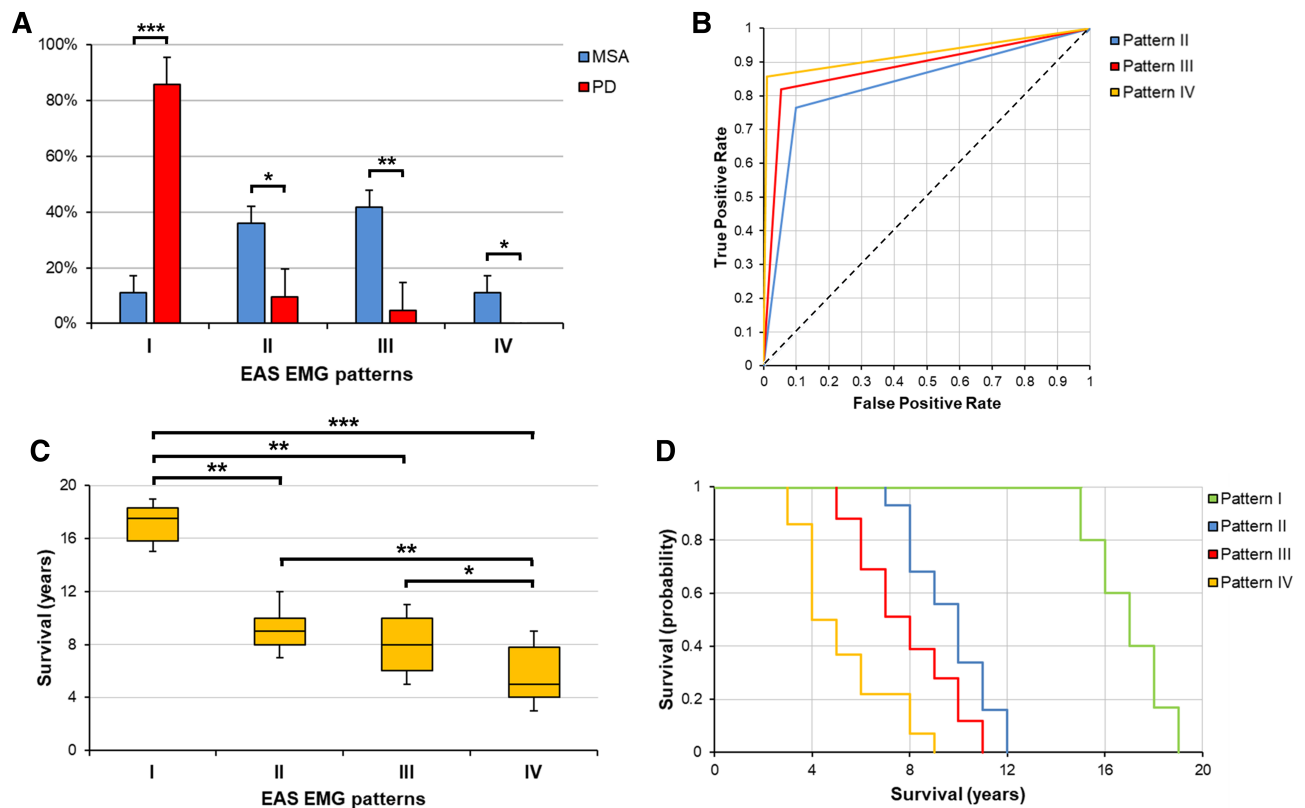


FIG. 1. (A) Frequency distribution of EAS EMG patterns in MSA and PD patients. Vertical error bars represent standard errors. Horizontal bars indicate significant differences detected with the χ^2 test (* $P < 0.05$, ** $P < 0.01$, *** $P < 0.001$). (B) Receiver operating characteristic curves of EAS EMG patterns for differential diagnosis between MSA and PD. MSA diagnosis was used as a positive level for logistic regression analyses. Pattern II showed an area under the curve (AUC) of 0.83, sensitivity of 76.5%, specificity of 90.0%, positive predictive value of 92.9%, and negative predictive value of 69.2%. Pattern III showed an AUC of 0.88, sensitivity of 82.0%, specificity of 94.7%, positive predictive value of 96.8%, and negative predictive value of 74.5%. Pattern IV showed an AUC of 0.96, sensitivity of 85.6%, specificity of 99.0%, positive predictive value of 99.5%, and negative predictive value of 89.7%. (C, D) Survival differences by EAS EMG patterns in MSA patients. (C) Horizontal bars indicate significant differences detected with the post-hoc Dunn's test after the Kruskal-Wallis test (* $P < 0.05$, ** $P < 0.01$, *** $P < 0.001$). (D) Kaplan-Meier curves for each EAS EMG pattern. EAS, external anal sphincter. [Color figure can be viewed at wileyonlinelibrary.com]

Meier curves and log-rank test to compare EAS EMG patterns. Statistical significance was set at $P < 0.05$. JMP Pro 14.0 software was used for statistical analyses.

Results

MSA and PD patients did not differ regarding gender, age at symptom onset, age and disease duration at EMG, or LEDD (Table S1). The distribution of EAS EMG patterns was found to differ between the two cohorts ($P < 0.001$): pattern I was more frequent in subjects with PD as compared with MSA patients (85.7% vs. 11.1%, respectively, $P < 0.001$), whereas each of the abnormal patterns was more frequent in the MSA group (pattern II: 36.1% in MSA vs. 9.5% in PD, $P = 0.011$; pattern III: 41.7% in MSA vs. 4.8% in PD, $P = 0.002$; pattern IV: 11.1% in MSA vs. no PD patient, $P = 0.028$) (Fig. 1A). Differences persisted after excluding MSA-C patients.

The presence of an abnormal pattern correlated with MSA diagnosis ($R^2 = 0.43$, $P < 0.001$), with an area under the curve of 0.87, sensitivity of 88.9%, specificity of 85.7%, positive predictive value of 95.5%, negative predictive value of 69.2%, and OR of 48.0 (95% confidence interval [CI]: 11.5–199.8). The likelihood of MSA diagnosis paralleled the severity of EAS EMG impairment (Fig. 1B). Pattern II was a diagnostic predictor of MSA ($R^2 = 0.32$, $P < 0.001$), with an OR of 29.3 (95% CI: 5.6–54.1). Pattern III correlated with MSA diagnosis ($R^2 = 0.35$, $P < 0.001$) and showed an OR of 67.5 (95% CI: 7.8–104.9). Pattern IV predicted MSA diagnosis ($R^2 = 0.44$, $P < 0.001$), with an OR of 103.7 (95% CI: 23.8–219.7). Demographic and clinical differences based on EAS EMG patterns in the MSA cohort are shown in Figure 2 and Appendix S2.

The following median survival times were recorded in MSA patients: 17.5 years (range: 15–19) in 6 patients with pattern I; 9 years (range: 7–12) in 16 subjects with pattern II; 8 years (range: 5–11) in 19 patients with pattern III; 5 years (range: 3–9) in eight subjects with pattern IV (Fig. 1C). As compared with the group with pattern I, survival was shorter in subjects with patterns II ($P = 0.004$), III ($P = 0.002$), or IV ($P < 0.001$). Patients with pattern IV also had worse prognosis than subjects with patterns II ($P = 0.009$) or III ($P = 0.011$). These findings were confirmed by Kaplan–Meier analyses, which showed poorer prognosis in patients with patterns II (vs. pattern I, $P < 0.001$), III (vs. pattern I, $P < 0.001$), or IV (vs. pattern I, $P < 0.001$; vs. pattern II, $P = 0.001$; vs. pattern III, $P = 0.007$) (Fig. 1D). Differences persisted after adjustment for disease duration at EMG.

Discussion

We identified EAS EMG patterns of increasing severity, assessing the value of the resulting novel classification for differential diagnosis and prognostic stratification of MSA patients. EAS electrophysiological impairment was found to parallel diagnostic accuracy and survival: the more severe the EMG alterations, the greater the likelihood of

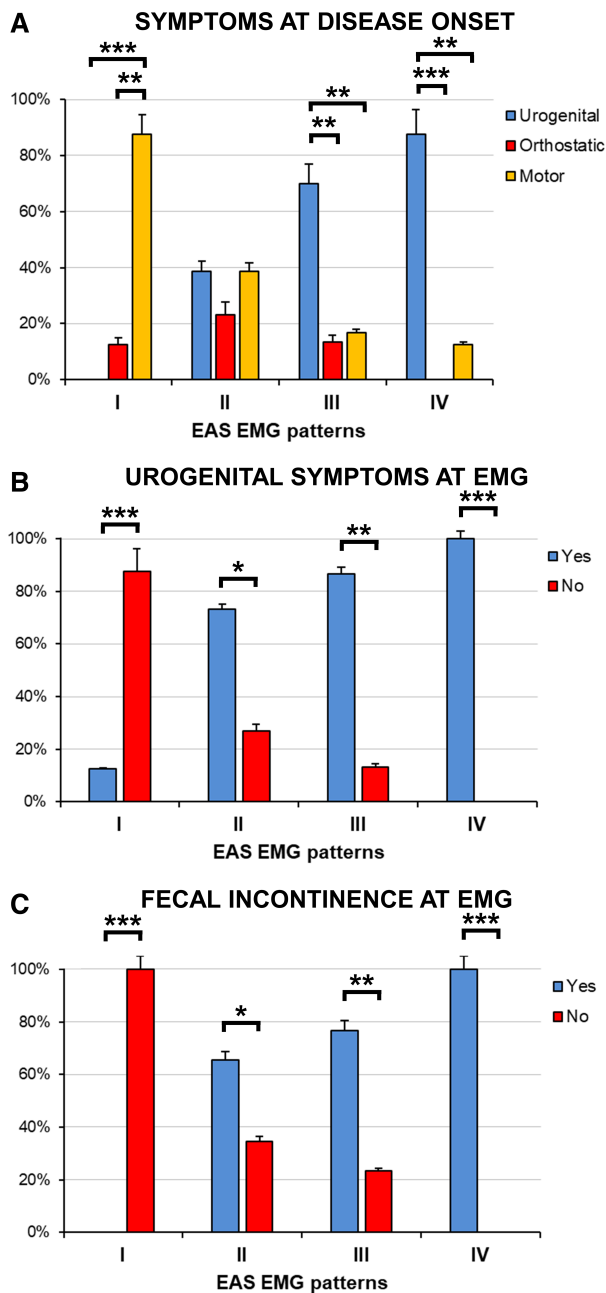


FIG. 2. Frequency distribution of symptom types at disease onset (A) and at hospital admission (B, C) based on EAS EMG patterns in MSA patients. Vertical error bars represent standard errors. Horizontal bars indicate significant within-pattern differences detected with the χ^2 test ($*P < 0.05$, $**P < 0.01$, $***P < 0.001$), whereas between-pattern comparisons are reported in Appendix S2. (A) The predominance of urogenital symptoms at disease onset in subjects with patterns III or IV, versus the group with pattern I, was significant. (B, C) Urogenital symptoms and fecal incontinence at hospital admission were more frequent in patients with patterns II, III, or IV with respect to subjects with pattern I, and in patients with pattern IV as compared with subjects with pattern II. EAS, external anal sphincter. [Color figure can be viewed at wileyonlinelibrary.com]

MSA diagnosis, the worse the patient's prognosis. The pathophysiological relevance of EAS EMG patterns was corroborated by their association with symptom type at disease onset and with prevalence of bladder and bowel symptoms. MSA patients with EAS EMG abnormalities often showed fecal incontinence and urogenital symptoms, which were also frequently present at disease onset in subjects with impaired MUAP recruitment. Indeed, the disease process could begin in the sacral spinal cord before spreading to other regions responsible for motor impairment and cardiovascular autonomic dysfunction.^{31,32} Conversely, MSA patients without EAS EMG alterations did not have fecal incontinence, rarely showed urogenital symptoms, and commonly presented with motor disturbances at disease onset.

Evaluation of MUAP recruitment allowed us to reveal a broader spectrum of EAS EMG abnormalities. Some authors subjectively graded MUAP interference pattern during maximal voluntary contraction, considering its reduction as an alternative expression of Onuf's nucleus degeneration in MSA.^{19,23} Instead, in a small MSA cohort, Gilad and colleagues objectively assessed several recruitment parameters, such as the mean number of MUAPs per insertion site.²⁶ Based on their observation of reduced recruitment pattern in the absence of other features of neurogenic damage, these authors hypothesized upper motor neuron degeneration rather than the loss of lower motor neurons of Onuf's nucleus in MSA patients. The reduced MUAP recruitment found in our study was invariably associated with increased MUAP duration, thus reflecting either a more severe Onuf's nucleus degeneration or a combination of lower motor neuron impairment and neuronal loss in supraspinal areas (eg, the pontine micturition and storage centers) that modulate Onuf's nucleus function.^{33,34}

We found high diagnostic accuracy of EAS EMG patterns in discriminating between MSA and PD, in keeping with studies analyzing single EMG parameters.^{14,18,23} The finding of lower sensitivity than specificity implies that, as seen in 11% of our cohort and in agreement with pathology evidence,³⁵ some MSA patients do not show EAS EMG abnormalities, suggesting Onuf's nucleus preservation.

This study is the first to explore the prognostic value of EAS EMG alterations in MSA. Our results support previous clinical and urodynamic observations, since lower urinary tract symptoms and reduced detrusor contractility were shown to be among the strongest survival predictors in MSA.^{5-8,36} Neurogenic urinary dysfunction was linked to recurrent lower urinary tract infections, a primary cause of death in MSA.³⁷ Moreover, urinary symptoms were associated with the loss of medullary serotonergic neurons, which contribute to micturition modulation and respiratory rhythmogenesis, increasing the risk of sudden death during sleep in MSA patients.^{6,38,39}

Early severe Onuf's nucleus degeneration without significant progression over time could account for lack of

association between EAS EMG patterns and disease duration in the MSA cohort, suggesting the usefulness of EAS EMG regardless of disease stage. However, the diagnostic and prognostic value of this investigation in the early stages should be thoroughly explored in future studies.

The retrospective design and possibility of misdiagnoses given the lack of neuropathological confirmation are limitations of this study. Furthermore, single-MUAP analysis is time-consuming and examiner-dependent, but also the automated techniques require manual revision to ensure accurate calculation of MUAP duration.^{17,40} In conclusion, the patterns described herein may be a valuable diagnostic and prognostic tool, and therefore EAS EMG should be recommended especially when the clinical picture is unclear. A normal EAS EMG pattern could identify a small MSA cohort characterized by less neurodegeneration and prolonged survival. ■

Acknowledgments: We wish to thank Catherine Wrenn for language editing of the manuscript. She had no role in drafting or revising the manuscript for intellectual content. Open Access Funding provided by Università degli Studi di Pavia within the CRUI-CARE Agreement.

Data Availability Statement

Raw data used in this study are available in the Zenodo repository: <https://doi.org/10.5281/zenodo.5775547>

References


1. Gilman S, Wenning GK, Low PA, et al. Second consensus statement on the diagnosis of multiple system atrophy. *Neurology* 2008;71(9):670-676.
2. Watanabe H, Saito Y, Terao S, et al. Progression and prognosis in multiple system atrophy: an analysis of 230 Japanese patients. *Brain* 2002;125(Pt 5):1070-1083.
3. Tada M, Onodera O, Tada M, et al. Early development of autonomic dysfunction may predict poor prognosis in patients with multiple system atrophy. *Arch Neurol* 2007;64(2):256-260.
4. Petrovic IN, Ling H, Asi Y, et al. Multiple system atrophy-parkinsonism with slow progression and prolonged survival: a diagnostic catch. *Mov Disord* 2012;27(9):1186-1190.
5. Wenning GK, Geser F, Krismer F, et al. The natural history of multiple system atrophy: a prospective European cohort study. *Lancet Neurol* 2013;12(3):264-274.
6. Figueroa JJ, Singer W, Parsaik A, et al. Multiple system atrophy: prognostic indicators of survival. *Mov Disord* 2014;29(9):1151-1157.
7. Coon EA, Sletten DM, Suarez MD, et al. Clinical features and autonomic testing predict survival in multiple system atrophy. *Brain* 2015;138(Pt 12):3623-3631.
8. Low PA, Reich SG, Jankovic J, et al. Natural history of multiple system atrophy in the USA: a prospective cohort study. *Lancet Neurol* 2015;14(7):710-719.
9. Hughes AJ, Colosimo C, Kleedorfer B, Daniel SE, Lees AJ. The dopaminergic response in multiple system atrophy. *J Neurol Neurosurg Psychiatry* 1992;55(11):1009-1013.
10. Bonnet AM, Pichon J, Vidailhet M, et al. Urinary disturbances in striatonigral degeneration and Parkinson's disease: clinical and urodynamic aspects. *Mov Disord* 1997;12(4):509-513.
11. Wenning GK, Tison F, Ben Shlomo Y, Daniel SE, Quinn NP. Multiple system atrophy: a review of 203 pathologically proven cases. *Mov Disord* 1997;12(2):133-147.
12. Fanciulli A, Strano S, Ndayisaba JP, et al. Detecting nocturnal hypertension in Parkinson's disease and multiple system atrophy: proposal of a decision-support algorithm. *J Neurol* 2014;261(7):1291-1299.

13. Pramstaller PP, Wenning GK, Smith SJ, Beck RO, Quinn NP, Fowler CJ. Nerve conduction studies, skeletal muscle EMG, and sphincter EMG in multiple system atrophy. *J Neurol Neurosurg Psychiatry* 1995;58(5):618–621.
14. Rodi Z, Denislic M, Vodusek DB. External anal sphincter electromyography in the differential diagnosis of parkinsonism. *J Neurol Neurosurg Psychiatry* 1996;60(4):460–461.
15. Palace J, Chandiramani VA, Fowler CJ. Value of sphincter electromyography in the diagnosis of multiple system atrophy. *Muscle Nerve* 1997;20(11):1396–1403.
16. Stocchi F, Carbone A, Inghilleri M, et al. Urodynamic and neurophysiological evaluation in Parkinson's disease and multiple system atrophy. *J Neurol Neurosurg Psychiatry* 1997;62(5):507–511.
17. Libelius R, Johansson F. Quantitative electromyography of the external anal sphincter in Parkinson's disease and multiple system atrophy. *Muscle Nerve* 2000;23(8):1250–1256.
18. Tison F, Arne P, Sourgen C, Chrysostome V, Yeklef F. The value of external anal sphincter electromyography for the diagnosis of multiple system atrophy. *Mov Disord* 2000;15(6):1148–1157.
19. Lee EA, Kim BJ, Lee WY. Diagnosing multiple system atrophy with greater accuracy: combined analysis of the clonidine-growth hormone test and external anal sphincter electromyography. *Mov Disord* 2002;17(6):1242–1247.
20. Paviour DC, Williams D, Fowler CJ, Quinn NP, Lees AJ. Is sphincter electromyography a helpful investigation in the diagnosis of multiple system atrophy? A retrospective study with pathological diagnosis. *Mov Disord* 2005;20(11):1425–1430.
21. Yamamoto T, Sakakibara R, Uchiyama T, et al. When is Onuf's nucleus involved in multiple system atrophy? A sphincter electromyography study. *J Neurol Neurosurg Psychiatry* 2005;76(12):1645–1648.
22. Sakakibara R, Uchiyama T, Yamanishi T, Kishi M. Sphincter EMG as a diagnostic tool in autonomic disorders. *Clin Auton Res* 2009;19(1):20–31.
23. Qiu F, Wang K, Li T, et al. Differential diagnosis of multiple-system atrophy with Parkinson's disease by external anal- and urethral-sphincter electromyography. *Neuropsychiatr Dis Treat* 2019;15:3061–3067.
24. Mannen T, Iwata M, Toyokura Y, Nagashima K. The Onuf's nucleus and the external anal sphincter muscles in amyotrophic lateral sclerosis and Shy-Drager syndrome. *Acta Neuropathol* 1982;58(4):255–260.
25. Quinn N. Multiple system atrophy. In: Marsden CD, Fahn S, eds. *Movement disorders 3*. London: Butterworth-Heinemann; 1994:262–281.
26. Gilad R, Giladi N, Korczyn AD, Gurevich T, Sadeh M. Quantitative anal sphincter EMG in multisystem atrophy and 100 controls. *J Neurol Neurosurg Psychiatry* 2001;71(5):596–599.
27. Schwarz J, Kornhuber M, Bischoff C, Straube A. Electromyography of the external anal sphincter in patients with Parkinson's disease and multiple system atrophy: frequency of abnormal spontaneous activity and polyphasic motor unit potentials. *Muscle Nerve* 1997;20(9):1167–1172.
28. Linder J, Libelius R, Nordh E, Holmberg B, Stenlund H, Forsgren L. Anal sphincter electromyography in patients with newly diagnosed idiopathic parkinsonism. *Acta Neurol Scand* 2012;126(4):248–255.
29. Giladi N, Simon ES, Korczyn AD, et al. Anal sphincter EMG does not distinguish between multiple system atrophy and Parkinson's disease. *Muscle Nerve* 2000;23(5):731–734.
30. Postuma RB, Berg D, Stern M, et al. MDS clinical diagnostic criteria for Parkinson's disease. *Mov Disord* 2015;30(12):1591–1601.
31. Panicker JN, Simeoni S, Miki Y, et al. Early presentation of urinary retention in multiple system atrophy: can the disease begin in the sacral spinal cord? *J Neurol* 2020;267(3):659–664.
32. Ding X, Zhou L, Jiang X, et al. Propagation of pathological α -synuclein from the urogenital tract to the brain initiates MSA-like syndrome. *iScience* 2020;23(6):101166
33. Blok BF, Holstege G. The central control of micturition and continence: implications for urology. *BJU Int* 1999;83(Suppl 2):1–6.
34. Fowler CJ, Griffiths D, de Groat WC. The neural control of micturition. *Nat Rev Neurosci* 2008;9(6):453–466.
35. Wenning GK, Ben Shlomo Y, Magalhães M, Daniel SE, Quinn NP. Clinical features and natural history of multiple system atrophy. An analysis of 100 cases. *Brain* 1994;117(Pt 4):835–845.
36. Xing T, Ma J, Jia C, Ou T. Neurogenic lower urinary tract dysfunction predicts prognosis in patients with multiple system atrophy. *Clin Auton Res* 2020;30(3):247–254.
37. Papapetropoulos S, Tuchman A, Laufer D, Papatsoris AG, Papapetropoulos N, Mash DC. Causes of death in multiple system atrophy. *J Neurol Neurosurg Psychiatry* 2007;78(3):327–329.
38. Tada M, Kakita A, Toyoshima Y, et al. Depletion of medullary serotonergic neurons in patients with multiple system atrophy who succumbed to sudden death. *Brain* 2009;132(Pt 7):1810–1819.
39. Deguchi K, Ikeda K, Goto R, et al. The close relationship between life-threatening breathing disorders and urine storage dysfunction in multiple system atrophy. *J Neurol* 2010;257(8):1287–1292.
40. Podnar S, Vodusek DB, Stålberg E. Standardization of anal sphincter electromyography: normative data. *Clin Neurophysiol* 2000;111(12):2200–2207.

Supporting Data

Additional Supporting Information may be found in the online version of this article at the publisher's web-site.

Serum Neurofilament Light Chain as a Biomarker of Brain Injury in Wilson's Disease: Clinical and Neuroradiological Correlations

Tjalf Ziemssen, MD, PhD,¹ Katja Akgun, MD, PhD,¹ Anna Członkowska, MD, PhD,² Agnieszka Antos, MD,² Jan Bembenek, MD, PhD,² Iwona Kurkowska-Jastrzębska, MD, PhD,² Adam Przybyłkowski, MD, PhD,³ Marta Skowrońska, MD, PhD,² Lukasz Smolinski, MD, PhD,² and Tomasz Litwin, MD, PhD^{2*} 

*Correspondence to: Dr. T. Litwin, Institute of Psychiatry and Neurology Second Department of Neurology, Sobieskiego 9, 02-957 Warsaw, Poland; E-mail: tomlit@medprakt.pl

Tjalf Ziemssen and Tomasz Litwin contributed equally.

Relevant conflicts of interest/financial disclosures: All financial involvement (eg, employment, consultancies, honoraria, stock ownership or options, grants, patents received or pending, royalties) with any organization or entity with a financial interest in, or financial conflict with, the subject matter or materials discussed in the submitted publication have been completely disclosed.

We have no financial interests relevant to the submitted publication.

Potential conflict of interest: Authors declare no conflict of interest.

Received: 24 October 2021; **Revised:** 11 January 2022; **Accepted:** 14 January 2022

Published online 3 February 2022 in Wiley Online Library (wileyonlinelibrary.com). DOI: 10.1002/mds.28946