

## CASE REPORT

# Case of possible encephalopathy following receiving the first dose of Iranian COVID-19 Vaccine; COVIran Barakat

Mohammad Javad Fallahi<sup>1</sup> | Navid Esmailzadeh Shahri<sup>2</sup>  | Zohre Khodamoradi<sup>1</sup> | Moazameh Meymandi Nia<sup>1</sup> | Faezeh Sehatpour<sup>1</sup> | Laleh Mahmoudi<sup>2</sup>

<sup>1</sup>Department of internal medicine, Shiraz University of Medical Sciences, Shiraz, Iran

<sup>2</sup>Department of Clinical Pharmacy, School of Pharmacy, Shiraz University of Medical Sciences, Shiraz, Iran

## Correspondence

Laleh Mahmoudi, Department of Clinical Pharmacy, School of Pharmacy, Shiraz University of Medical Sciences, 5 km of Shiraz-Isfahan highway, Shiraz, Iran.  
Email: mahmoudi\_l@sums.ac.ir

## Funding information

This research had no any funding sources.

## Abstract

We report a case of possible encephalopathy after receiving the first dose of Iran's COVIran Barekat vaccine. The patient had no history of neurological or mental illness. Clinical examinations and radiology reports were performed and differential diagnoses were analyzed by the treatment team. Finally, the possible association between vaccination and encephalopathy was concluded.

## KEYWORDS

COVID-19, COVIran Barekat, encephalopathy, vaccine

## 1 | INTRODUCTION

The global SARS-CoV-2 pandemic has led to a respiratory infection that presents with a variety of clinical symptoms.<sup>1</sup> Although the pulmonary manifestations of COVID-19 have been described in most articles, the neurological consequences of the virus have been less studied.<sup>2</sup> The lack of definitive treatment for this disease has led to an unprecedented worldwide effort to develop an effective vaccine against the virus.<sup>3</sup> One of these vaccines produced in Iran is the complete vaccine of inactivated SARS-CoV-2 virus called COVIran Barekat,<sup>4</sup> which is still in the third stage of clinical trials, but due to the fact that in initial clinical reports, this vaccine has shown sufficient safety and efficacy, an emergency use permit was issued in Iran in June 2021.<sup>5</sup>

COVIran Barekat is an inactivated virus-based vaccine. Also, in the formulation of this vaccine, adjuvants have been used with the aim of increasing and/or modulating the inherent immunogenicity of the antigen in order to create strong and long-lasting immune responses. This factor significantly reduces the amount of antigen and/or the total number of booster injections needed to achieve the required immune responses.<sup>4</sup>

Like any vaccine, COVID-19 vaccines of any kind can cause side effects, most of which are mild to moderate and go away on their own within a few days. The neurological side effects are usually mild, self-limiting, and controllable. However, in some cases, these complications may become so severe that the person may need to be hospitalized or even admitted to the intensive care unit (ICU). These complications can rarely lead to death.

This is an open access article under the terms of the Creative Commons Attribution-NonCommercial-NoDerivs License, which permits use and distribution in any medium, provided the original work is properly cited, the use is non-commercial and no modifications or adaptations are made.

© 2022 The Authors. *Clinical Case Reports* published by John Wiley & Sons Ltd.

Despite the possible association of vaccine injection with neurological complications, it is vital to consider more important causes of encephalitis including CNS infections, septic encephalopathy, metabolic encephalopathy, drug toxicity, cerebrovascular disease, neoplastic disorders, epileptic disorders, and rheumatic disorders.<sup>6</sup>

The exact mechanism of encephalopathy following COVID-19 vaccines is not known, but vaccines can cause autoimmunity in humans through a specific mechanism of molecular mimicry, which can be enhanced by an immunological adjuvant, or a non-specific activating mechanism.<sup>7–9</sup> In general, vaccination can induce pro-inflammatory cytokines and T-cell responses.<sup>10</sup> Peripheral pro-inflammatory cytokines that are expressed after vaccination can lead to neuroinflammation and encephalitis when they reach the brain.<sup>11</sup>

Here, we present a patient with autoimmune encephalitis whose symptoms started one day after receiving the first dose of COVIran Barekat vaccine.

## 2 | CASE PRESENTATION

A 37-year-old man with no previous history of illness or medication was taken to the hospital emergency room due to decreased level of consciousness. The patient developed hallucinations, photophobia, and aphasia one day after the first dose of the COVIran barekat vaccine, followed by loss of consciousness, fever, and abnormal movements of the upper and lower limbs. He has no recent travel history, alcohol or drug use, or high-risk sexual behaviors.

In the initial assessment, body temperature was 38.9 frontally, blood pressure (BP) was 110/90 mmHg, respiratory rate (RR) was 22 breaths/min, and heart rate (HR) was 98 beats/min. Oxygen saturation in room air was 95%. A random blood glucose of 190 mg/dL was recorded by a glucometer. Both pupils were medium in size and responded to light. Neck stiffness was determined on head and neck examination. Pulmonary auscultation was significant for fine basilar crackles of the left lower lung. On neurological examination, the patient had no response, episodic jerky movement of the whole body without focal neurological deficit. Fundoscopy was normal.

CT scan of the brain without contrast was normal, and HRCT of the lung showed infiltration of the left lower lobe (Figures 1 and 2).

Due to decreased level of consciousness and meningismus, lumbar puncture was performed for the patient. The opening pressure was 14cmH<sub>2</sub>O. CSF analysis showed the number of white blood cell (WBC) 38 (segment count:3 and lymphocyte count:35), number of red blood (RBC) 0, protein level 39 mg/dl. Because of the possibility of developing herpes encephalitis, an intravenous acyclovir was started empirically for him, and the patient was transferred to the ICU. Laboratory results are summarized in Table 1.

Blood, CSF, and urine culture results were negative after 96 h. The results of HSV PCR of CSF and COVID-19 PCR results were also negative. Laboratory findings showed a gradual increase in muscle enzymes, so aggressive hydration and urinary alkalization were initiated to prevent renal failure. An electroencephalogram (EEG) recorded the brain's normal electrical activity without evidence of epilepsy. Brain MRI was also completely normal (Figure 3). In the ICU, a low dose of midazolam (2.5 to 5 mg/h) was started to stop his jerky movements. Due to normal brain MRI and negative herpes simplex PCR in CSF, acyclovir was discontinued.

With supportive care in the ICU, the patient's condition and level of consciousness improved significantly after 3 days. He eventually left the hospital in normal condition and in full recovery.

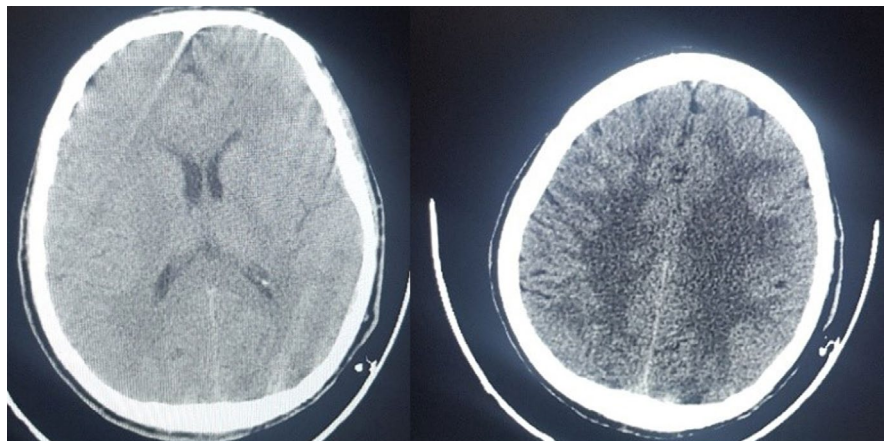
## 3 | DISCUSSION

Acute encephalopathy has a wide range of possible causes, the most common of which are infectious.<sup>6</sup> To date, there have been no reports of encephalitis and seizures with the Iran's COVID-19 vaccine, but in a few cases, encephalopathy has been reported after injecting other types of COVID-19 vaccine. One of these cases has been reported in the article by Liu et al., in which two cases of encephalopathy were reported following the injection of the Moderna COVID-19 vaccine. Both patients were elderly and had no known neurological or psychological history, and their symptoms began approximately one week after the first dose of the Moderna COVID-19 vaccine.<sup>12</sup> But our

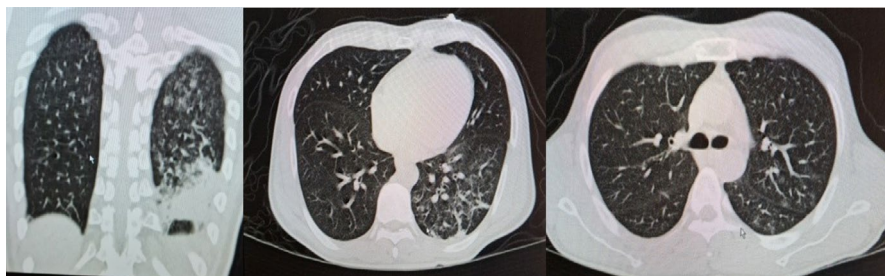

FIGURE 1 Lung HRCT: left lower lobe infiltration in favor of aspiration pneumonia

**FIGURE 2** Normal non-contrast brain CT scan



**TABLE 1** Laboratory data

|                             | 1 <sup>st</sup> day | 3 <sup>rd</sup> day | 6 <sup>th</sup> day | 9 <sup>th</sup> day | 12 <sup>th</sup> day | 15 <sup>th</sup> day |
|-----------------------------|---------------------|---------------------|---------------------|---------------------|----------------------|----------------------|
| WBC(x1000/mm <sup>2</sup> ) | 14.8                | 18.4                | 11.7                | 8.2                 | 7.2                  | 7.2                  |
| HB(g/dL)                    | 13.5                | 12.7                | 12                  | 12                  | 12.9                 | 12.2                 |
| PLT(x1000/mm <sup>2</sup> ) | 203                 | 144                 | 118                 | 172                 | 238                  | 231                  |
| BUN (mg/dL)                 | 38                  | 12                  | 9                   | 16                  | 7                    | 10                   |
| CR (mg/dL)                  | 1.51                | 2.3                 | 1.11                | 1                   | 1.24                 | 1.3                  |
| Na(meq/L)                   | 152                 | 149                 | 148                 | 137                 | 138                  | 143                  |
| K(meq/L)                    | 3.3                 | 4                   | 4                   | 3.9                 | 3.8                  | 3.6                  |
| CPK(U/L)                    | 3770                | 12000               | 2070                | 2690                | 1650                 | 363                  |
| LDH(U/L)                    | 767                 | –                   | –                   | –                   | –                    | –                    |
| Phosphor(mg/dL)             | 3.6                 | –                   | –                   | –                   | –                    | –                    |
| Ca(mg/dL)                   | 10                  | –                   | –                   | –                   | –                    | –                    |
| AST(U/L)                    | 137                 | 210                 | –                   | –                   | –                    | –                    |
| ALT(U/L)                    | 40                  | 66                  | –                   | –                   | –                    | –                    |
| ESR (mm/hr)                 | –                   | –                   | –                   | 35                  | –                    | 30                   |
| CRP (mg/L)                  | 58                  | –                   | –                   | –                   | –                    | –                    |

Abbreviations: ALT, alanine aminotransferase; AST, aspartate aminotransferase; BUN, blood urea nitrogen; CPK, Creatine phosphokinase; LDH, lactate dehydrogenase Ca, calcium; CR, ceratinin; CRP, C-reactive protein; ESR, erythrocyte sedimentation rate; HB, hemoglobin; K, potassium; Na, sodium; PLT, platelete; WBC, white blood cell.

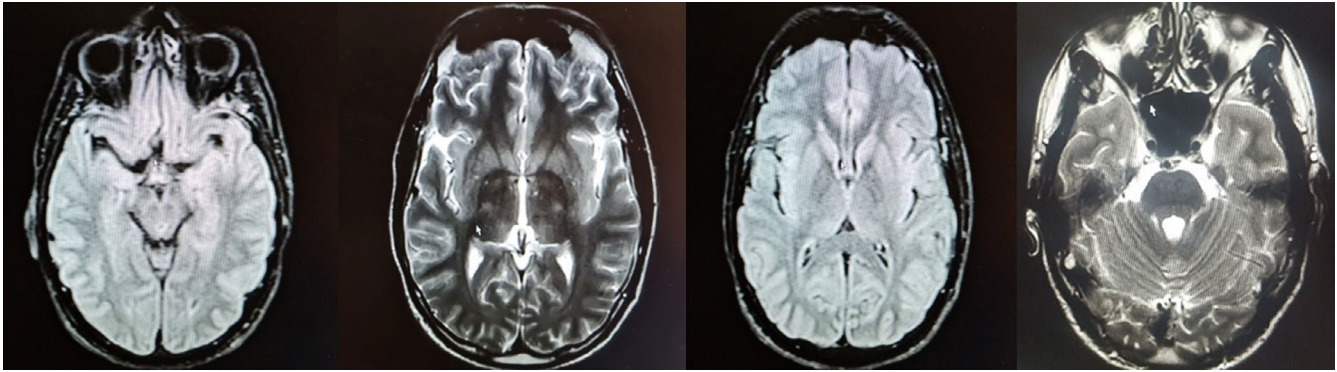
patient was younger and the onset of symptoms occurred the day after the injection of vaccine, which may be due to differences in the technology of production of these vaccines. Inactivated virus is used in CovIran Barakat vaccine, while Moderna vaccine is based on virus mRNA.

Genetics is also a very influential factor in the immunogenicity and immunological responses of different people to vaccines, which can play an important role in creating this difference.

In another article by Frederick et al., three cases of encephalitis were reported after the ChAdOx1 nCov-19 vaccine. In this study, symptoms started 7–11 days after the first dose of the vaccine. In this study, the prevalence of encephalitis after injection of the ChAdOx1 nCov-19 vaccine was 8 cases per 10 million, so COVID vaccine-induced

encephalitis could be a rare side effect. But in case of this complication, it should be diagnosed in time and treated in a timely and appropriate manner.<sup>13</sup> Depending on the severity of the symptoms, encephalitis caused by the COVID vaccine can be controlled, as in our patient, by symptomatic treatment with benzodiazepines, although in more severe cases, the use of an immunosuppressive agent may be required.<sup>12,13</sup>

Encephalopathy refers to dysfunction of the level or contents of consciousness due to brain dysfunction and can be caused by general brain injuries such as traumas, infections, drugs, etc. or focal lesions such as brain tumors. Underlying causes of encephalopathy include primary and systemic neurological conditions, each of which requires its own diagnostic pathway and



**FIGURE 3** Multiplanar, multi-sequential contrast MRI study the brain with contrast. No evidence of acute infarction or hemorrhage. No focal meningeal enhancement. No space-occupying lesion

includes a wide range of radiological and serological/immunological studies. Magnetic resonance imaging is the gold standard technique for imaging the brain in encephalitis. The key point is that in case of seizure or loss of consciousness in a patient with a recent injection of the COVID-19 vaccine, the more important causes of these symptoms should be considered and investigated. Vaccine-related encephalopathy is, therefore, a diagnosis of exclusion.

In our patient, blood glucose levels were assessed, CSF analysis and PCR were performed to rule out bacterial and viral meningoencephalitis, MRI and CT scan of the brain were done to assess central nervous system infection and sepsis-related encephalopathy, and electroencephalogram was performed to detect epileptic disorders. All tests related to metabolic or rheumatic disorders in the patient were also evaluated.

Since no organic, bacterial, or metabolic cause was found for the patient's symptoms, the possibility of autoimmune encephalitis due to the vaccine was raised.

In general, vaccine injection can induce pro-inflammatory cytokines and T-cell responses. Peripheral pro-inflammatory cytokines that develop after vaccination can cross the blood–brain barrier and enter to the brain, and the brain recognizes these cytokines TNF, such as alpha and interleukin-6, as molecular signals of sickness and it can cause nerve inflammation.<sup>11</sup> This factor can be considered as a justification for encephalopathy due to COVID-19 vaccine injection. However, the link between encephalopathy and COVID-19 vaccine cannot be confirmed with certainty.

Different conditions such as COVID-19 infection iatrogenic and autoimmune conditions can trigger cytokine storm neurotoxicity related to immune effector cell-associated neurotoxicity syndrome.<sup>14</sup>

Cytokine storm-associated encephalopathy is a recently definition which means the massive release of cytokines promoting blood–brain barrier disruption and

microglia/astrocyte activation which support neuroinflammation in a synergistic act.<sup>15</sup> This mechanism could be considered for acute reversible encephalopathy associated with the COVID-19 vaccine. This cytokine storm triggers an innate immune response either to the DNA encoding SARS-CoV-2 or to a viral vector or adjuvants, in a patient with previous exposure to SARS-CoV-2, which is prone to autoimmunity that can cause an unbridled immune response.

Although this report suggests a possible association between the COVIran Barekat vaccine and the incidence of encephalopathy, further data collection based on epidemiological studies is needed to confirm this theory. In conclusion, we documented the first hyperacute reversible encephalopathy following COVIran Barekat COVID-19 vaccination, suggesting cytokine storm as its causative mechanism, and highlighting the need to deepen our knowledge on this immune-mediated phenomenon. Finally, we hope that these data will increase physicians' awareness in identifying and diagnosing this complication early in order to perform timely treatment measures.

#### ACKNOWLEDGMENTS

The authors are grateful of Namazi hospital, Internal care unit, Shiraz- Iran, for supporting this study. Also, the authors thank Dr. Nasim Khosroabadi for commenting on the initial manuscript.

#### CONFLICT OF INTEREST

There is no conflict of interest.

#### AUTHOR CONTRIBUTIONS

Duties: A. patient management and Clinical Examination B. Data gathering C. Manuscript drafting D. Critique review of manuscript E. project management Mohammad Javad Fallahi: A, C, D. Navid Esmailzadeh Shahri: B, C. Zohre Khodamoradi: A, B. Moazameh Meymandi Nia: A, B. Faezeh Sehatpour: A, B. laleh Mahmoudi: C, D, E.

## ETHICAL APPROVAL

This study was supervised by Ethical committee of researches of Shiraz university of medical sciences, Shiraz- Iran.

## CONSENT

Written informed consent was obtained from the patient for publication of this case report.

## DATA AVAILABILITY STATEMENT

Data sharing not applicable—no new data generated, or the article describes entirely theoretical research.

## ORCID

Navid Esmaeilzadeh Shahri  <https://orcid.org/0000-0002-0388-8856>

## REFERENCES

- Huang C, Wang Y, Li X, et al. Clinical features of patients infected with 2019 novel coronavirus in Wuhan, China. *Lancet*. 2020;395(10223):497-506. doi:10.1016/S0140-6736(20)30183-5
- Wang HY, Li XL, Yan ZR, Sun XP, Han J, Zhang BW. Potential neurological symptoms of COVID-19. *Ther Adv Neurol Disord*. 2020;13:175628642091783. doi:10.1177/1756286420917830
- Andreadakis Z, Kumar A, Román RG, Tollefsen S, Saville M, Mayhew S. The COVID-19 vaccine development landscape. *Nat Rev Drug Discovery*. 2020;19(5):305-306.
- Abdoli A, Aalizadeh R, Aminianfar H, et al. Safety and potency of BIV1-CovIran inactivated vaccine candidate for SARS-CoV-2: A preclinical study. *Reviews in Medical Virology*. 2021. doi:10.1002/rmv.2305
- Venkadapathi J, Govindarajan VK, Sekaran S, Venkatapathy S. A minireview of the promising drugs and vaccines in pipeline for the treatment of COVID-19 and current update on clinical trials. *Front Mol Biosci*. 2021;8:637378.
- Graus F, Titulaer MJ, Balu R, et al. A clinical approach to diagnosis of autoimmune encephalitis. *Lancet Neurol*. 2016;15(4):391-404.
- Salemi S, D'Amelio R. Could autoimmunity be induced by vaccination? *Int Rev Immunol*. 2010;29(3):247-269.
- Ruiz JT, Luján L, Blank M, Shoenfeld Y. Adjuvants-and vaccines-induced autoimmunity: animal models. *Immunol Res*. 2017;65(1):55-65.
- Vegezzi E, Ravaglia S, Buongarzone G, et al. Acute myelitis and ChAdOx1 nCoV-19 vaccine: casual or causal association? *J Neuroimmunol*. 2021;359:577686.
- Pulendran B, Ahmed R. Immunological mechanisms of vaccination. *Nat Immunol*. 2011;12(6):509-517. doi:10.1038/ni.2039
- Giannotta G, Giannotta N. Vaccines and neuroinflammation. *Int J Pub Health Safe*. 2018;3(163):2.
- Liu BD, Ugolini C, Jha P. Two cases of post-moderna COVID-19 vaccine encephalopathy associated with nonconvulsive status epilepticus. *Cureus*. 2021;13(7):e16172.
- Zuhorn F, Graf T, Klingebiel R, Schäbitz WR, Rogalewski A. Postvaccinal encephalitis after ChAdOx1 nCoV-19. *Ann Neurol*. 2021;90(3):506-511.
- Cani I, Barone V, D'Angelo R, et al. Frontal encephalopathy related to hyperinflammation in COVID-19. *J Neurol*. 2021;268(1):16-19.
- Pensato U, Muccioli L, Cani I, et al. Brain dysfunction in COVID-19 and CAR-T therapy: cytokine storm-associated encephalopathy. *Ann Clin Transl Neurol*. 2021;8(4):968-979.

**How to cite this article:** Fallahi MJ, Esmaeilzadeh Shahri N, Khodamoradi Z, Meymandi Nia M, Sehatpour F, Mahmoudi L. Case of possible encephalopathy following receiving the first dose of Iranian COVID-19Vaccine; COVIran Barakat. *Clin Case Rep*. 2022;10:e05661. doi:[10.1002/ccr3.5661](https://doi.org/10.1002/ccr3.5661)