


## ORIGINAL RESEARCH

# Management of the facial nerve following temporal bone ballistic injury

Anne K. Maxwell MD  | John C. Lemoine MD | Jacob B. Kahane MD |  
Celeste C. Gary MD

Department of Otolaryngology-Head and Neck Surgery, LSU Health Sciences Center-New Orleans, New Orleans, Louisiana, USA

**Correspondence**

Anne K. Maxwell, Department of Otolaryngology-Head and Neck Surgery, Division of Neurotology, LSU Health Sciences Center-New Orleans, 533 Bolivar St, Suite 566, New Orleans, LA 70112, USA.  
Email: [amaxw3@lsuhsc.edu](mailto:amaxw3@lsuhsc.edu)

**Abstract**

**Objective:** To understand the patterns of temporal bone fracture and facial nerve injury from ballistic trauma.

**Study Design:** Retrospective case series.

**Methods:** Retrospective review of 42 patients evaluated following temporal bone ballistic injury at a single institution, university-based level-one trauma center between 2012 and 2021. Demographics, facial nerve status, CT images, interventions, complications, and outcomes were reviewed.

**Results:** Mean age 30.3 years (range 5–58 years); 79% male. Racial demographics reflected the surrounding community. Seven mortalities occurred. Nineteen patients (54%) demonstrated facial nerve injury. Of those, 13/19 displayed immediate paralysis, 1 delayed, 5 unknown (due to altered mental status). On consultation, House-Brackmann grade 6 paralysis was common (13/19). Fracture was otic capsule-sparing in 17/19 (90%), universally comminuted, with significant disruption along the mastoid tip (16/19), external auditory canal (EAC) (15/19), and periauricular soft tissues (13/19). Nine patients underwent surgical intervention: Transmastoid facial nerve decompression to remove compressive bony spicules ( $n = 5$ ); eye protection surgery ( $n = 3$ ); and peripheral facial nerve exploration ( $n = 1$ ), noting transection at the pes. One required middle cranial fossa and transmastoid repair of cerebrospinal fistulae in setting of severe meningitis. House-Brackmann scores improved in 80% following transmastoid nerve decompression despite CT evidence of likely additional injury in its extratemporal course.

**Conclusions:** Common patterns of temporal bone fracture seen in blunt trauma (longitudinal/transverse, otic capsule-sparing/disrupting) were not found in patients with ballistic facial nerve injury. Rather, injury was commonly apparent in the EAC, mastoid tip, and periauricular soft tissues. Clinicians should have high suspicion for extratemporal facial nerve injury following ballistic trauma.

This manuscript was presented at the Triological Society Meeting at the Combined Otolaryngology Sections Meeting in Dallas, TX on April 28-29, 2022.

This is an open access article under the terms of the [Creative Commons Attribution-NonCommercial-NoDerivs](https://creativecommons.org/licenses/by-nc-nd/4.0/) License, which permits use and distribution in any medium, provided the original work is properly cited, the use is non-commercial and no modifications or adaptations are made.

© 2022 The Authors. *Laryngoscope Investigative Otolaryngology* published by Wiley Periodicals LLC on behalf of The Triological Society.

## KEYWORDS

ballistic injury, facial nerve, gunshot wound, temporal bone, temporal bone fracture

## 1 | INTRODUCTION

Gunshot wounds (GSW) to the temporal bone are the etiology of only 3% of temporal bone fractures.<sup>1</sup> In spite of their rarity, GSW deserve special consideration due to the greater potential for severe and extensive damage compared with blunt trauma.<sup>2</sup> Injury severity depends on wound site, range (distance of the firearm from the wound), as well as the kinetic energy, material, and caliber of the bullet. The bullet's mass and caliber have less effect than its material: A full steel jacket is more likely to break bones, while copper and lead deform on impact expanding their diameter and releasing kinetic energy faster with a wider exit wound.<sup>3</sup>

The petrous temporal bone is the densest bone of the body requiring an estimated 1875 pounds of lateral force to fracture.<sup>4</sup> The bullet's velocity is the main driver of its kinetic energy ( $KE = \frac{1}{2}mv^2$ ) to achieve this force.<sup>5</sup> High-velocity firearms (primarily military) result in a low-blast effect with minimal skin disruption, but high-tissue damage as kinetic energy dissipates within that tissue. High-velocity bullets typically follow a straight path of destruction fracturing bone along the way. However, low-velocity firearms (including civilian 0.22- and 0.38-caliber handguns) demonstrate less destruction since the surrounding tissue can deflect the projectile's course more easily. Entrance and exit wounds may therefore not be directly connected.<sup>3</sup>

Structures at risk include those that travel within and immediately around the temporal bone. This includes the facial nerve, cochlea, labyrinth, ossicles, tympanic membrane, pinna, external auditory canal (EAC), carotid artery, jugular vein, dura, and lower cranial nerves. Orientation-based descriptions of temporal bone fractures used to describe blunt trauma, namely longitudinal or transverse fractures, do not seem to be useful for GSWs. Functional-based classification of whether the fracture spares or disrupts the otic capsule (of the inner ear) are more useful. However, due to acoustic trauma and labyrinthine concussion from a higher blast wave associated with GSW, sensorineural hearing loss is common even with a spared otic capsule.

In this study, we aimed to understand the patterns of temporal bone fracture and facial nerve injury from ballistic trauma.

## 2 | METHODS

Retrospective chart review was performed of 42 patients evaluated following temporal bone ballistic injury at a single institution, university-based level-one trauma center over a 10 year span (2012–2021). Institutional Review Board approval was obtained (Louisiana State University Health Sciences Center New Orleans IRB #1636, exempt). Inclusion criteria required a temporal bone fracture of any portion of the bone resulting from a gunshot wound. Patients who died within 72 hours were included in radiologic review of fracture patterns, but

excluded from all further analysis. Demographics, facial nerve status, CT images, interventions, complications, and outcomes were reviewed. Categorical variables were compared using a chi square test, where  $p < .05$  was considered significant (R statistical software, version 3.6.2).

## 3 | RESULTS

### 3.1 | Demographics

Most patients were male (79%) with a mean age of 30.3 years (range 5–58). The 67% were African American/Black, 19% white non-Hispanic, 7.1% white Hispanic, 2.4% Asian, 4.8% not identified. In Orleans Parish, 60.1% of residents are African American/Black, 30.9% white non-Hispanic, 5.5% white Hispanic, 2.9% Asian, 0.6% other. Thus, race/ethnicity of those injured approximated the demographics of the surrounding community. There were seven mortalities from nonsurvivable intracranial injuries, who were excluded from further analysis. Most GSW were due to interpersonal conflict, but 16% were self-inflicted and 5% overall were an accidental self-inflicted injury. Each ear was affected at approximately equal rates (52% right).

### 3.2 | Radiographic review

Overall on CT, the majority of fractures were otic capsule sparing. Commonly, the EAC and mastoid tip were fractured, with disruption of the periauricular soft tissues. Ossicular discontinuity was seen in one-third. Pneumolabyrinth was visible in one patient with anacusis and complete ipsilateral facial nerve palsy. Pneumocephalus was present in approximately half. The petrous apex was fractured in three patients, with involvement of the carotid canal in 2/3. EAC injury, mastoid tip fracture, periauricular soft tissue disruption and ossicular discontinuity were significantly more common in patients with facial nerve injury than without (see Table 1).

### 3.3 | Facial nerve injury

Nineteen patients (54%) demonstrated facial nerve injury. Of those, 13/19 displayed immediate paralysis, 1 delayed, 5 unknown (due to altered mental status). On consultation, House-Brackmann (HB) grade 6 paralysis was common (37%, see Table 2).<sup>6</sup> Fractures were otic capsule sparing in 17/19 (90%), universally comminuted, with significant disruption along the mastoid tip (16/19), EAC (15/19), and periauricular soft tissues (13/19).

Electroneurography was unfortunately not available at our institution. Therefore, decision for surgery was based on timing of facial nerve

**TABLE 1** Temporal bone CT findings

	With FNI	Without FNI	Total (%)	<i>p</i>
Otic capsule sparing	17 (89%)	15 (94%)	37 (88%)	1
Otic capsule disrupting	2 (11%)	1 (6%)	4 (10%)	1
Ossicular discontinuity	9 (47%)	1 (6%)	13 (31%)	.02
Pneumolabyrinth	1 (5%)	0 (0%)	1 (2%)	.54
EAC injury	15 (79%)	2 (13%)	22 (52%)	.0003
Mastoid tip involvement	16 (84%)	3 (19%)	20 (48%)	.0004
Periauricular soft tissue disruption	13 (68%)	1 (6%)	15 (36%)	.0007
Petrous apex involvement	2 (11%)	1 (6%)	3 (7%)	1
Pneumocephalus	5 (26%)	8 (50%)	20 (48%)	.27
	<i>n</i> = 19	<i>n</i> = 16	<i>n</i> = 42	

Abbreviations: EAC, external auditory canal; FNI, facial nerve injury.

**TABLE 2** House-Brackmann score at time of consultation compared with final outcome at last documented visit

HB score	At consultation: No. (%)	Final: No. (%)
6	13 (37%)	6 (17%)
5	1 (3%)	2 (6%)
4	0 (0%)	2 (6%)
3	1 (3%)	2 (6%)
2	2 (6%)	2 (6%)
1	18 <sup>a</sup> (51%)	21 (61%)

Abbreviations: No., number of patients; % = percentage of patients.

<sup>a</sup>Includes two patients with peripheral branch weakness (one temporal branch, one marginal mandibular branch).

paralysis (immediate, complete ipsilateral paralysis), radiographic findings to suggest injury (ballistic fragments and/or bony spicules disrupting fallopian canal), and medical stability. Table 3 lists the facial nerve status of each patient with facial nerve injury and decision making for each patient.

Nine patients underwent surgical intervention: Transmastoid facial nerve decompression to remove compressive bony spicules (*n* = 5); eye protection surgery (*n* = 3); and peripheral facial nerve exploration (*n* = 1), noting transection at the pes. One required middle cranial fossa and transmastoid repair of cerebrospinal fistulae in setting of severe meningitis. 10/19 patients (52%) with facial nerve involvement improved HB score. Of the 5 patients who underwent transmastoid nerve decompression, 4/5 (80%) improved despite CT evidence of likely additional injury in its extratemporal course. The one who did not improve underwent facial nerve decompression 1 year after injury during concomitant tympanomastoidectomy for cholesteatoma removal.

### 3.4 | Audiologic results

Eleven patients (58%) with facial nerve injury underwent audiologic testing. Five demonstrated sensorineural hearing loss, three showed mixed loss, two had purely conductive loss, and one retained normal hearing levels. Mean pure tone average was 83 ± 34 dB (median 76 dB), mean bone line average was 47 ± 27 dB (median 41 dB), and

mean word recognition score was 48 ± 51% (median 43%). Six patients failed to undergo audiologic testing and were lost to follow-up, and two transferred their postoperative care to another institution.

## 3.5 | Case reports of surgical patients

### 3.5.1 | Patient 4

The 21-year-old male with a GSW to the left temple noted to have a left otic capsule sparing comminuted TB fracture involving the EAC and TMJ. The bullet trajectory included the left preauricular soft tissues, the C1 transverse process, C2 lateral mass, and spinous processes of C3-4. Immediate onset complete facial paralysis. On the day of injury, he underwent an extratemporal facial nerve dissection, where transection of the main trunk was noted at the pes anserinus. The proximal stump and multiple distal branches were identified and tagged for planned subsequent reanastomosis and nerve grafting. He did not present to his scheduled clinics appointments, including audiogram, and was lost to follow-up.

### 3.5.2 | Patient 11

The 18-year-old female with shotgun blast to the temple was noted to have a comminuted otic capsule sparing fracture. Immediate, complete facial paralysis was noted. She underwent transmastoid canal wall down facial nerve decompression with improvement to HB 4/6. Gold weight eyelid loading was performed and botulinum toxin injections were performed routinely for synkinesis. Eight years later due to persistent otorrhea in setting of anacusis, she underwent subtotal petrosectomy with EAC overclosure.

### 3.5.3 | Patient 18

The 13-year-old male presented after self-inflicted GSW with right mandible, maxilla, zygoma and temporal bone fractures with

**TABLE 3** Outcomes for patients who did not undergo decompression

Patient	Initial HB score	Reason decompression not performed	Final HB score	Follow-up duration
1	1/6	Only temporal branch paralysis	1/6	3 days (lost)
3	6/6	Multiple intracranial hemorrhages, multiple I&D of abscesses, developed cranial osteomyelitis; lost to follow-up	6/6	43 days (lost)
4	6/6	Obvious injury in extratemporal facial nerve; Underwent exploration and tagging, but patient lost to follow-up prior to definitive repair	6/6	4 days (lost)
7	5/6	Partial paralysis only	4/6	1 day (lost)
10	2/6	Partial paralysis only	2/6	8 months
11	6/6	N/A (underwent decompression–bony spicules/ballistic fragments noted)	4/6	9 years
12	2/6	Partial paralysis only	1/6	2 months (lost)
18	6/6	Transferred to Children's Hospital before acute facial decompression performed/underwent attempted decompression 1 year later at time of surgery for cholesteatoma, which was unsuccessful	6/6	2 years
19	6/6	Facial function improved with steroids while recovering from watershed infarcts after ICA coiling	3/6	2 months (lost)
20	6/6	Concern for comminution with possible worsening of the injury and CSF leak	5/6	9 months (lost)
22	6/6	No expectation of benefit: severity of soft tissue disruption including the facial nerve as it traversed the parotid	6/6	17 months
27	6/6	N/A (underwent decompression bony spicules/ballistic fragments noted on CT)	5/6	1 month (lost)
29	6/6	Resolved with steroids; visible improvement within 4 days (to HB 3/6 at hospital discharge)	1/6	3 months
31	1/6	Only marginal mandibular branch weak	1/6	2 months
33	3/6	Delayed onset of paralysis/resolved with steroids	1/6	4 months
35	6/6	Severity of injuries, surgery for large CSF leak in setting of severe meningitis	6/6	2 months (lost)
36	6/6	N/A (underwent decompression–bony spicule/ballistic fragments on CT)	3/6	2 months (lost)
37	6/6	Severity of spinal injuries; facial nerve exploration planned after discharge but lost to follow-up after acute rehabilitation stay	6/6	1 month (lost)
42	6/6	N/A (underwent decompression–ballistic fragments on CT)	2/6	6 months

Abbreviations: CSF, cerebrospinal fluid; HB, House-Brackmann; I&D, incision and drainage; ICA, internal carotid artery; N/A, not applicable.

immediate, complete facial paralysis noted. Otic capsule sparing fracture disrupted the EAC and preauricular soft tissues with bullet fragments lodged in the inferior mastoid. The entrance wound was at the right chin and exit right infratemporal fossa and EAC. After initial stabilization, he was transferred to a pediatric hospital for further ICU care. One year later, cholesteatoma and persistent HB 6/6 palsy was noted. Tympanomastoidectomy for cholesteatoma removal with transmastoid facial nerve exploration was performed. Dense scar was noted at the stylomastoid foramen, and the main facial nerve trunk could not be positively identified. Two years after injury, he underwent cross facial grafting with the sural nerve in anticipation of planned gracilis free flap for dynamic facial nerve reanimation.

### 3.5.4 | Patient 20

The 26-year-old male presented with GSW to left face and hip. Entrance wound was noted at the left inferomedial cheek with a

preauricular exit wound. He had an immediate HB grade 6/6 palsy, with a left otic capsule sparing comminuted temporal bone fracture involving the EAC, TMJ, and mastoid tip with ballistic fragments and air near the stylomastoid foramen. Decision at time of injury was to not perform decompression due to concern for comminution with possible worsening of the injury and CSF leak. He followed up initially, then had multiple canceled appointments. Nine months after injury, he underwent gold weight eyelid loading and lateral tarsoconjunctival flap, did not present to his postoperative appointment and was lost to follow-up. Facial nerve function at time of last encounter was HB 5/6, 9 months after injury.

### 3.5.5 | Patient 22

The 37-year-old male with accidental shotgun blast to the face causing very extensive disruption of preauricular soft tissues and mandible. Left otic capsule sparing fracture involved the EAC and mastoid

tip with ballistic fragments at the stylomastoid foramen. Decompression was not offered due to the severity of soft tissue disruption including the facial nerve as it traversed the parotid. He underwent ORIF of his facial fractures and multiple surgeries to repair his soft tissue defects including vastus lateralis myocutaneous free flap. His eye was protected with gold weight loading and lateral tarsoconjunctival flap, then revision gold weight and tarsal strip procedure. His course was complicated by multiple infections with draining purulence from the and lacerations and EAC, as well as facial/neck abscesses requiring several washouts. Cross facial grafting utilizing the sural nerve was performed 15 months after injury in anticipation of planned gracilis free flap.

### 3.5.6 | Patient 27

The 16-year-old male with GSW to head, face and right leg. Right otic capsule disrupting TB fracture resulted in pneumolabyrinth and bony spicules/ballistic fragments along the tympanic and mastoid segments as well as air within the infratemporal fossa. Vascular injuries were treated with coil embolization of the bilateral internal maxillary arteries and antiplatelet therapy (aspirin 81 mg) for stable clot in the sigmoid and transverse dural venous sinuses. After stabilization from his temporal lobe injuries, he underwent transmastoid facial nerve decompression (4 days postinjury). Impinging bony spicules were removed from the tympanic and mastoid segments and a compressive hematoma at the inferior mastoid was drained. The nerve was noted to be partially transected at the stylomastoid foramen and was laid in approximation. Extratemporal facial nerve exploration was planned one month later, at which time facial movement had improved to HB 5/6, so exploration was deferred to observe for return of facial nerve movement before considering other repair or reanimation procedures. Gold weight eyelid loading and lateral tarsoconjunctival strip was performed.

### 3.5.7 | Patient 35

The 19-year-old female with multiple GSW including to cheek, head and neck with an immediate, complete facial paralysis. CT demonstrated a right otic capsule sparing TB fracture with wide separation of the mastoid down to the level of stylomastoid foramen, disruption of EAC and ossicles, petrous carotid artery, with a large exit wound in the right midface. Concomitant cranial nerve III and IV palsies were present. Emergent decompressive craniectomy and multiple endovascular interventions were performed. Two weeks postinjury, an abscess developed under her scalp flap with severe meningitis and large CSF leak through the temporal bone and sphenoid sinus. She underwent middle cranial fossa repair of large dural and skull base defect, subtotal petrosectomy with EAC overclosure, external ventriculostomy drain placement. Since her operation was in the setting of severe meningitis, no facial nerve exploration was performed due to her critical illness.

### 3.5.8 | Patient 36

The 20-year-old male with a GSW to right neck, ear, and knee and immediate, complete facial paralysis. CT revealed right otic capsule sparing comminuted TB fracture involving the right periauricular soft tissues and mastoid tip with bone fragments around the facial nerve at the stylomastoid foramen. Unstable C2 fracture was treated with immobilization with a C-collar and thrombosis of the right vertebral artery in the neck from level C7 through the V4 segment without obvious extravasation. Following stabilization, on the 6th day postinjury, transmastoid facial nerve decompression was performed including removal of a bony spicule at the stylomastoid foramen. His facial nerve function improved to a HB 4/6 at 6 weeks, then 3/6 at 2 months, before he was lost to subsequent follow-up.

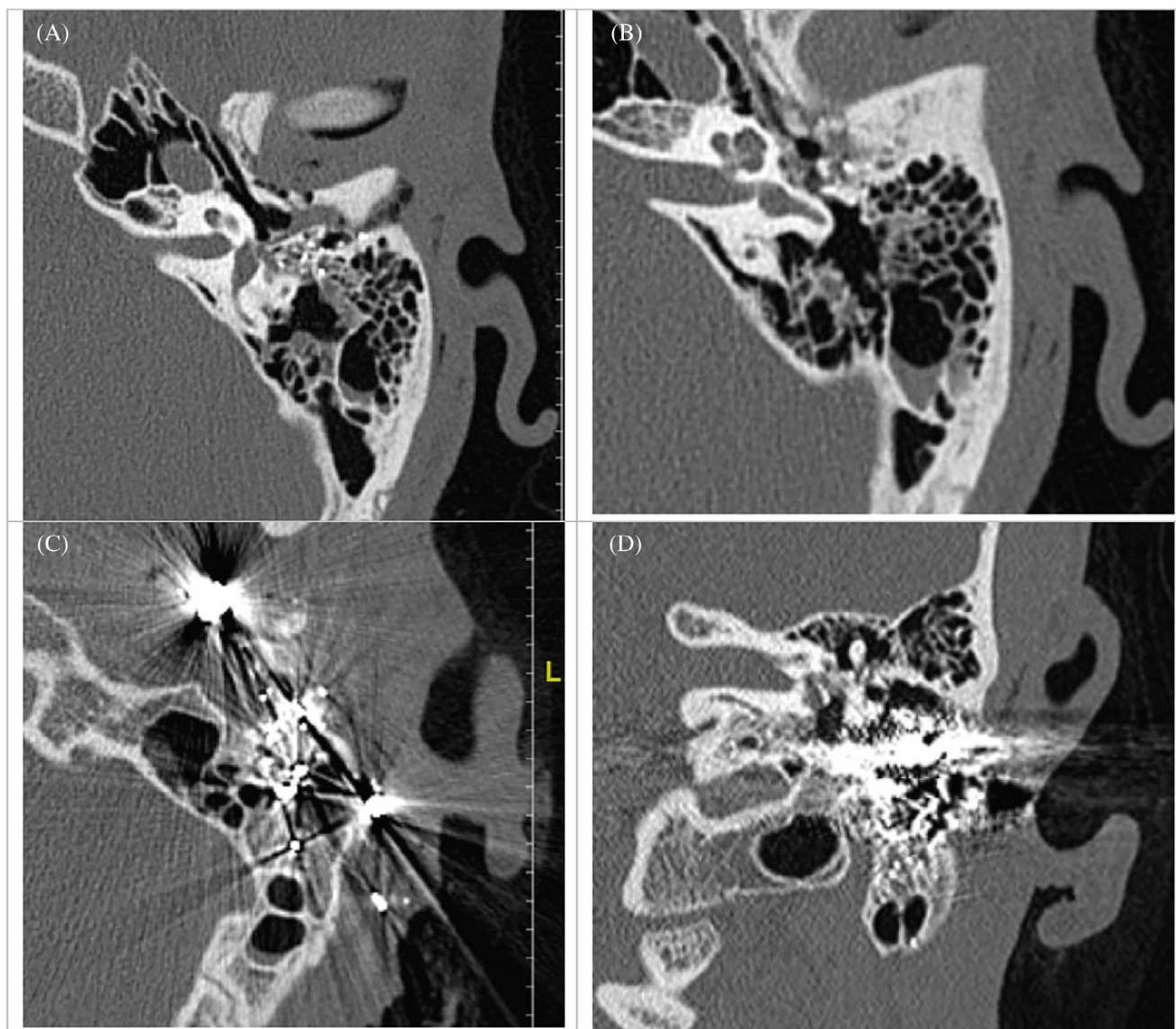
### 3.5.9 | Patient 42

The 16-year-old male with multiple GSW to head, face, extremities, pelvis, abdomen, and an immediate, complete facial paralysis. CT demonstrated left otic capsule sparing comminuted TB fracture with bullet fragments against the tympanic and vertical segments of the facial nerve, incus dislocation, large disruption of anterior and posterior EAC with bullet and bony fragments in EAC (see Figure 1). He underwent exploratory laparoscopy and bowel resection, ORIF of facial fractures and orthopedic fractures. After stabilization, 4 days after injury, transmastoid decompression of the facial nerve and simultaneous canal wall down tympanomastoidectomy with ossiculoplasty was performed. His facial nerve function improved to HB 2/6.

## 4 | DISCUSSION

Evaluation of the patient begins with a full history including the mechanism of injury and type of gun used (high or low velocity). Full head and neck physical exam should be performed with special attention to any concomitant airway or facial trauma, full cranial nerve exam, and otoscopy to evaluate for hemotympanum, canal lacerations, or cerebrospinal otorrhea. Tuning fork exam is helpful if mental status allows. Most often, some of these history and exam elements must be obtained at a second evaluation when the patient is extubated and mental status clears. However, it is paramount that the facial nerve be evaluated at the earliest possible point as the decision for surgical intervention depends on whether the paralysis was complete/immediate or partial/delayed. The imaging should be reviewed with attention to the full course of the facial nerve, status of the EAC, ossicular chain, otic capsule, and carotid canal as well as any intracranial or spinal injuries that may complicate interventions.

In our series, 54% of patients demonstrated facial nerve injury, with most of these being an immediate and complete facial paralysis, suspicious for direct facial nerve injury. This represents a much higher incidence of facial nerve injury than that found in blunt trauma. Facial nerve injury occurs in approximately 7% of patients with temporal



**FIGURE 1** CT temporal bone of left temporal bone GSW penetrating injury, Patient 42. (A) External auditory canal fracture of anterior canal with large mastoid fistula, ballistic fragments at the at the facial nerve second genu. (B) Disrupted ossicular chain (incus dislocation seen here; intraoperatively, posterior crus of stapes also fractured). (C) Ballistic fragments extend into soft tissue around stylomastoid foramen and periauricular soft tissues. (D) Ballistic fragments causing artifact obscuring mastoid segment of fallopian canal

bone fractures overall.<sup>1,7</sup> The frequency in our series is consistent with other small series reporting increased rates of facial nerve injury following GSW to the temporal bone of 27%–75%,  $n = 8$ –43.<sup>8–13</sup>

Despite multiple publications regarding management of facial nerve injury after temporal bone trauma, the subject remains controversial. To assist surgical decision making in the acute setting, ideally electrodiagnostic testing is performed to assess nerve function in patients with immediate, complete facial paralysis. Electroneurography can help distinguish degenerated nerves from neuropraxic nerves. Performed 72 hours after injury (following onset of Wallerian degeneration) and most accurate within 3 weeks of injury, electroneurography demonstrating >95% degeneration indicates a poor prognosis for complete recovery.<sup>7</sup> Unfortunately, electrodiagnostic testing often cannot be obtained in the acute or inpatient setting at

many trauma centers, including ours. Thus, in a patient with immediate, complete facial nerve paralysis, surgeons often rely on a CT scan with visible bony spicules or small ballistic fragments impinging on the fallopian canal. Larger ballistic fragments often cause radiographic artifact, making an assessment of fallopian canal disruption difficult. Patient with delayed or incomplete facial nerve weakness are usually treated with systemic steroids, unless contraindicated by their other injuries. In immediate, complete facial nerve paralysis, decompression and exploration should be performed after the patient is stabilized from their other injuries. In a published literature review of blunt trauma, decompression was found to be beneficial if performed less than 14 days from injury, while late exploratory surgery in those with inadequate recovery of facial nerve function typically requires nerve repair.<sup>7</sup>

Bento and de Brito (2004) performed a retrospective review of 98 patients with facial nerve injury after GSW to the temporal bone. All were surgically treated, most with cable grafting, and followed for 2 years postoperatively. Postoperative infection was common. The authors concluded that the stylomastoid foramen/extratemporal facial nerve should be explored since the facial nerve injury was often in close proximity.<sup>2</sup>

While we agree that injury to the extratemporal facial nerve should be evaluated and considered, our series elucidates that there is still value to performing transmastoid facial nerve decompression even when suspicion for concomitant extratemporal injury exists. Two patients who underwent transmastoid facial nerve decompression had evidence of likely concomitant extratemporal facial nerve injury. Patient 27 had injury just distal to the stylomastoid foramen with a partial transection, and the damaged nerve edges were laid in approximation with decision made for staged extratemporal exploration and repair. He improved at 1 month to HB 5/6 in spite of this and decision was made to observe expectantly, though he was unfortunately lost to follow-up thereafter. Thus, he improved even in spite of concomitant extratemporal injury, though it is unclear if he would have had an improved outcome if subsequent repair had been performed. CT imaging in Patient 36 revealed bony spicule at stylomastoid foramen and soft tissue disruption in the infratemporal fossa and periauricular soft tissues suspicious for extratemporal facial nerve injury. The bony spicule was removed at the stylomastoid foramen and he improved to HB 3/6 at 2 months before being lost to follow-up. Improvement was noted with transmastoid approach alone, though due to his truncated follow-up it is unclear his final outcome and if he would have further improved with transcervical exploration and repair.

All patients who underwent transmastoid decompression in the acute period (<14 days) had improvement in their facial nerve function. Decompression was performed from the geniculate ganglion to the stylomastoid foramen. Due to the location of the fracture usually in the mastoid tip and external and middle ear, most facial nerve injuries were in the tympanic and mastoid segments, which can be accessed via a transmastoid approach alone without concomitant middle cranial fossa or translabyrinthine approach to the more proximal segments. This is fortunate as most patients (57%) had concomitant intracranial injuries and would be higher risk of complication from a craniotomy. However, no patients achieved normal (HB grade 1) facial nerve function following surgical decompression. Edema of the nerve could have extended proximal to the location of the injury, and it is not known if decompression proximal to the geniculate ganglion would have improved outcomes.

While observing the patient following facial nerve injury, protection of the eye from exposure keratitis and its risk of blindness is paramount. When lagophthalmos is noted, initial eye protection includes lubricating eye drops frequently during the day, lubricating ointment at night, and eye taping. For patients expected to have persistent lagophthalmos for greater than 3 months, surgical intervention is indicated. We have transitioned from gold weight to platinum weight due to lower profile and decreased reactivity of the latter. Eyelid coupling

or tightening may additionally be considered including lateral tarsoconjunctival flap or lateral tarsal strip procedure.

If facial nerve exploration or repair must be delayed (intracranial injuries, unstable spinal fractures, severe recurrent infections including meningitis, and others), extratemporal facial nerve reanimation procedures can be considered. Older series relied on static reanimation procedures and hypoglossal-facial anastomoses.<sup>9-11</sup> Our preference is to perform dynamic procedures including cross-facial grafting followed by gracilis free flap in the cooperative patient.

The patient population of GSW to the temporal has some unique challenges including social issues related to interpersonal violence that may be on-going or intentional self-inflicted injuries, interactions with law enforcement, concomitant traumatic brain injuries impacting executive functioning, and a frequent need for acute rehabilitation following hospital discharge. Due to these and likely other unknown issues, there is a high rate of loss of follow-up. In our series, 26% did not show for initial clinic evaluation after discharge, with 63% eventually lost to follow-up when additional interventions had been planned. This includes one patient who underwent peripheral facial nerve exploration with tagging of the proximal and distal segments but did not proceed to definitive grafting. When the patient's other injuries and condition allow, every effort should be made to perform the definitive surgical repair prior to hospital discharge.

#### 4.1 | Limitations

This study is limited by its retrospective nature and small sample size due to the relative rarity of the injury. Regarding timing, four patients were decompressed in the acute period (after medical stabilization and within 3 weeks of injury), and one attempt was made in a chronic setting (1 year after injury), which was unsuccessful (the surgeon was unable to localize the facial nerve at the stylomastoid foramen due to extensive scarring and nerve degeneration). No attempts to decompress the nerve were performed in an intermediate setting, so further conclusions regarding surgical timing cannot be formed.

Additionally, the extent of the decompression was not independently evaluated. Transmastoid facial nerve decompression from the geniculate ganglion to the stylomastoid foramen was performed. No patients were offered decompression proximal to the geniculate ganglion due to their concomitant intracranial injuries and lack of radiographic evidence of bony disruption of the fallopian canal in that location. However, significant facial nerve edema may have extended proximally to affect outcomes with impingement of the nerve at the fallopian canal's narrowest point in its labyrinthine segment. Notably, the best outcome of patients in our series following decompression was House-Brackmann grade 2/6. It is unclear if this outcome could have been improved with the addition of more proximal decompression; therefore, we cannot draw further conclusions.

Finally, many patients with facial nerve injuries were lost to follow-up (26% initially, and 63% when additional intervention was still planned). This included five patients with a HB grade 6/6 paralysis at last visit, limiting abilities to draw conclusions regarding those patients.

## 5 | CONCLUSION

Orientation-based (longitudinal/transverse) and functional-based (otic capsule sparing/disrupting) classifications are not useful descriptors for ballistic temporal bone injury. Instead, injury was commonly seen in the EAC, mastoid tip, and periauricular soft tissues. There is a high risk of facial nerve injury, often in the mastoid segment near the stylo-mastoid foramen. Clinicians should maintain high suspicion for concomitant extratemporal facial nerve injury. However, facial nerve decompression in the acute period, even in setting of extratemporal injury is likely to be beneficial.

### CONFLICT OF INTEREST

The authors declares there is no potential conflict of interest.

### ORCID

Anne K. Maxwell  <https://orcid.org/0000-0001-7270-2552>

### REFERENCES

1. Brodie HA, Thompson TC. Management of complications from 820 temporal bone fractures. *Am J Otol.* 1997;18(2):188-197.
2. Bento RF, de Brito RV. Gunshot wounds to the facial nerve. *Otol Neurotol.* 2004;25(6):1009-1013.
3. Yetiser S, Kahramanyol M. High-velocity gunshot wounds to the head and neck: a review of wound ballistics. *Mil Med.* 1998;163(5):346-351.
4. Travis LW, Stalnaker RL, Melvin JW. Impact trauma of the human temporal bone. *J Trauma.* 1977;17(10):761-766.
5. Kennedy KL, Cash E, Petrey J, Lin JW. Temporal bone fractures caused by ballistic projectiles: a systematic review. *Otolaryngol Head Neck Surg.* 2021;164(6):1160-1165.
6. House JW, Brackmann DE. Facial nerve grading system. *Otolaryngol Head Neck Surg.* 1985;93:146-147.
7. Chang CYJ, Cass SP. Management of facial nerve injury due to temporal bone trauma. *Am J Otol.* 1999;20:96-114.
8. Hooper RE, Ruben RJ, Mahmood K. Gunshot injuries of the temporal bone. *Arch Otolaryngol.* 1972;96(5):433-440.
9. Hagan WE, Tabb HG, Cox RH, Travis LW. Gunshot injury to the temporal bone: an analysis of thirty-five cases. *Laryngoscope.* 1979;89(8):1258-1272.
10. Duncan NO, Coker NJ, Jenkins HA, Canalis RF. Gunshot injuries of the temporal bone. *Otolaryngol Head Neck Surg.* 1986;94(1):47-55.
11. Shindo ML, Fetterman BL, Shih L, Maceri DR, Rice DH. Gunshot wounds of the temporal bone: a rational approach to evaluation and management. *Otolaryngol Head Neck Surg.* 1995;112(4):533-539.
12. Haberkamp TJ, McFadden E, Khafagy Y, Harvey SA. Gunshot injuries of the temporal bone. *Laryngoscope.* 1995;105(10):1053-1057.
13. Sabin SL, Lee D, Har-el G. Low velocity gunshot injuries to the temporal bone. *J Laryngol Otol.* 1998;112(10):929-933.

**How to cite this article:** Maxwell AK, Lemoine JC, Kahane JB, Gary CC. Management of the facial nerve following temporal bone ballistic injury. *Laryngoscope Investigative Otolaryngology.* 2022;7(5):1541-1548. doi:[10.1002/lio2.880](https://doi.org/10.1002/lio2.880)