

Contents lists available at [ScienceDirect](#)

## International Journal of Surgery Case Reports

journal homepage: [www.casereports.com](http://www.casereports.com)

# Spontaneous flexor tendon rupture due to an insufficiency fracture of the hamate hook in a patient with systemic lupus erythematosus: A case report



Toshihiro Hosokawa, Ryo Oda\*, Shogo Toyama, Daigo Taniguchi, Daisaku Tokunaga, Hiroyoshi Fujiwara, Toshikazu Kubo

Department of Orthopaedics, Graduate School of Medical Science, Kyoto Prefectural University of Medicine, Kyoto, Kawaramachi-Hirokoji, Kamigyo-ku, Kyoto 602-8566, Japan

## ARTICLE INFO

## Article history:

Received 25 April 2016

Received in revised form 30 June 2016

Accepted 30 June 2016

Available online 1 July 2016

## Keywords:

SLE

Flexor tendon rupture

Insufficiency fracture

Hamate hook

Steroid

Case report

## ABSTRACT

**INTRODUCTION:** Spontaneous flexor tendon rupture is usually caused by trauma, systemic diseases, or carpal bone and joint disorders. Here we report a case of spontaneous flexor tendon rupture occurring in a systemic lupus erythematosus (SLE) patient following nonunion of the hamate hook after an insufficiency fracture, and which was also associated with tendon degeneration caused by SLE.

**CASE PRESENTATION:** A 57-year-old woman was diagnosed with SLE 22 years ago and being treated with oral prednisolone. She became unable to flex her left little finger without any history of trauma or sporting activity. CT showed nonunion of the hamate hook. MRI showed rupture of the flexor digitorum profundus tendon of the little finger. We performed tendon transfer and excision of the hamate hook. She recovered active flexion of the little finger at 4 months postoperatively with full satisfaction.

**DISCUSSION:** There was no history of trauma that could have caused nonunion of the hamate hook. We considered that the insufficiency fracture of the hamate hook occurred as a result of osteoporosis caused by SLE and long-term steroid use. Nonunion of the hamate hook caused mechanical attrition of the tendons, and in combination with the tendon degeneration caused by SLE, further resulted in rupture of the flexor tendon.

**CONCLUSION:** When we encounter a case of spontaneous flexor tendon rupture in a patient with systemic disease such as SLE or long-term steroid use, attention should be paid to the state of the carpal bones and joints as they sometimes accompany unexpected causes.

© 2016 The Authors. Published by Elsevier Ltd on behalf of IJS Publishing Group Ltd. This is an open access article under the CC BY-NC-ND license (<http://creativecommons.org/licenses/by-nc-nd/4.0/>).

## 1. Introduction

Spontaneous flexor tendon rupture is usually caused by (1) trauma, (2) carpal bone and joint disorders, such as malunion of wrist fracture or osteophytes, or arthritis, (3) underlying systemic disease such as rheumatoid arthritis (RA), and (4) drug-related such as steroid injections at tendon sheath or intake of oral agents [1]. Nonunion of the hamate hook is one of the important causes of flexor tendon rupture in the little finger. Hamate hook fractures are rare, accounting for about 2–4% of carpal bone fractures. This fractures are usually caused by trauma or the repeated impacts during sports like golf or racket sports [2]. Here, we report a case of spontaneous flexor tendon rupture occurring in a systemic lupus erythematosus (SLE) patient following nonunion of the hamate

hook after an insufficiency fracture, and which was also associated with tendon degeneration caused by SLE.

## 2. Case presentation

The patient was a 57-year-old right-hand dominant woman, office worker. She was diagnosed with SLE 22 years ago and was being treated with oral prednisolone at a dose of 5 mg/day and mizoribine at a dose of 200 mg/day. There was no obvious history of trauma or sporting activities. While opening the car door, the patient became unable to flex her left little finger, and visited our hospital 6 weeks later. Active flexion of the proximal interphalangeal (PIP) joint of the left little finger was possible, but active flexion of the distal interphalangeal (DIP) joint was not. Physical examination revealed no swelling or redness in her right palm. Total active motion (TAM) was 190° (percent TAM, 70%). Grip strength was 14.8 kg on the right side and 13.0 kg on the left side. Blood tests showed a leukocyte count of 7700 cells/ $\mu$ l, and a CRP of 0.40 mg/dl. Plain X-ray images of the wrist joint showed no remarkable findings, but CT showed nonunion of the hamate hook. (Fig. 1a,b). Rupture of the flexor digitorum profundus (FDP) tendon of the lit-

\* Corresponding author.

E-mail addresses: [t-hoso@koto.kpu-m.ac.jp](mailto:t-hoso@koto.kpu-m.ac.jp) (T. Hosokawa), [r-oda@koto.kpu-m.ac.jp](mailto:r-oda@koto.kpu-m.ac.jp) (R. Oda), [shogo.toyama@gmail.com](mailto:shogo.toyama@gmail.com) (S. Toyama), [daigo1@koto.kpu-m.ac.jp](mailto:daigo1@koto.kpu-m.ac.jp) (D. Taniguchi), [dai@koto.kpu-m.ac.jp](mailto:dai@koto.kpu-m.ac.jp) (D. Tokunaga), [fjwr@koto.kpu-m.ac.jp](mailto:fjwr@koto.kpu-m.ac.jp) (H. Fujiwara), [tkubo@koto.kpu-m.ac.jp](mailto:tkubo@koto.kpu-m.ac.jp) (T. Kubo).

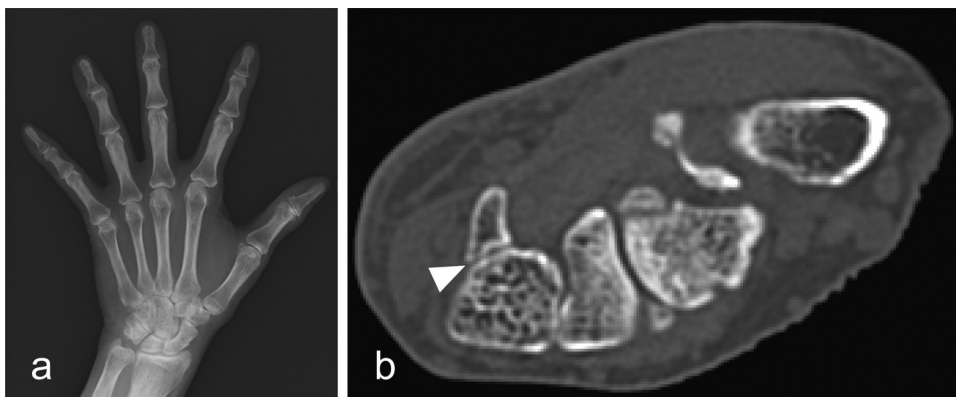


Fig. 1. (a) Plain X-ray image (b) CT image (arrow head: nonunion of the hamate hook).

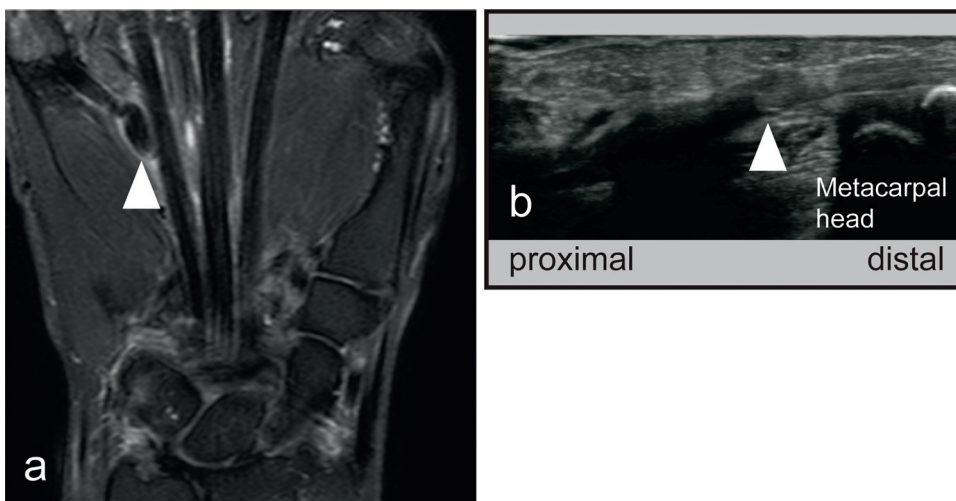


Fig. 2. (a) MRI (arrow head: distal stump of the FDP of the little finger) (b) ultrasound image (arrow head: Distal stump of the FDP of the little finger).

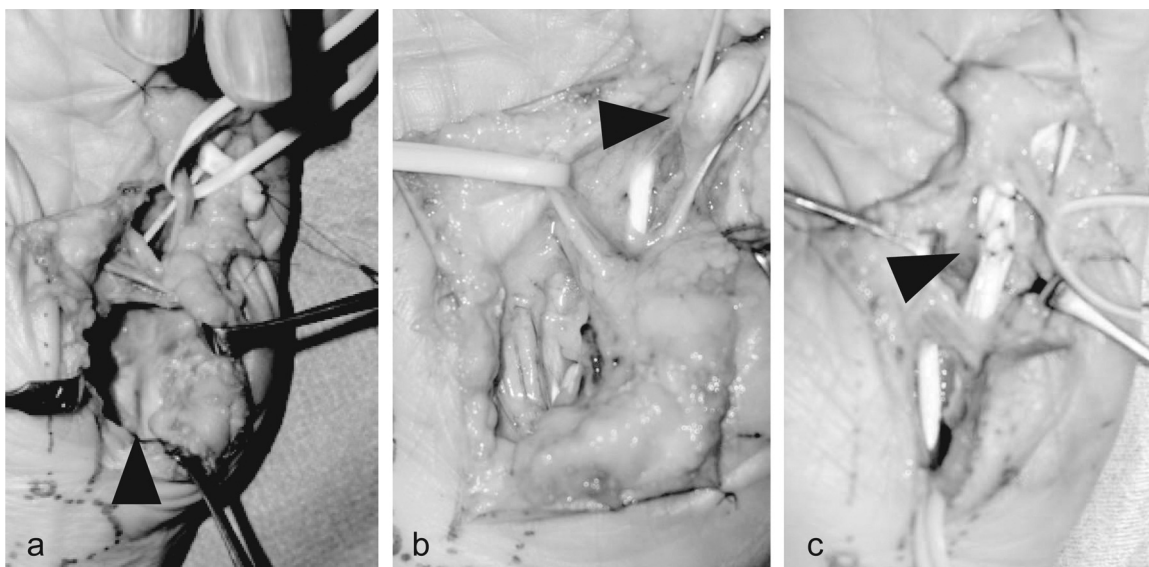


Fig. 3. (a) Nonunion of the hamate hook (arrow head) (b) distal stump of the FDP tendon (arrow head) (c) tendon transfer (arrow head).

tle finger was noted on MRI and ultrasound (Fig. 2a,b). We planned tendon transfer and excision of the hamate hook. Intraoperatively, the FDP tendon was exposed through a palmar zig-zag incision. The FDP tendon of the little finger underwent degeneration and rupture at nonunion of the hamate hook. Both tendon ends showed fibrotic scar formation. The flexor digitorum superficialis (FDS) tendon of

the little finger showed moderate degeneration but it was continuous. The carpal tunnel was released to expose the hamate hook. There was a rupture of the joint capsule at the base of the hamate hook and osteophytes projected into the carpal tunnel. Nonunion of the hamate hook was identified and it was removed. Since the FDP tendon of the ring finger appeared intact, the distal stump of

the FDP of the little finger was transferred to the FDP of the ring finger using an interlacing suture (Fig. 3a–c). The pathological findings of the stump at the site of tendon rupture included perivascular infiltration by inflammatory cells, which were mainly lymphocytes and plasma cells, as well as villous changes in a part of the synovial membrane. These findings suggested the presence of SLE-related tenosynovitis. She recovered active flexion of the little finger at 4 months postoperatively with full satisfaction. At 6 months after surgery, TAM increased to 240° (percent TAM, 89%) in the little finger and grip strength was 12.6 kg.

### 3. Discussion

The hamate hook plays the role of a pulley for the little and ring fingers, and exerts mechanical stress on the flexor tendons as it glides over it. Rupture of flexor tendons occurs as a complication in approximately 15% of fractures and nonunion of the hamate hook due to increasing the mechanical stress at this site [3]. Hamate hook fractures are sometimes painless, and may be overlooked as the sensitivity of plain X-rays is low at 50–90%, even when using carpal tunnel views. CT scans demonstrate higher sensitivity at 94% and are recommended for the diagnosis of hamate hook fractures [4].

Chronic synovitis and tenosynovitis, arthritis, hand deformities such as Jaccoud's arthropathy, local steroid injections, and long-term oral steroid use can contribute to degeneration and increase the vulnerability of the flexor tendon in patients with SLE [5–7]. There have been case reports of spontaneous tendon rupture in patients with SLE such as the Achilles tendon, patellar tendon and digital extensor tendons, but there have been few reports regarding flexor tendon rupture [8–10]. We have previously reported a case of spontaneous tendon rupture of the ring and small fingers in a patient with SLE [11]. Furthermore, patients with SLE have increased risk for osteoporosis because of oral steroid use, systemic inflammation such as nephritis, metabolic disorder, and endocrine disorder. Thus, the rate of osteoporosis and fracture is higher than that in healthy women, and the risk of insufficiency fractures is reported to be high [12,13].

In the present case, there was no obvious history of trauma or sporting activity that could have caused nonunion of the hamate hook. We considered that the insufficiency fracture of the hamate hook occurred as a result of osteoporosis caused by SLE and long-term oral steroid use. Nonunion of the hamate hook caused mechanical attrition of the tendons, and in combination with the tendon degeneration caused by SLE, further resulted in spontaneous flexor tendon rupture. When treating spontaneous flexor tendon rupture associated with systemic disease such as SLE, it is important to perform CT scans as well as plain X-ray to reveal bone and joint damage which may be hidden cause of tendon rupture.

### 4. Conclusion

We reported a case of flexor tendon rupture occurring in a SLE patient following nonunion of the hamate hook after an insufficiency fracture, and which was also associated with tendon degeneration caused by SLE. When we encounter a case of spontaneous flexor tendon rupture in a patient with systemic disease such as SLE or long-term oral steroid use, attention should be paid to the state of the carpal bones and joints as they sometimes accompany unexpected causes.

### Conflict of interest

None.

### Funding source

Nothing to declare.

### Ethical approval

Not required.

### Author contribution

Toshihiro Hosokawa: acquired clinical data and wrote the manuscript, design and image providing, obtaining informed consent from patient, Ryo Oda: performing surgery, drafted and revised the manuscript and figure, Shogo Toyama: performing surgery, drafted and revised the manuscript and figure, obtaining informed consent from patient, Daigo Taniguchi, Daisaku Tokunaga, Hiroyoshi Fujiwara, Toshikazu Kubo: drafted and revised the manuscript and figure.

### Consent

Written informed consent was obtained from the patient for publication of this case report and accompanying images.

### Guarantor

Ryo Oda.

### References

- [1] D.T. Netscher, J.J. Badal, Closed flexor tendon ruptures, *J. Hand Surg.* 39 (2014) 2315–2323.
- [2] H.J. Boulas, M.A. Milek, Hook of the hamate fractures. Diagnosis, treatment, and complications, *Orthop. Rev.* 19 (1990) 518–529.
- [3] M.A. Milek, H.J. Boulas, Flexor tendon ruptures secondary to hamate hook fractures, *J. Hand Surg. Am.* 15 (1990) 740–744.
- [4] M.A. Klausmeyer, C.S. Mudgal, Hook of hamate fractures, *J. Hand Surg. Am.* 38 (2013) 2457–2460, quiz 60.
- [5] A.S. Zayat, M.Y. Md Yusof, R.J. Wakefield, et al., The role of ultrasound in assessing musculoskeletal symptoms of systemic lupus erythematosus: a systematic literature review, *Rheumatology (Oxford, England)* 55 (2016) 485–494.
- [6] M.B. Santiago, V. Galvao, Jaccoud arthropathy in systemic lupus erythematosus: analysis of clinical characteristics and review of the literature, *Medicine* 87 (2008) 37–44.
- [7] E.M. Alves, J.C. Macieira, E. Borba, et al., Spontaneous tendon rupture in systemic lupus erythematosus: association with Jaccoud's arthropathy, *Lupus* 19 (2010) 247–254.
- [8] Y.M. Chiou, J.L. Lan, T.Y. Hsieh, et al., Spontaneous Achilles tendon rupture in a patient with systemic lupus erythematosus due to ischemic necrosis after methyl prednisolone pulse therapy, *Lupus* 14 (2005) 321–325.
- [9] C.H. Pritchard, S. Berney, Patellar tendon rupture in systemic lupus erythematosus, *J. Rheumatol.* 16 (1989) 786–788.
- [10] H. Oishi, R. Oda, S. Morisaki, et al., Spontaneous tendon rupture of the extensor digitorum communis in systemic lupus erythematosus, *Mod. Rheumatol.* 23 (2013) 608–610.
- [11] R. Oda, H. Fujiwara, D. Tokunaga, et al., Spontaneous flexor tendon rupture in systemic lupus erythematosus: a case report, *Mod. Rheumatol.* (2014) 1–4.
- [12] I.E. Bullink, Osteoporosis and fractures in systemic lupus erythematosus, *Arthritis Care Res.* 64 (2012) 2–8.
- [13] R. Ramsey-Goldman, J.E. Dunn, C.F. Huang, et al., Frequency of fractures in women with systemic lupus erythematosus: comparison with United States population data, *Arthritis Rheum.* 42 (1999) 882–890.

### Open Access

This article is published Open Access at [sciendoirect.com](http://sciendoirect.com). It is distributed under the [IJSCR Supplemental terms and conditions](#), which permits unrestricted non commercial use, distribution, and reproduction in any medium, provided the original authors and source are credited.