

Case Report

Adult T-cell lymphoma associated with HTLV-1: An atypical case report

Mariana Abdo de Almeida ^{a,*}, Lívia Reis de Miranda ^b,
Raquel Ferrari Marchesi ^c

^a Universidade de Taubaté (Unitau), Taubaté, SP, Brazil

^b Hospital Regional do Vale do Paraíba, Taubaté, SP, Brazil

^c Faculdade de Medicina da Universidade de São Paulo (FMUSP), SP, Brazil

ARTICLE INFO

Article history:

Received 10 February 2020

Accepted 18 February 2021

Available online 20 May 2021

The adult T-cell leukemia/lymphoma (ATL) is a rare and aggressive lymphoproliferative disease caused by Human T-lymphotropic virus type 1 (HTLV-1), which is usually fatal and unresponsive to chemotherapy. It occurs in about 2.5% of infected individuals and it manifests, in general, after a long latency period.¹

ATL has been classified into four clinical subtypes: acute, chronic, lymphoma, and smoldering.¹ Another clinical form, the primary cutaneous tumoral (PCT), with more far specific characteristics, has recently been suggested.²

PCT lesions can be present in about 40 to 70% of the cases.² In the present report, however, the patient presents significant cutaneous lesions, and his diagnostic parameters do not fit the most standard classic categorization of this disease.

Case report

A 61-year-old male patient, single, bus farecollector, was referred to the hematology center reporting nodules in his

hands, which were itching and burning for 8 months, presenting progressive increase and dissemination of the same nodules (Figure 1). The patient denied weight loss, fever, and sweating. There was no evidence of sexually transmitted diseases.

In a previous hospital, the patient was submitted to a dermatology evaluation, and an incisional biopsy was performed. The histopathological analysis revealed lymphoproliferative neoplasia characterized by intermediate to large lymphocytes, T-immunophenotype, with a diffuse and perianaxial infiltration pattern, involving the dermis and subcutaneous tissue with focus of necrosis (Figure 2). Immunohistochemistry showed a high proliferative index to Ki-67, immunorepression of T- markers (CD3, CD4, CD5, and CD8), with loss of CD7 expression. CD25 and FOXP3 expressions were not significant. Although the CD25 and FOXP3 results are not typical ATL findings, once they usually come with CD25 and FOXP3 diffuse immunorepression,³ these findings could suggest ATL if associated with clinical data. In the previous evaluation, HTLV-I virus serology was positive. The patient presented normal calcium and blood count, and peripheral blood immunophenotyping by flow cytometry without anomalous cells.

Once transferred to our hematology center, the serology with Western Blot and PCR (polymerase chain reaction) were

* Corresponding author at: R. Maestro Otto Wey, 133 – Jardim Itatinga, São Paulo, SP, Brazil, CEP: 02636100.

E-mail address: abdomed@bol.com.br (M.A.d. Almeida).

<https://doi.org/10.1016/j.htct.2021.02.013>

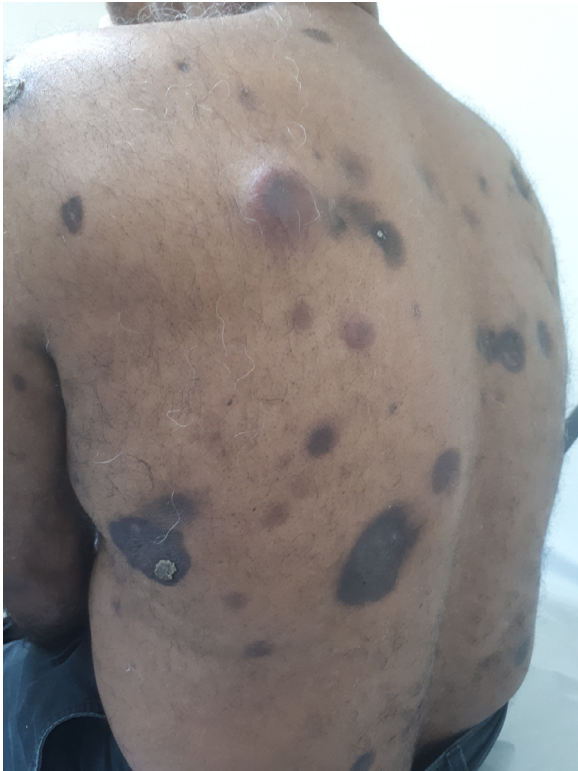

Figure 1 – Patient with tumoral and hyperchromatic cutaneous lesions, some with necrosis central and secretion.

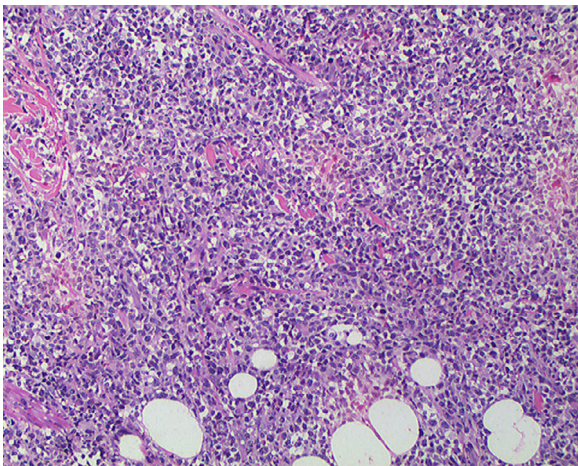


Figure 2 – Skin with diffuse interstitial infiltrate of lymphoid cells. HE:100x.

confirmed, and the patient already presented mild hypercalcemia and a considerable increased DHL, up to five times greater than normal. The microscopy analysis of peripheral blood and immunophenotyping by flow cytometry once again did not demonstrate abnormal cells; and bone marrow biopsy did not show lymphomatous infiltration. The PET CT showed a thickening uptake of the diffuse cutaneous and subcutaneous tissue, up to 4.8 cm, besides lytic lesions in the right scapula, costal arches, sacrum; and greater trochanter on the

right. It also demonstrated a ground-glass nodule in the right pulmonary middle lobe and lymph nodes that are only reactive in appearance.

Considering hypercalcemia described specially in the acute form, at first a treatment with zidovudine and interferon was prescribed, though resulting in the disease progression. Thus the treatment with the CHOEP regimen was administered.

Despite partial cutaneous improvements in the first cycle, the disease progressed in the subsequent cycles, especially with new cutaneous lesions and bone injuries worsening. The patient presented an important clinical decline, leading to death in December 2018, ten months after diagnosis.

Discussion

The ATL, according to Shimoyama's classification is divided into four clinical subtypes - lymphomatous, acute, chronic, and smoldering. However, this classification does not include a rare atypic variant recently described, such as cutaneous ATL.¹

According to Bittencourt et al., the primary cutaneous tumor form (PCT) would present only one difference concerning the non-leukemic smoldering subtype: the presence of nodules or tumors on the skin and a worse prognosis. Thus, in many studies, this tumor form is included in the smoldering subtype. The chronic subtype would be marked by lymphocytosis which remains stable for months or years; presenting an increase in LDH and an absence of hypercalcemia with possible moderate lymphadenomegaly; there is an unfavorable subtype which is defined by low levels of serum albumin and high levels of serum LDH and/or urea, presenting a similar prognosis to the aggressive forms. In the chronic subtype, there is no involvement of the central nervous system (CNS), bone, gastrointestinal tract (GIT), or pleural effusions. There may be skin lesions, mainly in the form of disseminated papules. The lymphomatous subtype is marked by lymphadenopathy without lymphocytosis and $\leq 1\%$ abnormal lymphocytes in the peripheral blood. There may be increased serum LDH and serum calcium as well as the involvement of the CNS, GIT, and bones. Histological proof of infiltration of T-cell lymphoma in the lymph nodes is required, associated with extranodal involvement or otherwise. Finally, the acute subtype presents high levels of lymphocytosis and atypical cells, including flower cells in the peripheral blood smear. Any organ may be involved. Pleural involvement occurs frequently and there may be a remarkable increase in serum LDH levels, in addition to lymphadenomegaly and skin involvement. It should be taken into consideration that this subtype may present different aspects including, less commonly, the absence of lymphocytosis and hypercalcemia. In the absence of lymphocytosis, the differential diagnosis against the lymphoma subtype depends on the presence of a high percentage of atypical lymphocytes in the peripheral blood.²

Tsukasaka et al. established criteria for extranodal variants of ATL. According to their study, a primary cutaneous lymphoma must be restricted to the skin at the time of diagnosis. Severity criteria were established within this subtype: if

multiple cutaneous lesions were present, the most severe type would be established. Within the types of lesion, the nodule/tumoral was considered the most severe.⁴

Bittencourt et al. compared 52 patients with serological diagnosis and histopathological evidence of cutaneous involvement. There was statistically significant difference between the mean survival time of patients with primary cutaneous tumoral ATL and those with a secondary impairment only, with the mean survival time of the second form being statistically shorter.⁵ Besides, a large difference in survival time was observed between the two primary types of cutaneous ATL, with the tumoral form being more aggressive than the indolent one, as it seems to have happened at the present casereport.

Given the difficulty of classifying new clinical variants, Cook et al. published a review based on discussions at the 18th International Conference on Human Retrovirology. According to this report, it was suggested that primary cutaneous ATL in its form (without leukemia or lymph node enlargement, which was before formerly allocated as ATL in the smoldering subtype), would be acknowledged as a lymphomatous form of ATL, an extranodal primary skin variant, described as skin lesions manifested by rapidly growing tumors, whose histology shows large and atypical cells, with a high proliferative index similar to the present case report, considered aggressive and suggested to immediate treatment. Still in that report, the need for intensive treatment was mentioned, including schemes which were in the present case report, though presenting no benefit.⁶ The present casereport seemed to be, at first, a primary cutaneous extranodal disease. However, the usage of new technologies, such as PET CT, provided more possibilities since the extensive and asymptomatic bone disease could be identified, which progressed despite the use of chemotherapy. Besides the rapid onset of hypercalcemia and greatly increased DHL before treatment, a proper classification ATL subtype is still doubtful, seeming to fit better among the lymphomatous forms.

Conclusion

The patient in the present case report presented at first only symptoms of cutaneous manifestation at diagnosis,

presenting later some altered laboratory parameters and bone lesions, leading to an ATL primary cutaneous classification, probably more adequate within the lymphomatous classification which includes secondary changes, even without any lymph node enlargement. The rapid evolution and low response to treatment lead to the need of a more precise approach concerning these new variants, aiming to a better therapeutic choice management. Thus, new subtype classifications have been proposed, in an attempt to include such cases providing more accessible new treatments.

Conflicts of interest

The authors declare no conflicts of interest.

REFERENCES

1. Bittencourt AL, Barbosa HS, Vieira MG, Alves CRB, Farré L. Adult T-cell leukemia/lymphoma (ATL) in Bahia, Brazil: analysis of prognostic factors in a group of 70 patients. *Am J Clin Pathol.* 2007;128:875–82.
2. Bittencourt AL, Farré L. Leucemia/linfoma de células T do adulto. *Na Bras Dermatol.* Rio de Janeiro. 2008;83(4):351–9.
3. Abe M, Uchihashi K, Kazuto T, Osaka A, Yanagihara K, Tsukasaki K, et al. Foxp3 expression on normal and leukemic CD4+CD25+ T cells implicated in human T-cell leukemia virus type-1 is inconsistent with Treg cells. *Eur J Haematol.* 2008;81(3):209–17.
4. Tsukasaki K, Imaizumi Y, Tokura Y, Ohshima K, Kawai K, Utsunomiya A, et al. Meeting report on the possible proposal of an extranodal primary cutaneous variant in the lymphoma type of adult T-cell leukemia/lymphoma. *J Dermatol.* 2014;41(1):26–8.
5. Bittencourt AL, Barbosa HS, Vieira MD, Farré L. Adult T-cell leukemia/lymphoma (ATL) presenting in the skin: clinical, histological and immunohistochemical features of 52 cases. *Acta Oncol.* 2009;48(4):598–604. <https://doi.org/10.1080/02841860802657235>. PMID:19165640.
6. Cook LB, Fuji S, Hermine O, Bazarbachi A, Ramos JC, Ratner L, et al. Revised Adult T-Cell Leukemia-Lymphoma International Consensus Meeting Report. *J Clin Oncol.* 2019;37(8):677–87.