

Prurigo pigmentosa following ketogenic diet and bariatric surgery: A growing association



Mohammed A. Alshaya, MBBS,^a Mohammed G. Turkmani, MD, FAAD,^b and Ahmed M. Alissa, MD, FRCPC^b
Riyadh, Saudi Arabia

Key words: Prurigo pigmentosa; keto(genic) diet; ketosis.

BACKGROUND

Prurigo pigmentosa (PP) is an uncommon inflammatory skin disorder. It is characterized by the development of erythematous urticated papules following a reticulate distribution. Although there is no clear cause for PP, multiple mechanical, inflammatory, and metabolic factors have been associated with the condition. One of these factors is the role of ketosis in inducing the eruption of PP. Histopathologic examination varies during the different stages of PP and includes perivascular neutrophilic infiltrate, parakeratosis, spongiosis, and dyskeratotic cells in the epidermis, with later stages featuring melanophages in the superficial dermis. We report 4 new cases of PP from Saudi Arabia: 3 were temporally associated with initiating ketogenic diet, and 1 patient had undergone bariatric surgery 1 month before the onset of PP. We also review the literature regarding the association of ketosis, diet, and PP.

CASE REPORT

Patient 1

A 26-year-old woman, who was otherwise healthy, presented with itchy skin lesions that started 3 months after adhering to a ketogenic diet. Her weight at the initial visit was 82 kg. A skin examination found erythematous papules coalescing to form plaques arranged in a reticulated configuration involving the chest, with intermammary and submammary involvement, and the upper back (Fig 1). A skin biopsy found an acanthotic epidermis with parakeratosis and few dyskeratotic cells overlying a mild/focal vacuolar interface change at the dermoepidermal junction (Fig 2). The dermis showed a superficial and mid-dermal perivascular lymphocytic infiltrate with few

Abbreviation used:

PP: prurigo pigmentosa

eosinophils. The overall clinical and histologic findings were consistent with PP.

Patient 2

A 20-year-old healthy man developed a rash 2 months after starting the ketogenic diet. His weight was 78 kg, and upon examinations the patient had bilateral erythematous papules and plaques on the sides of the neck (Fig 3). Based on the results of skin biopsy and clinical presentation, the findings were in keeping with a diagnosis of PP.

Patient 3

A 22-year-old woman presented with a history of skin lesions appearing on the chest and neck. She started the ketogenic diet 4 months prior. Her weight was 84 kg at presentation, and a physical examination found grouped erythematous papules coalescing into plaques, mainly on the intermammary area with less involvement of the neck (Fig 4). The patient refused a skin biopsy for cosmetic concerns, and a diagnosis of PP was made based on clinical grounds owing to the typical presentation of the eruption.

Patient 4

A 24-year-old woman had itchy skin eruption 5 weeks after bariatric surgery. She weighed 79 kg, and clinical examination found scattered erythematous papules on the sides of the face, shoulders, and chest (Fig 5). The patient refused biopsy, but similar to the previous patient, a diagnosis of PP was based

From the Dermatology Department, Prince Sultan Military Medical City^a and Derma Clinic.^b

Funding sources: None.

Conflicts of interest: None disclosed.

Correspondence to: Mohammed G. Turkmani, MD, FAAD, Dermatology Consultant Derma Clinic, PO Box 20632 Riyadh 11465, Saudi Arabia. E-mail: mgtderma@yahoo.com.

JAAD Case Reports 2019;5:504-7.
2352-5126

© 2019 by the American Academy of Dermatology, Inc. Published by Elsevier, Inc. This is an open access article under the CC BY-NC-ND license (<http://creativecommons.org/licenses/by-nc-nd/4.0/>).

<https://doi.org/10.1016/j.jidcr.2019.03.011>

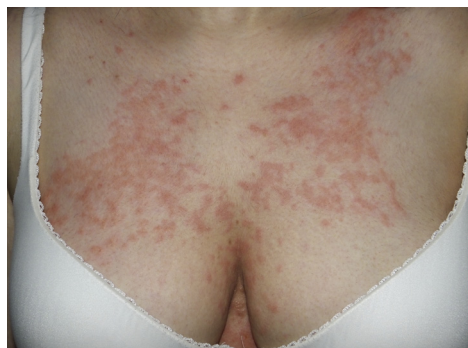

Fig 1. PP: clinical presentation of patient 1. Reticulated erythematous papules and plaques on the chest.

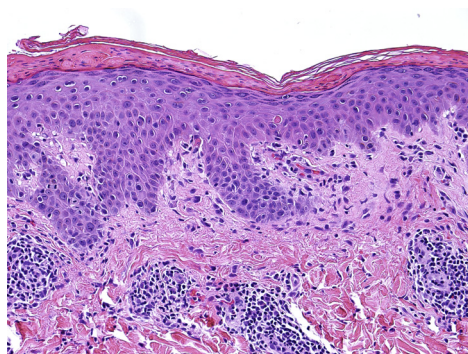


Fig 2. PP: histopathologic examination of skin lesions of patient 1. Parakeratosis, acanthosis, few dyskeratotic cells, mild vacuolar change at the dermoepidermal junction, and superficial perivascular lymphocytic infiltrate.

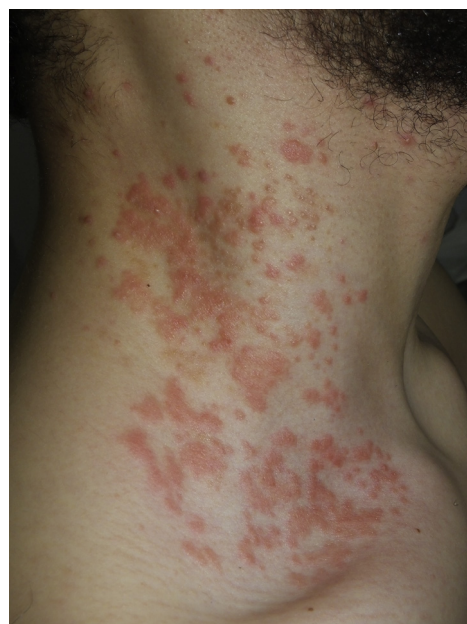

Fig 3. PP: clinical presentation of patient 2. Erythematous papules and plaques on the neck.

on the clinical presentation that was reinforced with the patient's response to treatment.

All patients were treated with 100 mg/d of doxycycline for 4 weeks, and the ketogenic diet was discontinued for the 3 patients who were on it prior to the presentation. A clinical response was noted as early as 2 weeks from the initiation of treatment, which resolved with residual post inflammatory hyperpigmentation. There was no recurrence of PP at the 2-month follow-up. At 1-year follow up, patient 2 had a recurrence of PP that was in association with resuming the ketogenic diet (Fig 6). This patient also reported recent initiation of metformin, as he was found to be prediabetic.

DISCUSSION

The first report of PP was in 1971 by Nagashima et al.¹ It disproportionately affects females in comparison to males, with a ratio of 2:1.² The eruption of PP is characterized by erythematous pruritic coalescing of papules arranged in a reticulate configuration that is transient and later resolves with postinflammatory hyperpigmentation.³ Variations of the typical

morphology of PP include pustular, bullous, and urticarial forms.² Although most cases have been described initially in Japan, there is an increase in reporting of PP worldwide, which is hypothesized to be related to the increase in awareness of the condition.³ Histopathologic features of PP depend on the stage at which the lesions are biopsied. They typically show a perivascular neutrophilic infiltrate in the early stages, which later evolve to feature necrotic keratinocytes and spongiosis of the epidermis. They ultimately lead to the presence of melanophages and lymphocytic infiltrate of the superficial dermis.⁴

The exact cause of PP remains unknown. However, reports of the condition developing after certain exposures along with the nature of the disease's behavior has led many investigators to hypothesize explanations to the appearance of such eruptions. Some examples include sweating,^{1,2} clothing friction, rubbing,³ contact dermatitis, and conditions like atopy and pregnancy.⁵ The metabolic associations with PP include diabetes mellitus,⁶ fasting,³ ketonemia,⁷ and dieting.^{7,8}

A ketogenic diet consists of reducing the carbohydrate content in the diet (usually to less than 50 g/d) while increasing the fraction of fat and protein intake. There is resurgence in the interest to adopt this diet regimen because of the growing reports of its beneficial effect in areas like weight control, diabetes, and cardiovascular disease among others.⁹

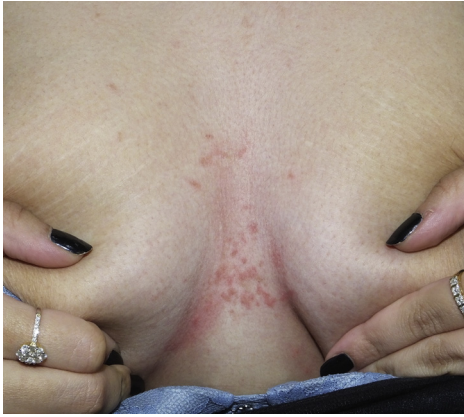

Fig 4. PP: clinical presentation of patient 3. Blanching erythematous papules involving the intermammary area.

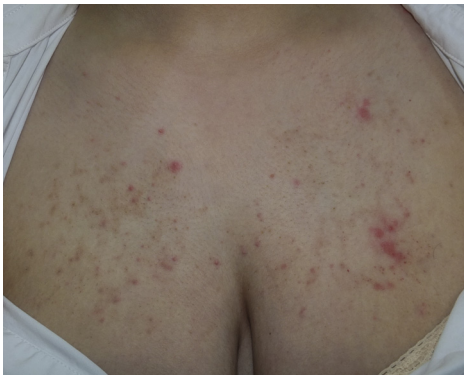

Fig 5. PP: clinical presentation of patient 4. Scattered erythematous papules on a background of hyperpigmented reticulated patches on the chest.

Ketosis has frequently been linked to PP development in various reports.^{2,3,10} One of the earliest to note correlation was Teraki et al.⁷ They reported 10 cases, of which, 8 were found to have ketosis by laboratory findings precipitated by either dieting, loss of appetite, or insulin-dependent diabetes mellitus.⁷ Other conditions that have been reported to lead to ketosis included obesity,¹¹ bariatric surgery,¹² and hyperemesis gravidarum of pregnancy.⁵ It is important to consider PP, as its initial presentation may not be a straightforward diagnosis. For instance, a report of a patient that was initially thought to have an urticarial eruption later had PP diagnosed, caused by ketosis secondary to anorexia nervosa.¹³ Previous reports have also supported the association between anorexia nervosa and PP.⁸ There are frequent reports of ketosis secondary to diabetes mellitus.⁶ Similarly, and of interest to our case, diet is also linked to the development of PP caused by ketosis.^{2,7,8,14,15} In a recent report by Almaani et al,¹⁵ PP development in 2 of 3 Jordanian patients was linked to fasting during the month of Ramadan, whereas the other case was a

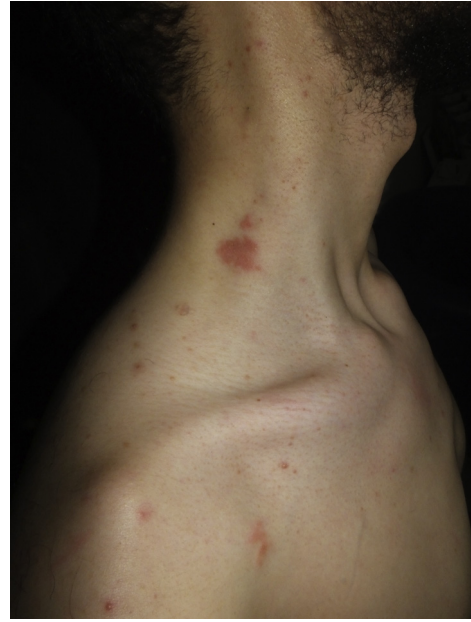

Fig 6. PP: recurrence of PP after resuming ketogenic diet in patient 2. Few erythematous plaques with scattered red papules on the side of the neck and upper chest. These lesions have recurred after resuming ketogenic diet after a period of clearance from the previous eruption.

result of strict dieting.¹⁵ Although these reports support an association between ketosis and the onset of PP, it is still not considered an established causative factor for the disease.² It has been hypothesized that ketone bodies play a role in inducing perivascular inflammation, mainly through neutrophils, thus explaining the positive response to medications suppressing neutrophilic-mediated processes like dapsone and tetracyclines.¹² Another mechanism that has been hypothesized is the direct alteration of intracellular processes owing to their entry into cells.¹²

Treatment of PP classically consists of oral antibiotics, including minocycline,² dapsone,^{2,11} and doxycycline.¹⁴ Typically, the treatment is successful, but hyperpigmentation may persist beyond the acute eruption.⁴ One consideration when treating patients with history of dieting prior to PP development is to reinstitute a balanced diet as an adjunct to medical therapies, as it was found to help in the treatment of the disease.²

We report on 3 patients who were on a ketogenic diet and 1 patient who had bariatric surgery, all of whom had PP a few months after the precipitating factor was initiated/performed. All patients were treated with doxycycline along with discontinuation of the ketogenic diet, which was associated with resolution of PP. It is prudent for the dermatologist to consider PP in the assessment and evaluation of

patients with risk factors for ketosis development, including those on diet or other metabolic disorders. Particularly, PP should be considered in patients on a ketogenic diet who have cutaneous eruptions, especially with the growing interest in adopting such dietary regimens.

The authors would like to acknowledge Amr Turkmani for his assistance in the data compilation and analysis process and for his time spent in editing this respective article.

REFERENCES

1. Nagashima M. A peculiar pruriginous dermatosis with gross reticular pigmentation. *Jpn J Dermatol.* 1971;81:38-39.
2. Boer A, Misago N, Wolter M, Kiryu H, Wang XD, Ackerman AB. Prurigo pigmentosa: a distinctive inflammatory disease of the skin. *Am J Dermatopathol.* 2003;25(2):117-129.
3. Oh YJ, Lee MH. Prurigo pigmentosa: a clinicopathologic study of 16 cases. *J Eur Acad Dermatol Venereol.* 2012;26(9):1149-1153.
4. Beutler BD, Cohen PR, Lee RA. Prurigo pigmentosa: literature review. *Am J Clin Dermatol.* 2015;16(6):533-543.
5. Hanami Y, Yamamoto T. Bullous prurigo pigmentosa in a pregnant woman with hyperemesis gravidarum. *J Dermatol.* 2015;42(4):436-437.
6. Kobayashi T, Kawada A, Hiruma M, Ishibashi A, Aoki A. Prurigo pigmentosa, ketonemia and diabetes mellitus. *Dermatology.* 1996;192(1):78-80.
7. Teraki Y, Teraki E, Kawashima M, Nagashima M, Shiohara T. Ketosis is involved in the origin of prurigo pigmentosa. *J Am Acad Dermatol.* 1996;34(3):509-511.
8. Nakada T, Sueki H, Iijima M. Prurigo pigmentosa (Nagashima) associated with anorexia nervosa. *Clin Exp Dermatol.* 1998; 23(1):25-27.
9. Paoli A, Rubini A, Volek J, Grimaldi K. Beyond weight loss: a review of the therapeutic uses of very-low-carbohydrate (ketogenic) diets. *Eur J Clin Nutr.* 2013;67(8):789.
10. Michaels JD, Hoss E, DiCaudo DJ, Price H. Prurigo pigmentosa after a strict ketogenic diet. *Pediatr Dermatol.* 2015;32(2):248-251.
11. Schepis C, Siragusa M, Palazzo R, Cavallari V. Prurigo pigmentosa: a misdiagnosed dermatitis in Sicily. *Cutis.* 1999;63(2): 99-102.
12. Abbass M, Abiad F, Abbas O. Prurigo Pigmentosa After Bariatric Surgery. *JAMA Dermatol.* 2015;151(7):796-797.
13. Capucilli P, Wan J, Corry J, Chuang JH, Linn RL, Perman MJ. Prurigo pigmentosa: an itchy, urticarial eruption confused for food Allergy. *J Allergy Clin Immunol Pract.* 2018;6(4):1381-1382.
14. Jonak C, Riedl E. An itchy rash in a young Caucasian woman. *Dermatol Pract Concept.* 2012;2(3).
15. Almaani N, Al-Tarawneh A, Msallam H. Prurigo pigmentosa: a clinicopathological report of three Middle Eastern patients. *Case Rep Dermatol Med.* 2018;2018.