

## CASE REPORT

# SVC obstruction and stridor relieved by nasogastric tube insertion

Emma J. Molena<sup>1,\*</sup>, Ashwin Krishnamoorthy<sup>2</sup>, and Coimbatore Praveen<sup>1</sup><sup>1</sup>Frimley Park Hospital, Surrey GU16 7UJ, UK and <sup>2</sup>King's College Hospital, London SE5 9RS, UK

\*Correspondence address: Tel: +01276 604604; Fax: +01276 604856; E-mail: emma.molena@doctors.org.uk

## Abstract

Achalasia is an idiopathic motility disorder of the oesophagus of increasing incidence. It is characterized by aperistalsis of the lower oesophagus and failure of relaxation of the lower oesophageal sphincter. Patients classically present with chronic symptoms of dysphagia, chest pain, weight loss and regurgitation, and they commonly suffer pulmonary complications such as recurrent microaspiration of static, retained food contents of the upper oesophagus. However, it has also been described, uncommonly, to present with megaesophagus and secondary tracheal compression. We present a case of megaesophagus secondary to achalasia which presented with stridor and signs of acute superior vena caval obstruction.

## INTRODUCTION

Achalasia is a motility disorder of the oesophagus. It has rarely been described to cause megaesophagus, the exact pathophysiology of which is not known for certain. In cases of megaesophagus, the enlarged oesophagus causes tracheal compression and respiratory distress. It has also previously been described in one case to cause thoracic inlet compression with engorged neck veins and bilateral neck swelling [1]. The key to management is recognition and urgent decompression of the oesophagus with nasogastric tube.

## CASE REPORT

An 81-year-old woman with a background of asthma, ischaemic heart disease and achalasia presented to hospital with a 2-h history of worsening shortness of breath. On examination, she was in visible respiratory distress and was tachypnoeic at 24 breaths per minute, with oxygen saturations of 93% on room air. Examination of the chest revealed diffuse bilateral wheeze. She was tachycardic at 130 beats per minute and hypotensive. There was no specific trigger apart from the patient eating her

lunchtime meal. She was also noted to have noisy inspiratory stridor. Furthermore, she had bilateral neck swelling which moved with expiration, and her neck veins were visibly distended. High-flow oxygen was administered, and an arterial blood gas revealed a respiratory acidosis with pH 7.19, pO<sub>2</sub> 15.7 (on 15 l of oxygen), PCO<sub>2</sub> 8.6 and a lactate of 2.9. A provisional differential diagnosis of infective exacerbation of asthma was made with stridor of unknown cause. She was given intravenous fluids and nebulized steroids, intravenous steroid and nebulized adrenaline.

A plain chest radiograph was taken demonstrating a massively dilated air and fluid-filled oesophagus, with no visible intraparenchymal lung abnormality. A 16-French gauge nasogastric tube was immediately placed into the oesophagus with aspiration of air, fluid and food debris. This resulted in almost immediate relief of the patient's respiratory distress, and she clinically improved.

After decompression of the oesophagus, a computed tomography (CT) scan of the chest confirmed the diagnosis of megaesophagus causing tracheal compression. The patient, now stabilized, was referred for oesophago-gastro-duodenoscopy (OGD) with a view to Botulinum toxin treatment for underlying achalasia (Figures 1–3).

Received: December 21, 2015. Accepted: January 19, 2016

Published by Oxford University Press and JSCR Publishing Ltd. All rights reserved. © The Author 2016.

This is an Open Access article distributed under the terms of the Creative Commons Attribution Non-Commercial License (<http://creativecommons.org/licenses/by-nc/4.0/>), which permits non-commercial re-use, distribution, and reproduction in any medium, provided the original work is properly cited. For commercial re-use, please contact [journals.permissions@oup.com](mailto:journals.permissions@oup.com)

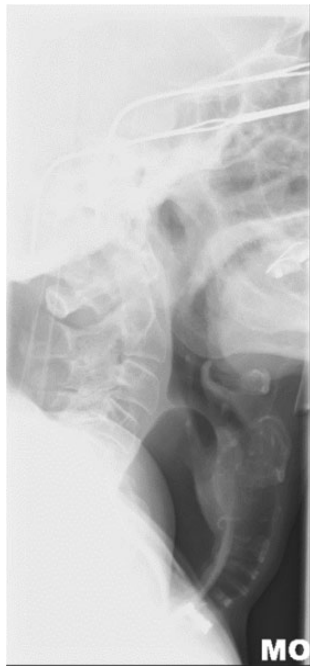

Figure 1: Lateral neck X-ray showing dilated oesophagus displacing trachea anteriorly.

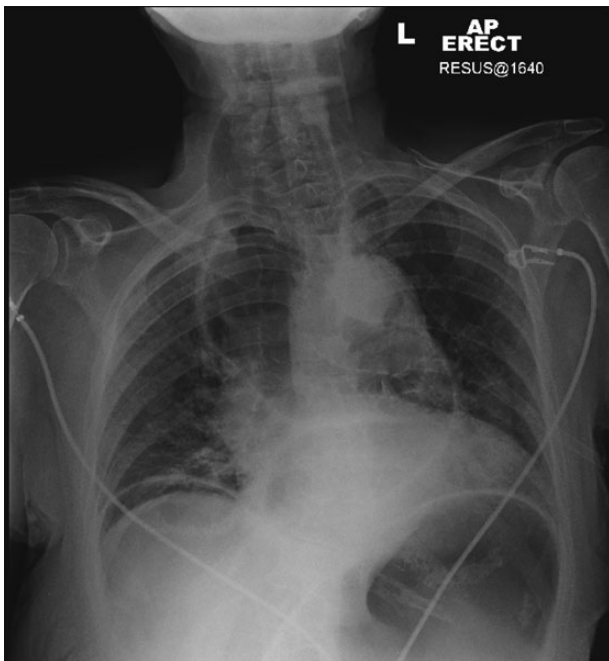


Figure 2: Chest X-ray: megaesophagus behind trachea.

## DISCUSSION

Over 50 years ago, the first instance of achalasia presenting in such fashion was first described [1], and since then, it has been sporadically reported in the literature. These cases have often had similar presentations, typically an elderly woman presenting with sudden onset of respiratory distress, stridor after a meal;

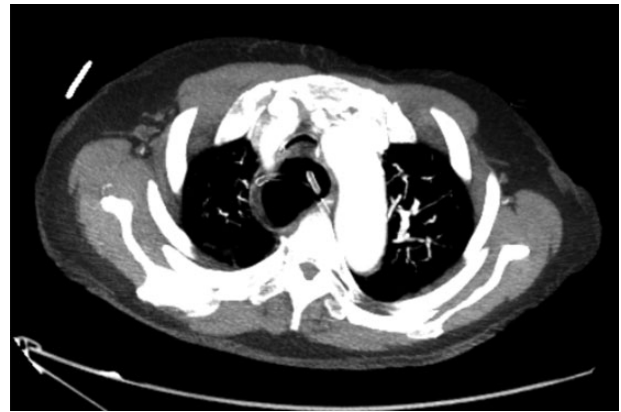

Figure 3: Axial slice of CT chest after nasogastric decompression showing persistent megaesophagus and airway narrowing.

with quick relief of symptoms after oesophageal decompression by a nasogastric tube [2–10].

Different hypotheses for the pathophysiology of this presentation have been postulated.

Firstly, it is proposed that the dilated oesophagus is cephalically displaced against the cricopharyngeus muscle resulting in a ‘pinch-cock’, one-way valve system allowing air to enter the thoracic oesophagus but not to escape.

Secondly, results of pharyngeal and upper oesophageal sphincter (UOS) manometry have shown repetitive UOS contractions, increased residual UOS pressure and failure of relaxation of the UOS. It is postulated that acute fierce UOS contraction could lead to a one-way valve system resulting in air trapped in a dilated oesophagus as above.

In both instances, the normal belch reflex is lost and the enlarged oesophagus compresses the trachea retrosternally causing airway compromise. A case described in 1976 by McLean *et al.* reports similar engorged neck veins, facial swelling and bilateral neck swelling indicative of thoracic inlet obstruction [1]. This high intrathoracic pressure results in reduced venous return to the heart and, by Starling’s law, reduced cardiac output and hence a haemodynamically unstable patient.

Regardless of the pathophysiology, we advocate that the emergency management should remain the same—achievement of urgent oesophageal decompression. The most effective way to achieve this is insertion of a large-bore nasogastric tube, coupled with suctioning of the upper respiratory tract. Other methods including needle aspiration of the oesophagus, bougienage and oesophagoscopy with catheter insertion have also been described.

In conclusion, doctors must be aware of this rare but potentially fatal acute complication of achalasia as, if managed correctly, a severely ill patient can be quickly and effectively stabilized before referral for definitive management.

## CONFLICT OF INTEREST STATEMENT

None declared.

## REFERENCES

1. McLean RDW, Stewart CJ, Whyte DGC. Acute thoracic inlet obstruction in achalasia of the esophagus. *Thorax* 1976;31:456–9.

2. O'Neill OM, Johnston BT, Coleman HG. Achalasia: a review of clinical diagnosis, epidemiology, treatment and outcomes. *World J Gastroenterol* 2013;**19**:5806–12.
3. Eckardt AJ, Eckardt VF. Current clinical approach to achalasia. *World J Gastroenterol* 2009;**15**:3969–75.
4. Bruijns SR, Hicks A. Achalasia—an unusual cause of airway obstruction. *Emerg Med J* 2009;**26**:148.
5. Thomas JD, Monaghan TM, Latief K. Megaesophagus; an unusual cause of stridor. *Q J Medicine* 2010;**103**:53–4.
6. Ho V, Whiting P. Acute airway obstruction secondary to achalasia mega-oesophagus. *Anaesth Intensive Care* 2008;**36**:582–4.
7. Miyamoto S, Konda Y, Matsui M, Sawada K, Ikeda K, Watanabe N, et al. Acute airway obstruction in a patient with achalasia. *Intern Med* 2011;**50**:2333–6.
8. Khan AA, Shah SW, Alam A, Butt AK, Shafqat E, Malik K, et al. Achalasia esophagus; presenting as acute air way obstruction. *J Pak Med Assoc* 2007;**57**:423–5.
9. Wechalekar MD, Southcott AM. Achalasia cardia presenting as stridor. *Respirology* 2008;**13**:1088–90.
10. Bello CT, Lewin JR, Norris CM, Farrar GE Jr. Achalasia (cardiospasm); report of a case with extreme and unusual manifestations. *Ann Intern Med* 1950;**32**:1184.