



# Percutaneous debridement and washout of walled-off abdominal abscess and necrosis by the use of flexible endoscopy: an attractive clinical option when transluminal approaches are unsafe or not possible

Matthew T. Moyer, MD, MS,<sup>1</sup> Leonard T. Walsh, MD,<sup>2</sup> Carl E. Manzo, MD,<sup>3</sup> Justin Loloi, BS,<sup>4</sup> Allene Burdette, MD,<sup>5</sup> Abraham Mathew, MD, MSc<sup>6</sup>

**Background and Aims:** Walled-off pancreatic necrosis is a well-known serious adverse event of severe acute pancreatitis. EUS-guided transluminal access followed by direct endoscopic necrosectomy is increasingly used to remove necrosis, with good efficacy and a superior safety profile when compared with surgery. However, a percentage of patients is too critically ill to undergo this procedure or lack an appropriate transluminal window for access. Here we describe the use of percutaneous flexible endoscopic necrosectomy (PEN) with use of standard-sized upper endoscopes and accessories in a retrospective single-institution experience with a video demonstration of 1 patient in the series.

**Methods:** The authors present a 23-patient retrospective case series of PEN with standard-sized endoscopes. The series includes 12 patients from a previously published analysis in 2016 and 11 additional patients from 2013 to 2018. A representative case illustrates the described technique in a patient with severe acute pancreatitis complicated by multisystem organ failure who required immediate drainage of a pancreatic fluid collection and placement of a percutaneous drain into the collection for decompression. The drain was serially upsized to 28F, and its tract was used for PEN.

**Results:** A total of 23 patients have undergone PEN at our institution. On average, the size of the pancreatic fluid collection was 11.6 cm in cross-sectional diameter. Of those 23 patients, 11 presented with symptoms of severe disease. The median time from onset of symptoms to PEN was 84 days. The median number of procedures per patient was 2.1. The median time to complete resolution of symptoms and fluid collections was 67 days. In total, resolution was reached in 22 of 23 patients. Two patients died of unrelated causes.

**Conclusion:** PEN is a minimally invasive and effective treatment approach to walled-off pancreatic necrosis in patients who are not amenable to transluminal drainage and in whom percutaneous drains have been successfully placed. This case series demonstrates the efficacy and safety of this approach. A randomized prospective trial would be warranted to validate these results. (VideoGIE 2019;4:389-93.)

## INTRODUCTION

Walled-off pancreatic necrosis (WOPN) is a well-known serious adverse event of severe acute pancreatitis. In many referral centers, EUS-guided transluminal drainage followed by direct endoscopic necrosectomy is increasingly used to remove the necrosis, with good clinical efficacy and a superior safety profile when compared with surgery (mortality rate of 2%-6% vs up to 50%, respectively).<sup>1</sup> However, a percentage of patients is too critically ill to undergo the deep sedation or general anesthesia that is required for this procedure, and others lack an appropriate transluminal window for access, with both situations typically resulting in percutaneous

drainage by radiology. Percutaneous drainage typically provides immediate relief with regard to decompressing the fluid aspect of the collection and stabilizing the patient's condition; however, percutaneous catheters rarely result in adequate removal of significant necrosis.

Direct percutaneous flexible endoscopic necrosectomy (PEN) through the established tract with both small and standard-sized endoscopes with CRE™ balloon dilation of the tract has been described, but with limited success. We demonstrate the safety and utility of serial percutaneous drain upsizing to 28F (typically 2-4 exchanges over 2-3 weeks) that allow the use of a standard 8.8-mm upper video endoscope with a 2.8-mm working channel and standard-sized accessories (such as a snare) for mechanical

**TABLE 1. Summary of cases**

Sex	Age	Etiology of necrosis	Size of necrosis (cm)	Severity/adverse events	Days from symptoms to first intervention
M	63	Pancreatic	10.5 x 3.7 cm	None	99
M	46	Hepatic	11.9 x 9.7 cm, 12.7 x 6.4 cm	Sepsis	21
F	51	Pancreatic	23.8 x 15.5 cm	Sepsis	61
F	34	Pancreatic	21.2 x 14.9 cm, 13.5 x 7.6 cm, 12.3 x 5.5 cm	Multiorgan failure, sepsis	68
F	65	Pancreatic	14.7 x 3.8 cm	Multiorgan failure, sepsis	87
F	73	Omental	9.8 x 3.5 cm	None	86
F	45	Pancreatic	14.1 x 12.9 cm	None	79
F	26	Pancreatic	6.4 x 2.5 cm	None	248
F	53	Pancreatic	11.6 x 5.2 cm	None	124
M	41	Pancreatic	7.0 x 3.2 cm	Sepsis	53
F	61	Pancreatic	12.4 x 2.5 cm	None	159
F	54	Pancreatic	10.6 x 9.6 cm	Sepsis	84
M	60	Pancreatic	11.7 cm x 2.2 cm	None	77
M	55	Pancreatic	15.7 x 9.2 cm	Multiorgan failure, sepsis	74
F	65	Hepatic	11.4 x 9.3 x 10.3 cm	Persistent leukocytosis	122
M	42	Pancreas	9 x 5 x 11 cm	None	95
M	31	Pancreas	6.0 x 7.8 cm	None	68
M	31	Pancreas	16.4 x 5.7 cm	Sepsis	73
F	36	Pancreas	22 x 10 x 5 cm	Sepsis	185
M	51	Pancreas	22 x 11 cm	None	121
F	85	Pancreas	10.8 x 5.1 cm	Tenuous resp status	42
M	79	Omental/post-surg bed	10 x 5.5 cm	None	224
M	37	Pancreas	10 cm x 6.2 cm	None	60

debridement through the established tract. After a clean cavity is achieved, a smaller, more compliant drain is replaced by the endoscopist under fluoroscopy, which is left to gravity drainage until follow-up clinic evaluation with repeated cross-sectional imaging.

The authors propose that this minimally invasive approach offers a safe and effective treatment modality for WOPN and other intra-abdominal fluid collections in appropriately selected patients. Here we review a 23-patient retrospective case series from our institution (Table 1). The video (Video 1, available online at [www.VideoGIE.org](http://www.VideoGIE.org)) highlights 1 patient in the case series.

## PATIENT CASE

A 55-year-old man with a significant cardiac history presented to the emergency department with severe acute pancreatitis and systemic inflammatory response syndrome. He further decompensated, and his case was complicated by acute respiratory distress syndrome, septic shock, and a non-ST-segment elevation myocardial infarction. He was intubated, given vasopressors, and transferred to the intensive care unit. CT showed pancreatic inflamma-

tion and colonic wall pneumatosis; he therefore required an urgent exploratory laparotomy and left hemicolectomy. The patient remained in critically ill condition for the following 3 weeks, and CT imaging showed progression of a peripancreatic fluid collection (Fig. 1). On hospital day 27, because of worsening fevers, tachycardia, tachypnea, and abdominal pain, it was thought that the WOPN was likely infected and treatment was indicated.

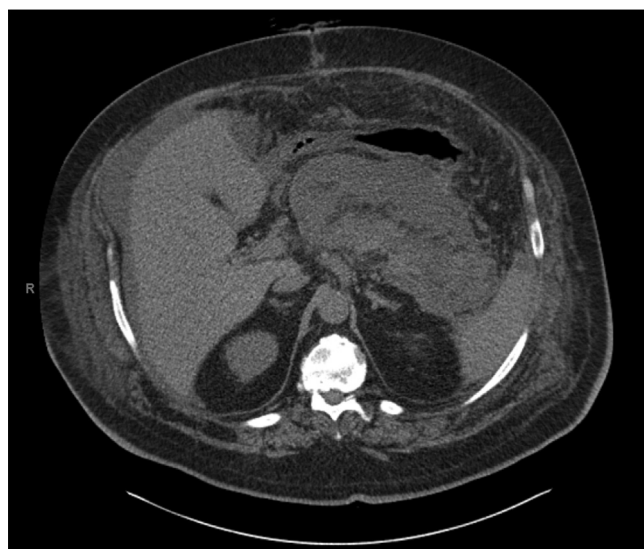The patient's condition was not stable enough to permit endoscopy with deep sedation, and the fluid collection did not appear mature enough for transgastric access and debridement. Consequently, after a multidisciplinary discussion, an interventional radiologist placed a percutaneous drain into the peripancreatic collection, and we planned for serial catheter upsizing for eventual PEN after stabilization. The patient was discharged at week 4 and underwent serial upsizing as an outpatient, concluding with a 28F catheter (Thal-Quick Abscess Drainage Set, Cook Medical, Bloomington, IN, USA).

He was seen for follow-up in clinic 4 weeks after hospital discharge and was found to be febrile, tachycardic, and tachypneic. He was directly admitted to the hospital and underwent PEN the following day.

TABLE 1. Continued

Number of PEN	Number of percutaneous drains	Time to resolution (all drains removed) (days)	Postprocedure adverse events	1-year sustained resolution
2	1	57	Fistula	Yes
4	3	74	None	Yes
2	1	171	None	Yes
5	3	123	None	Yes
4	2	n/a	None (death 3 months after procedure)	n/a
1	1	31	None	Yes
1	1	10	None	Yes
1	1	19	None	Yes
1	1	57	None	Yes
1	1	59	None	Yes
1	1	210	Fistula	Yes
5	2	40	None	n/a
1	1	27	None	Yes
3	1	89	None	Yes
1	1	n/a	None (death 1 month after procedure)	n/a
1	1	203	Fistula/pancreatic duct leak	Yes
2	2	140	PD leak	Yes
1	1	184	PD leak	Yes, but persistent pseudocyst
1	2	100	None	Yes, persistent fluid
2	1	35	None	Yes
1	1	53	PD leak	Yes
2	1	Drains remain	None	n/a
6	2	116	None	Yes

The 28F percutaneous drainage catheter was removed, and a standard 8.8-mm upper flexible endoscope with a 2.8-mm working channel was introduced through the established tract (Fig. 2) into the necrotic cavity. The cavity was



**Figure 1.** Axial CT image showing progression of a peripancreatic fluid collection.

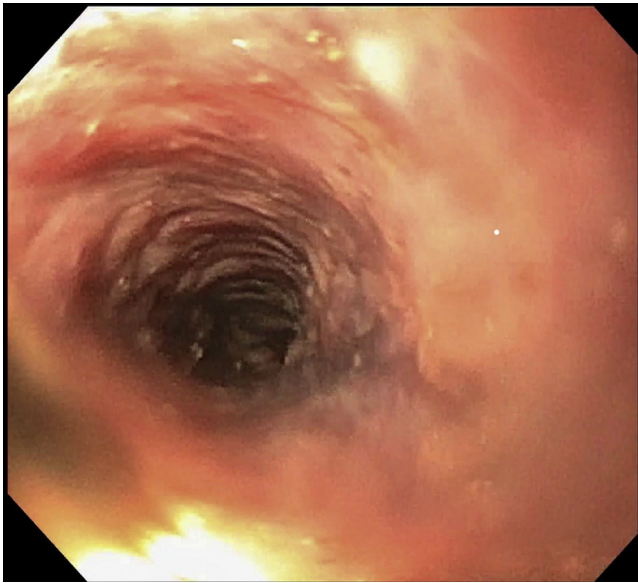
lavaged with normal saline, and necrotic debris was progressively removed with a 2-cm stiff polypectomy snare (Fig. 3). When all necrotic debris was removed, the cavity was lavaged with high-volume normal saline solution, and the 28F catheter was replaced. The patient was instructed to flush the drain with 20 to 50 mL of normal saline solution every 4 hours. A total of 3 procedures were performed, and upon completion of the third debridement and washout, no further necrosis was noted (Fig. 4). A smaller, more compliant, 14F pigtail drainage catheter (Skater All-Purpose Drainage Catheter, Argon Medical Devices, Frisco, Tex, USA) (Fig. 5) was placed until outpatient follow-up.

At 12 weeks after necrosectomy, the percutaneous drainage catheter was removed because the output was less than 20 mL per day for 3 days, and follow-up cross-sectional imaging showed complete resolution of the WOPN (Fig. 6). No recurrent fluid collections were noted.

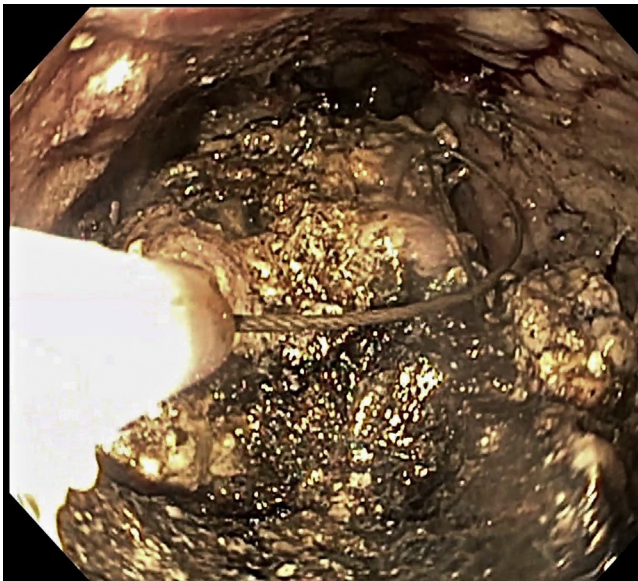
## CONCLUSION

PEN is a minimally invasive and effective treatment approach to WOPN in patients who are not amenable to trans-luminal drainage and in whom percutaneous drains have been successfully placed. A brief overview of the 23 patients



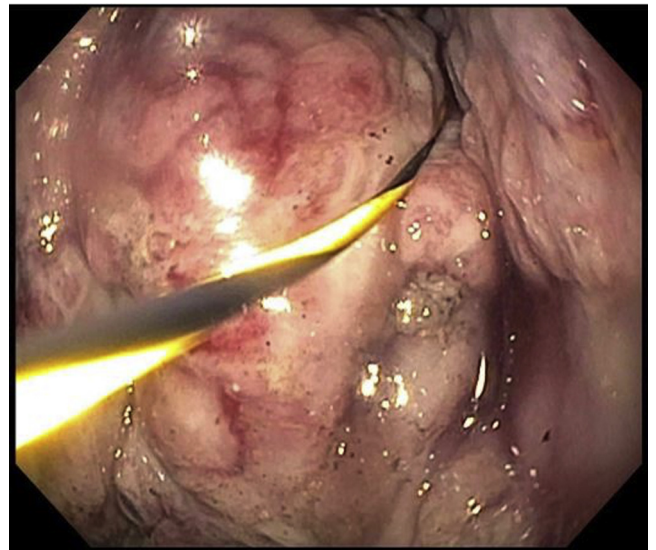


**Figure 2.** Endoscopic view of the percutaneous tract leading to the necrotic cavity.



**Figure 3.** Endoscopic view of the cavity showing necrotic debris being removed with a stiff polypectomy snare.

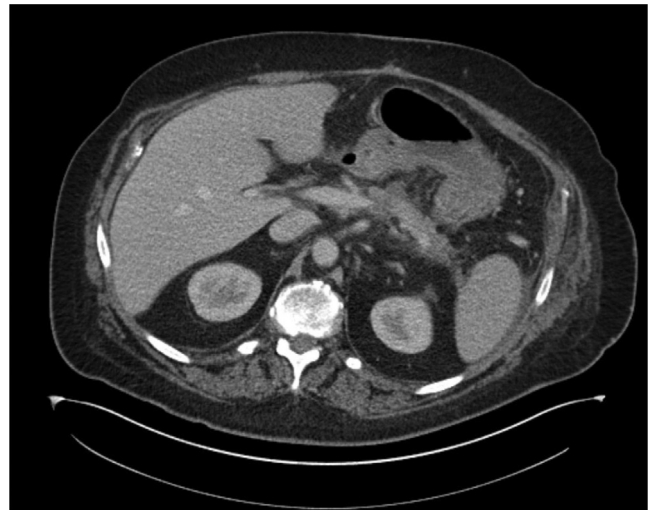treated with the PEN techniques described using standard-sized upper endoscopes and accessories at our institution is summarized in [Table 1](#). This approach demonstrates the effectiveness and safety of direct PEN in the treatment of intra-abdominal fluid collections and necrosis in appropriately selected patients. PEN appears to have equivalent efficacy and improved safety when compared with EUS-guided transluminal access, which carries a known serious adverse event rate to upward of 25% and a postoperative mortality rate of 2% to 6%.<sup>1-2</sup> More experience and more robust clinical trials will be required to confirm these results and further develop this approach.



**Figure 4.** Endoscopic view of the cavity and guidewire after completion of the third percutaneous flexible endoscopic necrosectomy with no further necrosis noted.



**Figure 5.** 14F Skater percutaneous drainage catheter placed by the endoscopist at the completion of the debridement and washout.



**Figure 6.** Coronal CT image 12 weeks after necrosectomy showing complete resolution of the walled-off pancreatic necrosis.

## DISCLOSURE

*Dr Moyer and Dr Mathew are consultants for Boston Scientific. All other authors disclosed no financial relationships relevant to this publication.*

Abbreviations: PEN, percutaneous flexible endoscopic necrosectomy; WOPN, walled-off pancreatic necrosis.

## REFERENCES

1. Bello B, Matthews J. Minimally invasive treatment of pancreatic necrosis. *World J Gastroenterol* 2012;18:6829-35.
2. Thompson CC, Kumar N, Slattery J, et al. A standardized method for endoscopic necrosectomy improves complication and mortality rates. *Pancreatol* 2015;16:66-72.

Division of Gastroenterology and Hepatology (1), Department of Internal Medicine (2), Division of Gastroenterology and Hepatology (3), Penn State

Health Milton S. Hershey Medical Center; Penn State Hershey College of Medicine (4), Division of Interventional Radiology (5), Division of Gastroenterology and Hepatology (6), Penn State Health Milton S. Hershey Medical Center, Hershey, Pennsylvania, USA.

Copyright © 2019 American Society for Gastrointestinal Endoscopy. Published by Elsevier Inc. This is an open access article under the CC BY-NC-ND license (<http://creativecommons.org/licenses/by-nc-nd/4.0/>).

<https://doi.org/10.1016/j.vgie.2019.04.005>

If you would like to chat with an author of this article, you may contact Dr Walsh at [lwalsh1@pennstatehealth.psu.edu](mailto:lwalsh1@pennstatehealth.psu.edu).

### Submit to *VideoGIE*

*VideoGIE* is now indexed in PubMed Central.

*VideoGIE* is an Open Access, online-only journal indexed in PubMed Central. Submit video cases of endoscopic procedures used in the study, diagnosis, and treatment of digestive diseases.

*VideoGIE* publishes the following article types:

- **Case Reports:** Reports of the diagnosis and management of digestive diseases using a single case.
- **Case Series:** Reports of the diagnosis and management of digestive diseases using 3 or more cases.
- **Tools and Techniques:** Educational videos demonstrating the use of a particular endoscopic tool or technique. The goal of this section is to help trainees, endoscopy nurses, and technicians learn how best to use the tools of endoscopy for high-quality care.

All manuscripts must be submitted online at <http://www.editorialmanager.com/vgie>