



# Reversible tactile hypoesthesia associated with myofascial trigger points: a pilot study on prevalence and clinical implications

Katsuyuki Moriwaki\*, Kazuhisa Shiroyama, Masako Yasuda, Fumihiko Uesugi

## Abstract

**Introduction:** Tactile hypoesthesia observed in patients with myofascial pain syndrome (MPS) is sometimes reversible when pain is relieved by trigger point injections (TPIs). We aimed to investigate the prevalence of such reversible hypoesthesia during TPI therapy and topographical relations between areas of tactile hypoesthesia and myofascial trigger points (MTrP) in patients with MPS.

**Methods:** Forty-six consecutive patients with MTrP were enrolled in this study. We closely observed changes in areas of tactile hypoesthesia in patients who had tactile hypoesthesia at the first visit, and throughout TPI therapy. Tactile stimulation was given using cotton swabs, and the areas of tactile hypoesthesia were delineated with an aqueous marker and recorded in photographs.

**Results:** A reduction in the size of hypoesthetic area with TPI was observed in 27 (58.7%) patients. All the 27 patients experienced a reduction in pain intensity by more than 50% in a numerical rating scale score through TPI therapy. In 9 patients, the reduction in the sizes of hypoesthetic areas occurred 10 minutes after TPI. Complete disappearance of tactile hypoesthesia after TPI therapy was observed in 6 of the 27 patients. Myofascial trigger points were located in the muscles in the vicinity of ipsilateral cutaneous dermatomes to which the hypoesthetic areas belonged.

**Conclusion:** Our results indicate a relatively high prevalence of reversible tactile hypoesthesia in patients with MPS. Mapping of tactile hypoesthetic areas seems clinically useful for detecting MTrP. In addition, treating MTrP with TPI may be important for distinguishing tactile hypoesthesia associated with MPS from that with neuropathic pain.

**Keywords:** Touch, Tactile sensory abnormalities, Muscle pain, Myofascial pain syndrome, Trigger point injection

## 1. Introduction

Several clinical studies have reported that tactile hypoesthesia can be observed in patients with myofascial pain<sup>2,9</sup> and myalgia.<sup>13,17</sup> Tactile hypoesthesia can also occur during experimentally induced muscular pain in healthy individuals.<sup>1,9,14,15,27</sup> We have noticed that some instances of tactile hypoesthesia are reversible when muscle pain is reduced by trigger point injections (TPI) in patients with persistent postmastectomy pain.<sup>20</sup> Such reversible tactile hypoesthesia has been reported to occur in painful areas for patients with

chronic pain,<sup>16,21–23</sup> and changes in size in parallel with intensity of pain.<sup>21,22</sup> However, the relation between such tactile hypoesthesia and muscle pain in patients with myofascial pain syndrome (MPS) has not been sufficiently studied, and its clinical significance is not well recognized. Previous prominent reviews on MPS<sup>5,10,11,24</sup> have not described tactile hypoesthesia as a significant clinical sign of the syndrome. The aims of this pilot study were to investigate prospectively the prevalence of such reversible tactile hypoesthesia for patients with MPS and the topographical relation between areas of tactile hypoesthesia and myofascial trigger points (MTrP).

Sponsorships or competing interests that may be relevant to content are disclosed at the end of this article.

Department of Anesthesiology, Critical Care and Pain Medicine, National Hospital Organization, Kure-Medical Center, Chugoku Cancer Center, Kure, Hiroshima, Japan

\*Corresponding author. Address: Department of Anesthesiology, Critical Care and Pain Medicine, National Hospital, Organization, Kure Medical Center and Chugoku Cancer Center, 3-1 Aoyama-cho, Kure, Hiroshima 737-0023, Japan. Tel.: +81-823-22-3111; fax: +81-823-21-0478. E-mail address: kmoriwaki1953@icloud.com (K. Moriwaki).

Copyright © 2019 The Author(s). Published by Wolters Kluwer Health, Inc. on behalf of The International Association for the Study of Pain. This is an open-access article distributed under the terms of the Creative Commons Attribution-Non Commercial-No Derivatives License 4.0 (CCBY-NC-ND), where it is permissible to download and share the work provided it is properly cited. The work cannot be changed in any way or used commercially without permission from the journal.

PR9 4 (2019) e772

<http://dx.doi.org/10.1097/PR9.0000000000000772>

## 2. Methods

### 2.1. Patients

With approval by our Institutional Review Board, 46 consecutive patients (19 males and 27 females, aged 27 to 88 years, median age of 66.5 years), who were referred to our pain clinic and having MTrP and myofascial pain, were enrolled in this study. Informed consent to participate was obtained from all patients.

### 2.2. Background tactile sensory abnormalities and study protocol

Types of tactile sensory abnormalities were examined at the first visit in all 46 patients (Table 1). Among them, 30 patients who had

**Table 1****Types of tactile sensory abnormalities observed at the first visit.**

Tactile sensory abnormalities	No. of patients	No. of patients who underwent TPI
Hypoesthesia alone	32	28
Allodynia surrounded by hypoesthesia	2	2
Allodynia alone	1	1
No sensory abnormalities	11	10

TPI, trigger point injection.

tactile hypoesthesia, and underwent TPI, were recruited for the observation study on the reversibility of tactile hypoesthesia. Pain intensity, pain etiology, number of TPI sessions, and duration of TPI therapy, as well as concomitant oral medications used to treat the pain, were studied. The areas of tactile hypoesthesia and allodynia (if existing), as well as degrees of pain intensity, were evaluated at every treatment visit (before TPI, **Fig. 1A**) as well as the last follow-up visit. Immediate changes in the areas of such sensory abnormalities and pain intensity were also evaluated at 10 minutes after TPI (**Fig. 1B**). The effects of TPI in one patient with allodynia alone and 10 patients who had no tactile sensory abnormalities were also studied.

### 2.3. Identification and evaluation of myofascial trigger points, tactile sensory abnormalities, and pain intensity

Myofascial trigger points were identified according to the diagnostic criteria of Simons et al.,<sup>25</sup> and marked with an "X" on the cutaneous surface using a red aqueous marker. Tactile stimulation was given using cotton swabs, and the areas of tactile hypoesthesia as well as allodynia (if existing) were delineated with

aqueous markers. Myofascial trigger points and the areas of tactile sensory abnormalities were recorded in photographs (**Fig. 1**). The degrees of tactile hypoesthesia and pain intensity were evaluated with a numerical rating scale (NRS). The NRS score of tactile hypoesthesia was defined from 0 (absence of touch sensation) to 10 (normal touch sensation).

### 2.4. Trigger point injection therapy

We treated myofascial pain once a week or every 2 weeks with TPI. Three to five milliliter of 1% lidocaine supplemented with or without 20 to 30 mg of triamcinolone was injected to MTrP using 26- or 25-G injection needles. Trigger point injection, if effective, was continued until adequate pain relief was obtained. Trigger point injection therapy was stopped when adequate progressive pain relief was not expected.

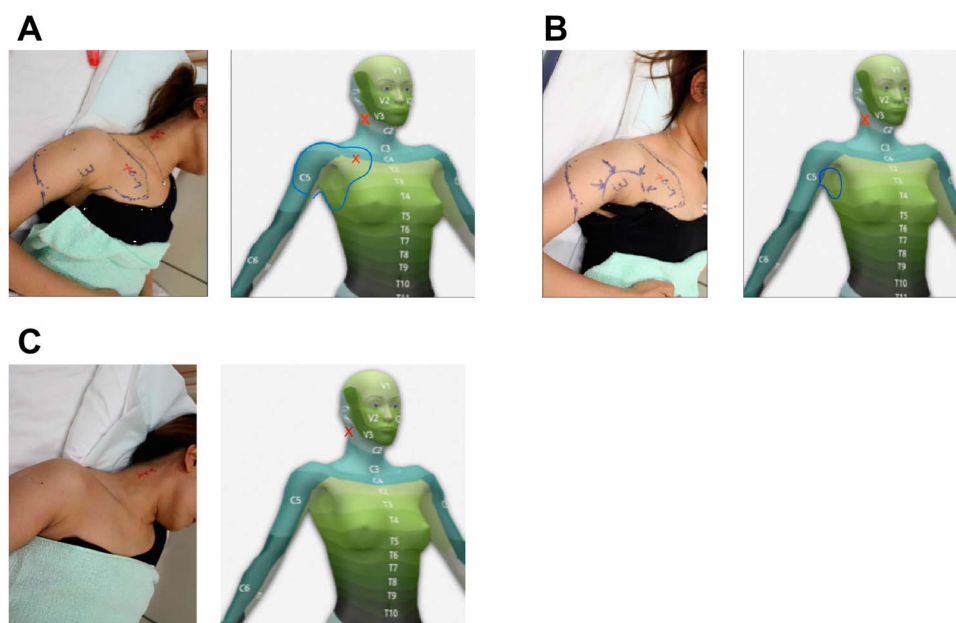
### 2.5. Analyses of stored data

Topographical relations between the areas of tactile hypoesthesia and sites of MTrP were studied by depicting the areas of hypoesthesia on a 3-D Dermatomes (Andreas Larsen and Tobias Due Munk, 2011, Mac App) from photographs as shown in **Figures 1 and 2**. The relation between categorical variables was tested using a  $\chi^2$  test (Yates' correction) with a significance level of 0.05.

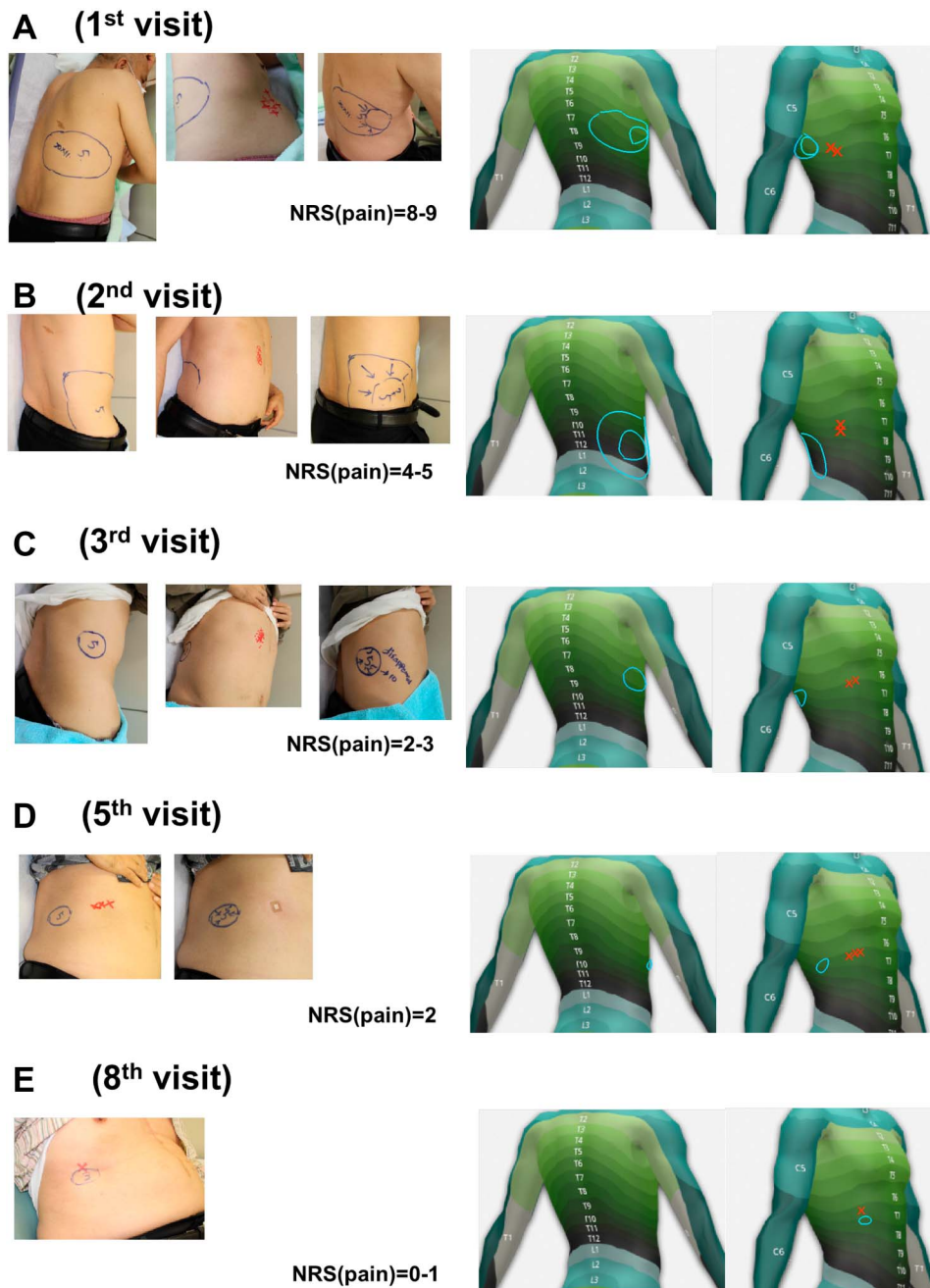
## 3. Results

### 3.1. Prevalence of tactile sensory abnormalities in patients with myofascial trigger points

Thirty-four (74%) of 46 patients with MTrP had tactile hypoesthesia (**Table 1**). Thirty-two patients had a tactile hypoesthetic



**Figure 1.** Identification of MTrP and delineation of tactile hypoesthesia areas. Tactile hypoesthesia and MTrP observed in a 41-year-old female patient at the first visit are shown in A and B. She was referred to our pain clinic due to head (occipital) and neck pain lasting 7 months with a NRS score of 7 to 8/10, after negative findings in both CT and myelography. At the first visit (A), she had severe MTrP (X) in the right trapezius muscle and tactile hypoesthesia around the right shoulder (delineated with a blue line). Ten minutes after TPI to MTrP, there was a reduction in the size of the tactile hypoesthesia (B). She was treated in 3 sessions of TPI over 3 weeks and concomitant oral medications with nortriptyline and acetaminophen for 4 weeks. Two weeks later at the second visit, the tactile hypoesthesia had already disappeared (C) along with decrease of pain with an NRS of 5/10 before the second TPI. The NRS became 2/10 or less at 4 weeks after consultation. Left: photograph. Right: tactile hypoesthesia and MTrP depicted on 3-D dermatomes. MTrP, myofascial trigger points; NRS, numerical rating scale.



**Figure 2.** Reduction in the size of tactile hypoesthesia in association with a decrease of myofascial pain by TPI: A typical case. A 63-year-old male patient was referred to our pain clinic with complaints of severe right lateral chest pain. He had no pathological findings such as rib fractures in CT, nor abnormal laboratory data. At the first visit, we found an area of tactile hypoesthesia of 20 cm × 11 cm with an NRS score (degree of hypoesthesia) of 5/10, and MTrP of external oblique muscles (A, the left photographs). Ten minutes after TPI, the hypoesthetic area reduced in its size as shown in A with arrows (the right photograph). He was treated with a total of 8 sessions of TPI with a concomitant oral medication of nortriptyline for 10 weeks. Progressive reductions in the size of hypoesthetic area were observed in parallel with decreases in pain intensity, during TPI therapy (A–E, the left side of photographs and 3-D dermatomes). Note that the areas of tactile hypoesthesia were round or oval and changed plastically without following the dermatomal distribution. MTrP, myofascial trigger points; NRS, numerical rating scale.

area alone. Two patients had allodynia surrounded by a tactile hypoesthetic area. One patient had allodynia alone. Eleven patients had no such sensory abnormalities.

### 3.2. Effects of trigger point injections on the sizes of hypoesthesia and allodynia

Thirty patients who had tactile hypoesthesia underwent TPI. The pain etiology, number of TPI sessions, duration of TPI

therapy, and concomitant oral medications of these patients are summarized in **Table 2**. Twenty-seven (90%) patients experienced a reduction in pain intensity by more than 50% in NRS after TPI therapy (**Table 3**). In all these 27 patients, a reduction in the size of the hypoesthetic area was observed during the course of treatment, with a complete disappearance of the tactile hypoesthesia observed in 6 patients (**Table 3**). The complete disappearance occurred more frequently in primary compared to secondary myofascial pain ( $P < 0.01$ ). A typical

**Table 2****Etiology of pain and details of therapy.**

Etiology of pain	No. of TPI sessions	Duration of therapy (wks)	Oral medications
Primary myofascial pain			
Unknown cause	5	2–6 (3)	Nortriptyline (1), acetaminophen (1)
Cough	1	8	Nortriptyline, acetaminophen, dihydrocodeine
Secondary myofascial pain			
Postsurgical pain (n = 12)			
Mastectomy	4	3–16 (6)	Nortriptyline (2), acetaminophen (3), dihydrocodeine (2), pregabalin (1), NSAIDs (1)
Video-assisted thoracic surgery (VATS)	3	2–5 (2)	—
Parotidectomy	2	2–4 (3)	4–8 (6)
Laparoscopic colectomy and VATS	1	9	15
Laparoscopic cholecystectomy	1	2	3
Blood vessel prosthesis implantation for thoracic dissecting aneurysm	1	19	40
Possible neuropathic pain (n = 7)			
Myelopathy, radiculopathy (cervical spondylosis, scoliosis)	4	3–29 (15)	5–36 (22)
Zoster-associated pain, postherpetic neuralgia	3	2–14 (3)	4–16 (5)
Cancer-related pain (n = 1)			
Bone metastasis (p/s esophagectomy)	1	4	13
Other pain pathology (n = 4)			
Contusion	1	2	3
Third molar	1	3	4
Atypical facial pain	1	2	4
Chronic primary pain	1	2	4

No. of TPI sessions and duration of therapy (wks) were shown as minimum–maximum (median) if indicated. No., numbers; TPI, trigger point injection(s); VATS, video-assisted thoracic surgery.

case is shown in **Figure 2**. In 2 patients who had allodynia surrounded by the hypoesthesia, the sensory abnormalities disappeared completely after 2 and 5 sessions of TPI, respectively. In one patient who had allodynia alone, the allodynic area disappeared with a reduction of pain after 5 sessions of TPI.

### 3.3. Immediate reduction in the size of hypoesthesia after trigger point injections

An immediate reduction of hypoesthesia was observed in 5 of 6 patients with primary myofascial pain, and 4 of 24 patients with secondary myofascial pain (**Figs. 1B and 2** right photographs, **Table 3**). The immediate reduction occurred more frequently in primary than secondary myofascial pain ( $P < 0.005$ ).

### 3.4. Topography of the reversible tactile hypoesthesia

Reversible tactile hypoesthesia was round or oval in shape and often showed a nondermatomal distribution (**Figs. 1 and 2**). The initial degree of hypoesthesia in the cutaneous area of the reversible hypoesthesia ranged from 5 to 8. Tactile hypoesthesia was felt by patients as something like a thin membrane layer between the cotton swab and the skin.

Myofascial trigger points were located in the muscles in the vicinity of ipsilateral cutaneous dermatomes to which the hypoesthetic areas belonged, or approximate myotomes that seemed to share the same spinal nerves (**Figs. 1 and 2**).

### 3.5. Effects of trigger point injections in patients without tactile sensory abnormalities

Ten of 11 patients who did not have sensory abnormalities underwent TPI. Nine of the 10 patients experienced more than a 50% decrease of pain in the NRS.

## 4. Discussion

Reversible hypoesthesia with TPI therapy was found in 58.7% of patients with MTrP. Our findings indicate the relatively high prevalence of reversible hypoesthesia in patients with MTrP. We also observed that a reduction in the size or disappearance of such hypoesthesia occurred in parallel with a reduction of myofascial pain. The reduction in the size of the hypoesthesia was observed progressively during TPI therapy and occasionally immediately after TPI. These findings suggest a close pathophysiological relation between MTrP and tactile sensation. In painful conditions other than muscular pain, the phenomenon of pain-induced tactile hypoesthesia has been described previously.<sup>3,6,12,18,21,22,28</sup> As for underlying mechanisms, several brain imaging studies have shown that the activity of the primary somatosensory cortex decreases along with a decline in touch sensation.<sup>4,19,26</sup> Such inhibition of neuronal activity in the somatosensory cortex induced by ongoing afferent nociceptive input from MTrP may underlie the reversible tactile hypoesthesia in patients with MPS.

Tactile hypoesthesia associated with myofascial pain can mimic that of neuropathic pain.<sup>8,15,16</sup> In our patients, a disappearance or reduction in the size of tactile hypoesthesia after TPI occurred less frequently in patients with secondary myofascial pain compared to those with primary myofascial pain. A lower frequency of reduction or disappearance of tactile hypoesthesia in patients with secondary MPS may be attributed to the existence of tactile hypoesthesia induced by nerve lesions in this group of patients. Topographically, remaining hypoesthetic areas observed after TPI therapy are thought of as hypoesthesia related to somatosensory nerve lesions that may be associated with neuropathic pain.

From a clinical point of view, we suggest that it is important to diagnose MTrP and treat it with TPI to distinguish neuropathic

**Table 3****Effects of TPI on pain intensity and tactile hypoesthesia in 30 patients who had tactile hypoesthesia that underwent TPI.**

Types and etiology of pain	No. of patients	Effects of TPI			
		Decrease of pain NRS by more than 50%	Reduction in size of tactile hypoesthesia	Immediate reduction 10 minutes after TPI	Complete disappearance of the tactile hypoesthesia
Primary myofascial pain					
Unknown cause	5	5	5	4	3
Cough	1	1	1	1	1
Secondary myofascial pain					
Postsurgical pain (n = 12)					
Mastectomy	4	4	4	0	0
Video-assisted thoracic surgery (VATS)	3	3	3	0	0
Parotidectomy	2	2	2	0	1
Laparoscopic colectomy and VATS	1	1	1	1	0
Laparoscopic cholecystectomy	1	1	1	1	1
Blood vessel prosthesis implantation for thoracic dissecting aneurysm	1	1	1	0	0
Possible neuropathic pain (n = 7)					
Myelopathy, radiculopathy (cervical spondylosis, scoliosis)	4	4	4	1	0
Zoster-associated pain, postherpetic neuralgia	3	3	3	0	0
Cancer-related pain (n = 1)					
Bone metastasis (p/s esophagectomy)	1	1	1	1	0
Other pain pathology (n = 4)					
Contusion	1	0	0	0	0
Third molar	1	1	1	0	0
Atypical facial pain	1	0	0	0	0
Chronic primary pain	1	0	0	0	0
<b>Total no. of patients</b>	<b>30</b>	<b>27</b>	<b>27</b>	<b>9</b>	<b>6</b>

NRS, numerical rating scale; TPI, trigger point injection(s); VATS, video-assisted thoracic surgery.

pain from myofascial pain. In addition, the mapping of hypoesthetic areas is useful for detecting MTrP because MTrP are located in the muscles in the vicinity of dermatomes to which the hypoesthetic areas belong.

This study had some limitations. One limitation is that we did not investigate the relationship between the area of reversible hypoesthesia and referred pain area. Numbness or hypoesthesia were reported to occur in the area of referred pain in patients with muscular pain<sup>2,7,16,17</sup> as well as volunteers with experimentally induced muscular pain.<sup>14,15</sup> Another limitation is that we were not able to investigate why some patients had tactile hypoesthesia and others did not, whereas 90% of patients in both groups experienced more than 50% pain relief by TPI.

In summary, although not always, reversible tactile hypoesthesia with TPI therapy often occurred in patients with MPS. Our present findings suggest that treating MTrP with TPI is important to distinguish tactile hypoesthesia associated with neuropathic pain from that with myofascial pain. Moreover, the mapping of tactile hypoesthesia on the skin seems useful for detecting MTrP because of their close topographical relation.

## Disclosures

The authors have no conflict of interest to declare.

## Acknowledgements

The authors thank the patients for permitting use of their photographs on this manuscript. The authors also thank Ms. Yuko Takeuchi for assistance with manuscript preparation.

## Article history:

Received 22 February 2019

Received in revised form 15 May 2019

Accepted 5 June 2019

## References

- [1] Adamczyk WM, Saulicz O, Saulicz E, Luedtke K. Tactile acuity (dys) function in acute nociceptive low back pain: a double-blind experiment. *PAIN* 2018;159:427–36.
- [2] Ambite-Quesada S, Arias-Buría JL, Courtney CA, Arendt-Nielsen L, Fernández-De-Las-Peñas C. Exploration of quantitative sensory testing in latent trigger points and referred pain areas. *Clin J Pain* 2018;34:409–14.
- [3] Apkarian AV, Stea RA, Bolanowski SJ. Heat-induced pain diminishes vibrotactile perception: a touch gate. *Somatosens Mot Res* 1994;11:259–67.
- [4] Apkarian AV, Stea RA, Manglos SH, Szevereniy NM, King RB, Thomas FD. Persistent pain inhibits contralateral somatosensory cortical activity in humans. *Neurosci Lett* 1992;140:141–7.
- [5] Bennett R. Myofascial pain syndromes and their evaluation. *Best Pract Res Clin Rheumatol* 2007;21:427–45.
- [6] Catley MJ, O'Connell NE, Beryman C, Ayhan FF, Moseley GL. Is tactile acuity altered in people with chronic pain? A systematic review and meta-analysis. *J Pain* 2014;15:985–1000.
- [7] Fernández-de-Las-Peñas C, Dommerholt J. International consensus on diagnostic criteria and clinical considerations of myofascial trigger points: a Delphi study. *Pain Med* 2018;19:142–50.
- [8] Finnerup NB, Haroutounian S, Kamerman P, Baron R, Bennett DL, Bouhassira D, Cruccu G, Freeman R, Hansson P, Nurmiikko T, Raja SN. Neuropathic pain: an updated grading system for research and clinical practice. *PAIN* 2016;157:1599–606.
- [9] Geber C, Magerl W, Fondel R, Fehrer M, Rolke R, Vogt T, Treede RD, Birkléin F. Numbness in clinical and experimental pain—a cross-sectional study exploring the mechanisms of reduced tactile function. *PAIN* 2008;139:73–81.
- [10] Gerwin RD. Diagnosis of myofascial pain syndrome. *Phys Med Rehabil Clin N Am* 2014;25:341–55.

- [11] Giamberardino MA, Affaitati G, Fabrizio A, Costantini R. Myofascial pain syndromes and their evaluation. *Best Pract Res Clin Rheumatol* 2011;25:185–98.
- [12] Harper DE, Hollins M. Is touch gating due to sensory or cognitive interference? *PAIN* 2012;153:1082–90.
- [13] Hollins M, Sigurdsson A, Fillingim L, Goble AK. Vibrotactile threshold is elevated in temporomandibular disorders. *PAIN* 1996;67:89–96.
- [14] Kosek E, Hansson P. The influence of experimental pain intensity in the local and referred pain area on somatosensory perception in the area of referred pain. *Eur J Pain* 2002;6:413–25.
- [15] Leffler AS, Kosek E, Hansson P. Injection of hypertonic saline into musculus infraspinatus resulted in referred pain and sensory disturbances in the ipsilateral upper arm. *Eur J Pain* 2000;4:73–82.
- [16] Leffler AS, Kosek E, Hansson P. The influence of pain intensity on somatosensory perception in patients suffering from subacute/chronic lateral epicondylalgia. *Eur J Pain* 2000;4:57–71.
- [17] Leffler AS, Hansson P, Kosek E. Somatosensory perception in patients suffering from long-term trapezius myalgia at the site overlying the most painful part of the muscle and in an area of pain referral. *Eur J Pain* 2003;7:267–76.
- [18] Magerl W, Treede RD. Secondary tactile hypoesthesia: a novel type of pain-induced somatosensory plasticity in human subjects. *Neurosci Lett* 2003;361:136–9.
- [19] Mailis-Gagnon A, Giannoylis I, Downar J, Kwan CL, Mikulis DJ, Crawley AP, Nicholson K, Davis KD. Altered central somatosensory processing in chronic pain patients with “hysterical” anesthesia. *Neurol* 2003;60:1501–7.
- [20] Moriwaki K, Sanuki M, Sugimoto Y, Hashimoto K, Toyota Y, Shiroyama K, Kurita S, Fujii K. Tactile hypoesthesia associated with myofascial trigger points in patients with persistent post-mastectomy pain—a close observation study in a case series. *Anesth Resus* 2019;55:71–4.
- [21] Moriwaki K, Yuge O. Topographical features of cutaneous tactile hypoesthetic and hyperesthetic abnormalities in chronic pain. *PAIN* 1999;81:1–6.
- [22] Moriwaki K, Yuge O, Nishioka K, Yamanoue T, Nakao M. Reduction in the size of tactile hypesthesia and allodynia closely associated with pain relief in patients with chronic pain. In: GF Gebhart, DL Hammond, TS Jensen, editors. *Progress in pain research and management*. Vol. 2. Seattle: IASP Press, 1994. p. 819–830.
- [23] Nathan PW. Improvement in cutaneous sensibility associated with relief of pain. *J Neurol Neurosurg Psychiatry* 1960;23:202–6.
- [24] Shah JP, Thaker N, Heimur J, Aredo JV, Sikdar S, Gerber L. Myofascial trigger points then and now: a historical and scientific perspective. *PM R* 2015;7:746–61.
- [25] Simons DG, Travell JG, Simons LS. *Myofascial pain and dysfunction: the trigger point manual*. Vol. 1. 2nd ed. Philadelphia: Williams & Wilkins, 1999. p. 31–5.
- [26] Stammer T, De Col R, Seifert F, Maihöfner C. Functional imaging of sensory decline and gain induced by differential noxious stimulation. *Neuroimage* 2008;42:1151–63.
- [27] Stohler CS, Kowalski CJ, Lund JP. Muscle pain inhibits cutaneous touch perception. *PAIN* 2001;92:327–33.
- [28] Younis S, Maarbjerg S, Reimer M, Wolfram F, Olesen J, Baron R, Bendtsen L. Quantitative sensory testing in classical trigeminal neuralgia—a blinded study in patients with and without concomitant persistent pain. *PAIN* 2016;157:1407–14.