

Oncology

MRI-guided pelvic lymph node biopsy via transrectal approach in prostate cancer



Christian Hague^a, Luke P. O'Connor^{a,*}, Alex Z. Wang^a, Patrick T. Gomella^a, Nitin K. Yerram^a, Maria J. Merino^b, Peter A. Pinto^a

^a Urologic Oncology Branch, National Cancer Institute, National Institutes of Health, Bethesda, MD, USA

^b Laboratory of Pathology, National Cancer Institute, National Institutes of Health, USA

ARTICLE INFO

Keywords:

MRI/TRUS fusion-guided biopsy
Lymph node biopsy
Prostate cancer
Pre-operative staging

ABSTRACT

Lymph node assessment in prostate cancer is most commonly performed at the time of radical prostatectomy. We present the case of pre-operative pelvic lymph node sampling with the use of MRI/TRUS fusion-guided biopsy at the time of prostate biopsy. Lymph node pathology revealed metastatic, poorly differentiated prostate cancer, concurrent with Gleason 4 + 5 disease showing perineural invasion. The use of MRI fusion guided biopsy for nodal sampling may be an effective method pre-operative staging and treatment planning for prostate adenocarcinoma.

Introduction

Sampling of suspicious lymph nodes in prostate cancer patients is traditionally completed during their scheduled radical prostatectomy. However, for poor surgical candidates, the morbidity of the surgery may outweigh the benefits. Thus, an effective method of minimally invasive nodal sampling may be a more accurate means of initial staging prior to surgical intervention. We present the case of a patient with suspicious lymph nodes, which were sampled using MRI/TRUS fusion-guided biopsy at the time of his prostate biopsy.

Case presentation

A 71-year-old male presented to our institution for a second opinion on elevated PSA and two suspicious lesions on initial prostate MRI read. Upon re-reading, a single large lesion occupying most of the peripheral zone bilaterally with evidence of extra-prostatic extension was identified. The lesion diameter was 5.3cm and scored as a PIRADS 5 lesion. Additionally, there were enlarged pelvic lymph nodes bilaterally, measured as 1.3cm on the right and 0.9cm on the left (Fig. 1).

The patient's past medical history includes a prostate biopsy in 2012, which showed High-grade prostatic intraepithelial neoplasia (HGPIN) of the left base. The patient was then followed with bi-annual PSA values. Since 2017, his PSA rose from 5.3 ng/mL to 9.9 ng/mL. Additionally, the patient underwent a transurethral resection of the prostate (TURP) in

2018 for lower urinary tract symptoms, which resolved his symptoms and revealed normal pathology results. His family history was positive for prostate cancer.

The patient was scheduled to undergo MRI-fusion guided biopsy of both the prostate as well as the enlarged pelvic lymph nodes to assess for nodal metastases. The patient underwent standard of care 12-core TRUS biopsy as well as targeted biopsy of the PIRADS 5 lesion and enlarged right-sided pelvic lymph node (Fig. 2). Pathology reported Gleason 4 + 5 disease for the targeted PIRADS 5 lesion (Fig. 3). Lymph node pathology was read as metastatic, poorly differentiated prostate adenocarcinoma.

Discussion

Nodal status is a significant prognostic factor in prostate cancer with node positive patients having much higher mortality compared to node negative patients. Overall survival in cohorts have been found to be as low as 44% after 10 years.¹ Additionally, large differences in "best treatment" varies after the presence of metastasis is confirmed. Because of its importance, the accurate establishment of nodal status in patients is paramount to their treatment course and overall prognosis.

Pre-operative lymph node assessment in patients has evolved greatly in recent years due to a lack of sensitivity and specificity of standard MRI and CT imaging.² Sentinel lymph node identification using Prostate Specific Membrane Antigen (PSMA) PET/CT scanning is an experimental method that has shown great promise with sensitivity and

* Corresponding author. Address: 10 Center Dr, Room 2W-5940, Bethesda, MD, 20814, USA.

E-mail address: luke.o'connor@nih.gov (L.P. O'Connor).

<https://doi.org/10.1016/j.eucr.2020.101129>

Received 10 December 2019; Received in revised form 21 January 2020; Accepted 22 January 2020

Available online 27 January 2020

2214-4420/© 2020 Published by Elsevier Inc. This is an open access article under the CC BY-NC-ND license (<http://creativecommons.org/licenses/by-nc-nd/4.0/>).

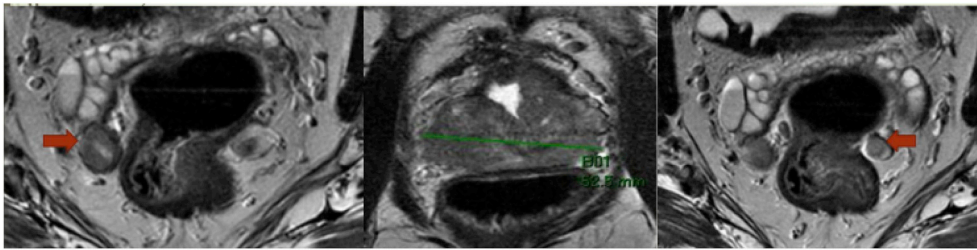


Fig. 1. Prostate MRI images. Left – enlarged 1.3 cm right pelvic lymph node (red arrow), middle – 5.3 cm prostate lesion, right – enlarged 0.9 cm left pelvic lymph node (red arrow). (For interpretation of the references to colour in this figure legend, the reader is referred to the Web version of this article).

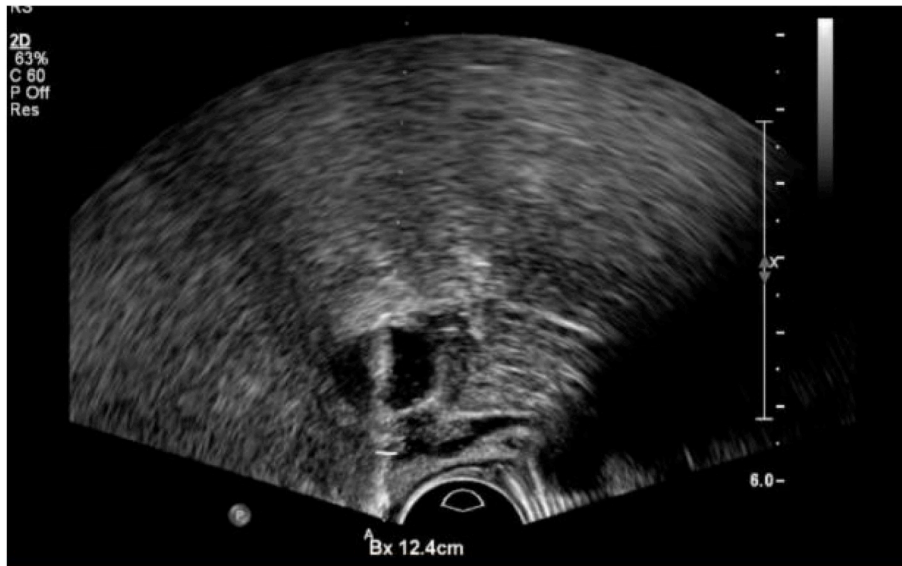


Fig. 2. Biopsy of right-sided pelvic lymph node. UroNav (Philips/Invivo, Gainesville, FL) imaging obtained during MRI targeted biopsy showing successful needle biopsy.

specificity approaching 93% and 100%, respectively.³ Additional methods of pre-operative nodal imaging include diffusion-weighted MRI and Ultrasmall Superparamagnetic Iron Oxide MRI, both of which have improved sensitivity and specificity compared to standard MRI.^{4,5} While these preliminary studies have shown encouraging results, further study is needed to validate these methods. Finding these sentinel nodes allows surgeons to perform a minimally invasive and more focused excision of affected lymph nodes prior to prostatectomy.

Our institution sought to determine if MRI/TRUS fusion-guided biopsy of suspicious pelvic lymph nodes was a viable method of determining nodal status. Two transrectal biopsies were taken of the larger right lymph node in addition to the prostatic cores. This is a minimally invasive procedure that may be performed under local anesthesia, sedation, or general anesthesia concurrently with prostate biopsy.

No matter the advancement of non-invasive nodal assessment, tissue samples are required to make the diagnosis of cancer and metastasis. We present a novel method of obtaining tissue samples of suspicious lymph nodes in a minimally invasive fashion, which may make it ideal for patients who are poor surgical candidates. Such a method requires further study to assess the risk to benefit ratio for patients compared to other traditional methods. Risks of this approach include infection from penetration of rectal mucosa, bleeding, and damage to other surrounding structures.

Conclusion

This case was able to show that transrectal biopsy of suspicious pelvic lymph nodes is an effective means of nodal sampling that offers

several advantages. It is not only minimally invasive but may be performed at the time of a patient's scheduled prostate biopsies, allowing for less procedure time. Additionally, the negative effects of the procedure will predominately be those associated with transrectal prostate biopsies to potentially allow for a safer side effect profile compared to other nodal sampling methods. This novel method will require more study before making final decisions regarding its true efficacy. However, we demonstrated the viability of a minimally invasive approach for more accurate prostate cancer staging.

Funding

This research was made possible through the National Institutes of Health (NIH) Medical Research Scholars Program, a public-private partnership supported jointly by the NIH and generous contributions to the Foundation for the NIH from the Doris Duke Charitable Foundation, Genentech, the American Association for Dental Research, the Colgate-Palmolive Company, alumni of student research programs, and other individual supporters via contributions to the Foundation for the National Institutes of Health.

Declaration of competing interest

NIH and Philips have a Cooperative Research and Development Agreement. NIH has intellectual property in the field, including among other patents and patent applications, Patent: "System, methods, and instrumentation for image guided prostate treatment" US Patent number: 8948845, with inventor/author PP. NIH and Philips (InVivo Inc)

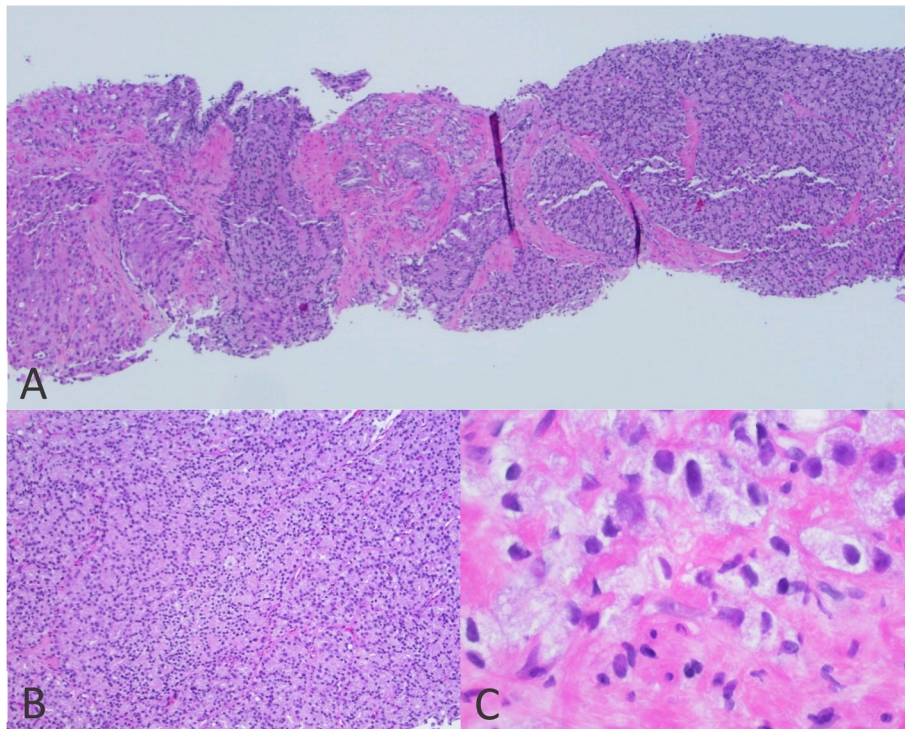


Fig. 3. Histopathologic images from biopsy specimen. Image showing low-powered view of the entire biopsy core (A) and high-powered views of Gleason pattern 4 (B) and Gleason pattern 5 (C).

have a licensing agreement. NIH and author PP receive royalties for a licensing agreement with Philips/InVivo Inc. NIH does not endorse or recommend any commercial products, processes, or services. The views and personal opinions of authors expressed herein do not necessarily reflect those of the US Government, nor reflect any official recommendation nor opinion of the NIH nor NCI.

Appendix A. Supplementary data

Supplementary data to this article can be found online at <https://doi.org/10.1016/j.eucr.2020.101129>.

References

1. Mathers MJ, et al. Patients with localised prostate cancer (t1-t2) show improved overall long-term survival compared to the normal population. *J Canc.* 2011;2:76.
2. Thoeny HC, et al. Functional and targeted lymph node imaging in prostate cancer: current status and future challenges. *Radiology.* 2017;285(3):728–743.
3. von Eyben FE, et al. (68)Ga-Labeled prostate-specific Membrane antigen ligand positron emission tomography/computed tomography for prostate cancer: a systematic review and meta-analysis. *Eur Urol Focus.* 2018;4(5):686–693.
4. Thoeny HC, et al. Metastases in normal-sized pelvic lymph nodes: detection with diffusion-weighted MR imaging. *Radiology.* 2014;273(1):125–135.
5. Triantafyllou M, et al. Ultrasmall superparamagnetic particles of iron oxide allow for the detection of metastases in normal sized pelvic lymph nodes of patients with bladder and/or prostate cancer. *Eur J Canc.* 2013;49(3):616–624.