

## Primary laryngeal cryptococcosis mimicking laryngeal malignancy: a case report

Kazuya Tonai, Naoki Nishio, Sayaka Yokoi, Masumi Kobayashi  
and Michihiko Sone

*Department of Otorhinolaryngology, Nagoya University Graduate School of Medicine, Nagoya, Japan*

### ABSTRACT

Primary laryngeal cryptococcosis is an extremely rare infection and presents with non-specific symptoms such as hoarseness or sore throat, resulting in delayed diagnosis. Here, we report the patient of a 56-year-old female patient with primary laryngeal cryptococcosis, who was being treated with oral and inhaled steroids for rheumatoid arthritis and bronchial asthma. The patient suffered from prolonged hoarseness and sore throat, and endoscopic biopsy was performed several times under local anesthesia, demonstrating only inflammatory cell infiltration. Considering the possibility of laryngeal malignancy, a third biopsy was performed by endoscopic laryngomicrosurgery under general anesthesia. Intraoperative frozen section revealed non-neoplastic laryngeal mucosa with erosion and severe inflammatory cell infiltration. However, we could not confirm the definite diagnosis of the lesion in the intraoperative consultation. Postoperative histopathological examination revealed a small number of yeast-type fungi and a definitive diagnosis was established by special stains including Alcian blue stain. Finally, the patient was diagnosed as primary laryngeal cryptococcosis. Daily oral administration of fluconazole (400 mg/day) was performed for 6 months according to the treatment protocol for pulmonary cryptococcosis. The symptoms gradually improved, and endoscopy revealed no recurrence 6 months post-treatment. Clinicians should consider the possibility of laryngeal cryptococcosis when severe inflammation is found in the larynx and discuss the disease history and pathological results with pathologists more closely.

**Keywords:** laryngeal cryptococcosis, yeast-like fungus, Alcian blue stain, fluconazole, inhaled corticosteroid

This is an Open Access article distributed under the Creative Commons Attribution-NonCommercial-NoDerivatives 4.0 International License. To view the details of this license, please visit (<http://creativecommons.org/licenses/by-nc-nd/4.0/>).

### INTRODUCTION

Cryptococcus is an encapsulated yeast-type fungus that is widespread in the environment and often causes pulmonary infections or central nervous system infections in humans through the respiratory tract. Primary laryngeal cryptococcosis is an extremely rare disease that presents with non-specific symptoms such as hoarseness or sore throat, and approximately 30 patients with laryngeal cryptococcosis have been reported worldwide until now.<sup>1,2</sup> Due to the variety

---

Received: September 17, 2021; accepted: February 2, 2022

Corresponding Author: Naoki Nishio, MD, PhD

Department of Otorhinolaryngology, Nagoya University Graduate School of Medicine, 65 Tsurumai-cho, Showa-ku, Nagoya 466-8550, Japan

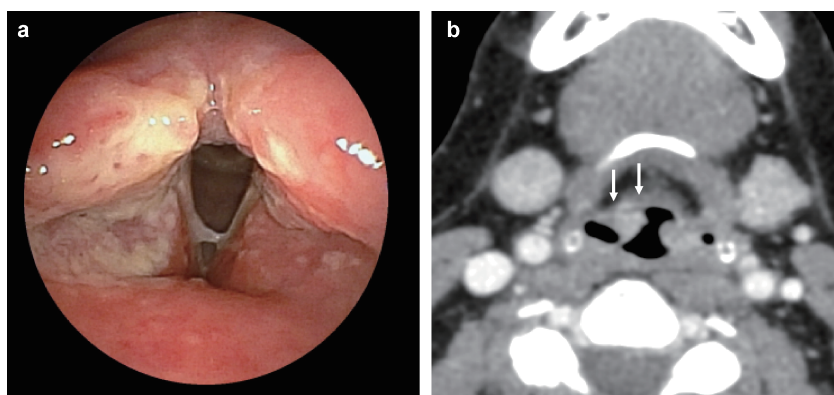
Tel: +81-52-744-2323, E-mail: [naokin@med.nagoya-u.ac.jp](mailto:naokin@med.nagoya-u.ac.jp)

of clinical manifestations, laryngeal cryptococcosis is occasionally misdiagnosed as chronic laryngitis or laryngeal malignancy. Adequate tissue sampling from the larynx is essential for the diagnosis of laryngeal cryptococcosis; however, it is often difficult to obtain sufficient tissue samples because of prolonged bleeding and laryngeal reflexes. This leads to delayed diagnoses in most patients.<sup>3-5</sup> Multiple biopsies are often required for the accurate diagnosis of laryngeal cryptococcosis. Some patients from the previous reports were diagnosed based on the repeated recurrence and remission for about half a year.<sup>3,4</sup> Furthermore, accurate diagnosis and distinction of laryngeal cryptococcal infections from other fungal infections with a yeast-type morphology, such as candidiasis, is difficult. Here, we report a patient of laryngeal cryptococcosis diagnosed by endoscopic laryngomicrosurgery under general anesthesia and specific Alcian blue stain of the sampled laryngeal tissues.

### CASE REPORT

Written informed consent was obtained from the patient for publishing this patient report and accompanying images. The patient was a 56-year-old woman with chief complaints of sore throat and hoarseness. She had a history of asthma, cervical hernia, lumbar hernia, rheumatoid arthritis, and hyperlipidemia. She was being treated with oral and inhaled steroids and immunosuppressive drugs for rheumatoid arthritis and asthma. She had no history of infection or allergies. Initially, her condition was clinically diagnosed as candidiasis of the larynx by a family doctor, where she received amphotericin B treatment. However, her symptoms did not improve. She was referred to a municipal hospital, where the first biopsy performed under local anesthesia. The first biopsy sample revealed laryngeal mucosa with severe inflammation. No sign of fungal infection was observed even after our retrospective slide review. After 4 months, she visited our university hospital due to persistent hoarseness and sore throat.

Flexible endoscopy was performed that revealed a white lesion extending from the right lacunae to the vestibular fold in the larynx (Fig. 1a). A second biopsy was performed at our hospital under local anesthesia. The specimen showed no fungal infection and lympho-plasmacytic inflammation without neoplastic or malignant features. The  $\alpha$ -streptococcus species was detected in the culture test. Her blood tests showed no inflammatory response, with a white blood cell



**Fig. 1** Endoscopic and contrast-enhanced computed tomography findings of the patient

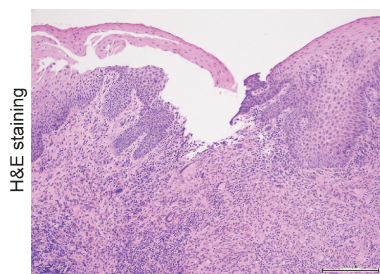
**Fig. 1a:** A white ridge lesion was found extending from the right lacunae to the vestibular fold.

**Fig. 1b:** A contrast-enhanced effect was observed in the right vestibular fold (arrows).

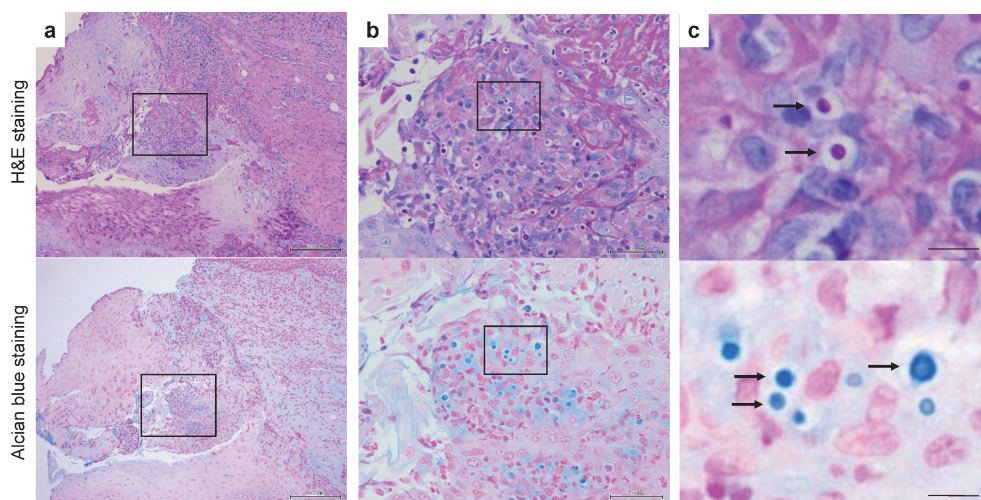
count of 5400/ $\mu\text{L}$  and C-reactive protein level of 0.02 mg/dL. Contrast-enhanced computed tomography revealed a contrast-enhanced effect in the right vestibular fold (Fig. 1b).

Considering the possibility of laryngeal malignancy, a third biopsy was performed by endoscopic laryngomicrosurgery under general anesthesia. Intraoperative frozen section revealed non-neoplastic laryngeal mucosa with erosion and severe inflammatory cell infiltration (Fig. 2).

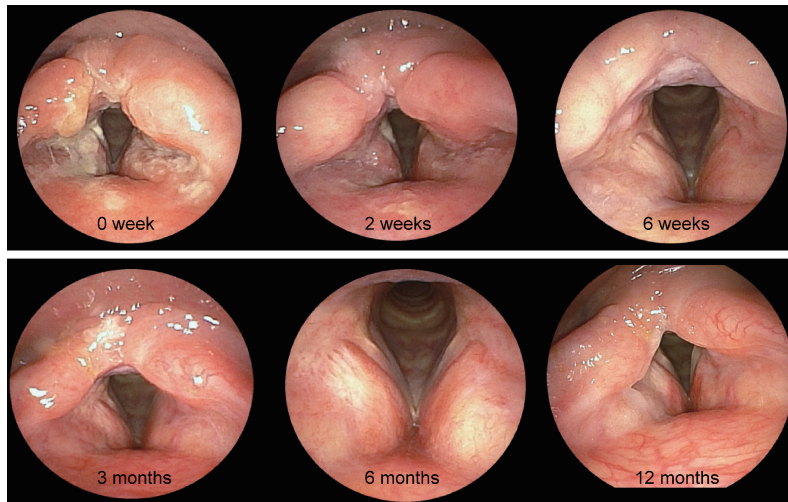
However, we could not confirm the definite diagnosis of the lesion in the intraoperative consultation. Postoperative histopathological examination revealed a small number of yeast-type fungi. The clearing effect around the organism represented a mucinous capsule. The capsule was highlighted with Alcian blue stain (Fig. 3). After the discussion of the patient's history and endoscopic findings between otolaryngologists and pathologists, her condition was diagnosed as primary laryngeal cryptococcosis. To rule out pulmonary cryptococcosis and cryptococcal meningitis, chest computed tomography and cerebrospinal fluid examination were additionally conducted, and the findings were normal. Additionally,  $\beta$ -D-glucan, serum cryptococcal antigen, and human immunodeficiency virus test results were negative.



**Fig. 2** Hematoxylin and eosin (H&E) staining of a biopsy sample for the intraoperative frozen analysis (H&E staining (50 $\times$ , Scale bars = 200  $\mu\text{m}$ ). Severe inflammatory cell infiltration and erosion were observed.



**Fig. 3** Hematoxylin and eosin (H&E) staining and Alcian blue stain of biopsy samples  
**Fig. 3a:** 50 $\times$ , Scale bars = 200  $\mu\text{m}$ .  
**Fig. 3b:** 200 $\times$ , Scale bars = 50  $\mu\text{m}$ .  
**Fig. 3c:** 1000 $\times$ , Scale bars = 10  $\mu\text{m}$ . Arrows show encapsulated yeast-type fungi.



**Fig. 4** Endoscopic findings of the larynx during the follow-up period

The white mass lesion shrank immediately after oral administration of fluconazole was started, and it completely disappeared 6 months after the start of treatment. Twelve months after the treatment was started, no recurrence of the disease was observed.

After the diagnosis of primary laryngeal cryptococcosis was made, daily oral administration of fluconazole (400 mg/day) was initiated according to the protocol for pulmonary cryptococcosis treatment. The white mass lesion shrank immediately after the treatment was started, and both sore throat and hoarseness improved 6 weeks after the start of treatment (Fig. 4). The patient completed a 6-month course of daily oral fluconazole treatment, and the symptoms, including hoarseness and sore throat, disappeared. Twelve months after the treatment was started, no recurrence of the disease was observed.

## DISCUSSION

Laryngeal cryptococcosis does not present specific findings on endoscopic examination or computed tomography, leading to a delay in appropriate treatment. When laryngeal leukoplakia is observed, laryngeal cancer, Kaposi's sarcoma, viral infections, laryngeal fungiosis, and laryngeal papillomas are the differential diagnoses. Laryngeal endoscopic features were similar to those of malignant tumors and Kaposi's sarcoma; hence, appropriate diagnosis was not possible by laryngeal endoscopy alone in previous patients.<sup>3-5</sup> In fact, in this patient, our initial assessment was laryngeal leukoplakia indicative of a malignant tumor, such as squamous cell carcinoma. However, no malignant cells were found, even after multiple tissue sampling and frozen section analyses. Laryngeal candidiasis is more common fungal infection of this site and some previous patients with laryngeal cryptococcosis were initially misdiagnosed and were treated as candida infections.<sup>3,4</sup> Although fungal infection is often accompanied by granulomatous inflammation with multinucleated giant cells, the initial biopsy of this case had no granulomatous inflammation. Because of the small size of yeast and no histologic clues of fungal infection like this case, it is important to obtain sufficient tissue samples even under general anesthesia and to identify microorganism by special stains including Alcian blue stain for definitive diagnosis of laryngeal cryptococcosis. In the diagnosis of pulmonary cryptococcosis and cryptococcal meningitis, a



positive serum cryptococcal antigen test is also valuable. However, a recent review indicated that serum cryptococcal antigen was relatively low level, and its testing is unreliable for laryngeal cryptococcosis (sensitivity = 39%).<sup>1,6</sup> In our patient, intraoperative frozen section showed only non-neoplastic laryngeal mucosa with erosion and severe inflammatory cell infiltration. Postoperative histopathological examination revealed a small number of yeast-type fungi and a definitive diagnosis was established by special stains including Alcian blue stain. Thus, a close collaboration between otolaryngologists and pathologists with the discussion of the patient's history and endoscopic findings and the use of an appropriate staining are essential to diagnose primary laryngeal cryptococcosis.

Cryptococcosis is a deep mycosis that develops in patients with underlying diseases such as human immunodeficiency virus infection and acquired immunodeficiency syndrome, which impair the cell-mediated immunity, and in those with drug-associated immune function decline, such as long-term systemic steroid administration. Additionally, the use of inhaled corticosteroids has been listed as a high risk factor for primary laryngeal cryptococcosis.<sup>5</sup> In approximately 30 patients with laryngeal cryptococcosis worldwide, the use of inhaled steroids was confirmed in almost half the patients.<sup>4</sup> Moreover, long-term corticosteroid therapy puts the patients at a significant risk of developing cryptococcal infections.<sup>5,7</sup> To avoid a delay in the accurate diagnosis of laryngeal cryptococcosis, clinicians should consider its possibility not only in immunocompromised patients, but also in healthy individuals when using corticosteroids.

Currently, no clear treatment method has been established in patients with laryngeal cryptococcosis. According to the clinical practice guidelines for the management of cryptococcal disease including pulmonary cryptococcosis and cryptococcal meningitis, daily oral administration of fluconazole (400 mg) is recommended for 3–6 months.<sup>8</sup> In patients with laryngeal cryptococcosis, oral administration of antifungal drugs (3–12 months) has shown a very high therapeutic effect.<sup>9</sup> In most patients of laryngeal cryptococcosis, the usual daily fluconazole dose was 400 mg, and the duration ranged from 6–44 weeks.<sup>3,4,10</sup> Despite the therapeutic effect of fluconazole, a patient of disease recurrence has been reported previously during the follow-up period due to insufficient dose and duration of fluconazole.<sup>10</sup> Another patient had persistence of hoarseness after 6 weeks of insufficient daily fluconazole (200 mg).<sup>10</sup> In our patient, oral administration of fluconazole (400 mg) for 6 months showed a high therapeutic effect and no recurrence of the disease was observed 12 months after the treatment was started. A flexible endoscopy is less invasive and helpful to evaluate the mucosal diseases in the head and neck region. For early diagnosis of disease recurrence, frequent endoscopic observation is recommended once every 2–3 months even after oral administration of antifungal drugs.

#### ACKNOWLEDGEMENT

The authors would like to thank Masato Nakaguro for the histopathological examination.

#### DISCLOSURE STATEMENT

The authors have no financial conflicts of interest to declare.

## REFERENCES

- 1 Worrall DM, Lerner DK, Naunheim MR, Woo P. Laryngeal cryptococcosis: an evolving rare clinical entity. *Ann Otol Rhinol Laryngol*. 2019;128(5):472–479. doi:10.1177/0003489419826131.
- 2 Quintero O, Trachuk P, Lerner MZ, Sarungbam J, Pirofski LA, Park SO. Risk factors of laryngeal cryptococcosis: a case report. *Med Mycol Case Rep*. 2019;24:82–85. doi:10.1016/j.mmcr.2019.04.009.
- 3 Mittal N, Collignon P, Pham T, Robbie M. Cryptococcal infection of the larynx: case report. *J Laryngol Otol*. 2013;127(Suppl 2):S54–S56. doi:10.1017/S0022215113000522.
- 4 Wong DJY, Stanley P, Paddle P. Laryngeal cryptococcosis associated with inhaled corticosteroid use: case reports and literature review. *Front Surg*. 2017;4:63. doi:10.3389/fsurg.2017.00063.
- 5 Tamagawa S, Hotomi M, Yuasa J, et al. Primary laryngeal cryptococcosis resembling laryngeal carcinoma. *Auris Nasus Larynx*. 2015;42(4):337–340. doi:10.1016/j.anl.2015.01.003.
- 6 Gordon DH, Stow NW, Yapa HM, Bova R, Marriott D. Laryngeal cryptococcosis: clinical presentation and treatment of a rare cause of hoarseness. *Otolaryngol Head Neck Surg*. 2010;142(3 Suppl 1):S7–S9. doi:10.1016/j.otohns.2009.08.030.
- 7 Isaacson JE, Frable MA. Cryptococcosis of the larynx. *Otolaryngol Head Neck Surg*. 1996;114(1):106–109. doi:10.1016/s0194-5998(96)70293-0.
- 8 Perfect JR, Dismukes WE, Dromer F, et al. Clinical practice guidelines for the management of cryptococcal disease: 2010 update by the infectious diseases society of America. *Clin Infect Dis*. 2010;50(3):291–322. doi:10.1086/649858.
- 9 Frisch M, Gnepp DR. Primary cryptococcal infection of the larynx: report of a case. *Otolaryngol Head Neck Surg*. 1995;113(4):477–480. doi:10.1016/s0194-5998(95)70089-7.
- 10 Bergeron M, Gagné AA, Côté M, Chênevert J, Dubé R, Pelletier R. Primary larynx *Cryptococcus neoformans* infection: a distinctive clinical entity. *Open Forum Infect Dis*. 2015;2(4):ofv160. doi:10.1093/ofid/ofv160.