

Urethral bulking agent found in a urethral caruncle which did not respond to topical oestrogens: A case report

Christopher Savvas^a, George Araklitis^{a,*}, Chirag Shah^b, Dudley Robinson^a, Linda Cardozo^a

^a Department of Urogynaecology, Suite 8, Golden Jubilee Wing, King's College Hospital, SE5 9RS, UK

^b Department of Histopathology, King's College Hospital, SE5 9RS, UK

ARTICLE INFO

Article history:

Received 19 October 2020

Received in revised form 21 October 2020

Accepted 22 October 2020

Keywords:

Macroplastique
Urethral bulking agent
Urethral caruncle

ABSTRACT

Background: Urethral caruncles are lesions occurring at the urethral orifice, around the posterior lip of the urethra. They are the most common benign growth of the female urethra. They are often asymptomatic and found incidentally on clinical examination. When symptomatic they commonly present with bleeding. Treatment includes vaginal oestrogens or, failing that, surgical excision. We present an unusual finding after excision of a urethral caruncle.

Case: A patient with a background of stress urinary incontinence had numerous pelvic surgeries, including colposuspension, tension-free vaginal tape (TVT) and Macroplastique (a urethral bulking agent). She developed bleeding from a 3 cm urethral caruncle, which did not improve with vaginal oestrogens. She proceeded to have a surgical excision of the caruncle. Histology revealed a foreign material with surrounding foreign-body-type multinucleate giant cell reaction. The material was compatible with Macroplastique.

Conclusion: This case report describes an unusual and unexpected histological finding. Macroplastique is injected in the urethra, 10–15 mm from the bladder neck. We suspect the caruncle dragged the Macroplastique material out through the urethral meatus. If urethral caruncles are not adequately treated with vaginal oestrogens, surgery should be considered.

© 2020 Published by Elsevier B.V. This is an open access article under the CC BY-NC-ND license (<http://creativecommons.org/licenses/by-nc-nd/4.0/>).

1. Introduction

Urethral caruncles are lesions occurring at the urethral orifice, around the posterior lip of the urethra [1]. Samuel Sharp first described it in 1750 [2]. It is differentiated from a urethral prolapse, which is a circumferential eversion of the urethra around the whole meatus [1]. A caruncle is usually bright red and is the most common benign growth of the female urethra [1]. They are usually less than 1 cm, often asymptomatic and found incidentally on clinical examination. They may often present with vaginal spotting or blood on wiping and may be confused with postmenopausal uterine bleeding [1]. Urethral caruncles are thought to be caused by hypoestrogenism and are commonly seen in pre-pubescent girls, particularly in those of Afro-Caribbean background, post-partum women [3], and post-menopausal women [1]. Other risk factors include chronic cough, constipation, obesity [1] and connective tissue disorders with women reporting a personal or family history of hernias or pelvic organ prolapse [3].

Treatment depends on whether the patient is symptomatic. Conservative therapy with topical vaginal oestrogens is recommended as first-line management although surgery may be required if symptoms

persist despite medical therapy, or if the condition causes urinary retention or if malignancy is suspected.

We present a case of a symptomatic urethral caruncle with an unusual and unexpected histological finding.

2. Case Report

A 65-year-old woman presented to a tertiary urogynaecology department, following referral by a local district general hospital. She had had a colposuspension 20 years previously and had had a tension-free vaginal tape (TVT) inserted around 10 years previously. She complained of urinary frequency, urgency, urgency incontinence, nocturia, stress urinary incontinence, recurrent urinary tract infections and pelvic organ prolapse. She had had two children by spontaneous vaginal delivery and was hypertensive.

Her three-day bladder diary showed she voided eight times in the day, twice at nights, with a reduced maximum functional capacity of 200 ml. Vaginal examination revealed a large rectocele, a well-supported uterus and no cystocele. Urodynamics revealed severe stress incontinence.

She underwent a cystoscopy with bladder biopsy, Macroplastique® (polydimethylsiloxane; Laborie, Canada), which is a urethral bulking agent for stress urinary incontinence and a posterior vaginal wall repair.

* Corresponding author.

E-mail address: george.araklitis@nhs.net (G. Araklitis).

The bladder biopsy revealed chronic inflammation and she was subsequently treated with three months of ciprofloxacin. She was happy with the result of her prolapse repair and Macroplastique but was still bothered by her overactive bladder symptoms. Subsequent ambulatory urodynamics revealed detrusor overactivity and she was treated with anticholinergic medication prior to percutaneous posterior tibial nerve stimulation (PTNS) (Urgent PC®; Laborie; Canada).

One year later she noticed vaginal spotting on her underwear after passing urine and was referred for an urgent transvaginal ultrasound scan. The uterus was normal with a thin (2 mm) endometrium. On examination she was found to have a urethral caruncle, which was deemed to be the cause of the bleeding, and she was prescribed vaginal oestrogens. A flexible cystoscopy was suggestive of cystitis glandularis at the base of the bladder neck and the urethral caruncle was noted.

Despite oestrogen therapy the bleeding persisted and she complained of increasing discomfort. At examination under anaesthesia there was no evidence of pelvic organ prolapse, the cervix was normal and cystoscopy revealed a globally inflamed urothelium with mild trabeculation. A bladder biopsy was taken and histology showed mild inflammation. A 3 cm urethral caruncle, which bled to touch, was excised and sent for histology [Fig. 1]. This showed disruptive urothelium with the underlying stroma revealing haemorrhage and relatively a well-defined area composed of foreign material (refractile but non-polarizing) with surrounding foreign-body-type multinucleate giant cell reaction. In addition there was refractile material surrounded by modified histiocytes forming multinucleate giant cells [Fig. 2]. The foreign material, which was compatible with Macroplastique®, will eventually be engulfed by these giant cells and removed, leaving fibrosis behind.

Postoperatively she had no evidence of recurrence of the caruncle and no further bleeding. She was started on low-dose ciprofloxacin for three months to treat the chronic inflammation of her bladder. Her bladder symptoms thereafter remained stable.

3. Discussion

Stress urinary incontinence is the leakage of urine under increased abdominal pressure [4]. Treatment options, following the failure of conservative therapy, include mid-urethral sling (MUS), colposuspension, autologous fascial sling and the use of urethral bulking agents (UBA), including Macroplastique, as in this case [5]. With the increased negative publicity surrounding the use of MUS and the NHS pause on vaginal mesh in 2018, the use of UBA has increased, despite it being a less

successful treatment. Macroplastique® has a success rate of 40–85% over more than two years [6], compared with an objective long-term cure rate reported with MUS of 91% [7]. Between 2004 and 2017 the number of UBA performed in England more than doubled, with a marked increase after 2018 [8] given the concerns regarding vaginal mesh.

Macroplastique is composed of a resorbed carrier, polyvinylpyrrolidone, and the permanent silicone-like elastomer, polydimethylsiloxane beads [6]. Under either local, spinal or general anaesthesia, it is injected 10–15 mm from the bladder neck at two, six and ten o'clock. The procedure may be performed using a cystoscope, para-urethrally or with the Macroplastique Implantation Device (MID)®. Whilst efficacy is lower than with traditional continence procedures the risk of adverse events is low, with catheterisation for longer than 10 days being the only common side-effect [9]. In a study in 2018 of 85 patients, there was only one reported case of voiding dysfunction, de novo overactive bladder and urethral pain [6]. The case of voiding dysfunction resolved itself spontaneously within 3 days. A separate systematic review found similarly low prevalence of mild complications, but, importantly, no evidence of migration or immune reaction related to Macroplastique® over a period of 20 years [8]. In an extensive review of the literature [10], there were no serious complications with Macroplastique® in 14 original articles with 654 patients, but there were four serious complications in the case reports. These included a complicated abscess, vaginal erosion and migration requiring vaginal surgery. Rarer complications reported include a suburethral mass, which when excised revealed refractile foreign-body material with giant cell reaction [11], as in our case. The low rate of complications, high success rate and straightforward nature of the procedure makes Macroplastique® a popular treatment option [9]. Interestingly, UBA are described as a potential risk factor for the development of urethral caruncles [3], although no other cases have been reported in the literature.

Urethral caruncles are generally asymptomatic and often diagnosed only incidentally on pelvic examination; however, they may present with bleeding, raising the suspicion of a genital tract tumour [2,12] as in this case. A caruncle may be misdiagnosed as a polyp, neoplasm, urethral diverticulum, urethrocele, skene gland cyst, sexual trauma or imperforate hymen in pre-pubertal females [3]. In a case series of 12 patients with a urethral caruncle, it took over one year for the correct diagnosis to be reached [3].

In the asymptomatic cases treatment is not necessary; patients just need education and reassurance. There remains debate over the

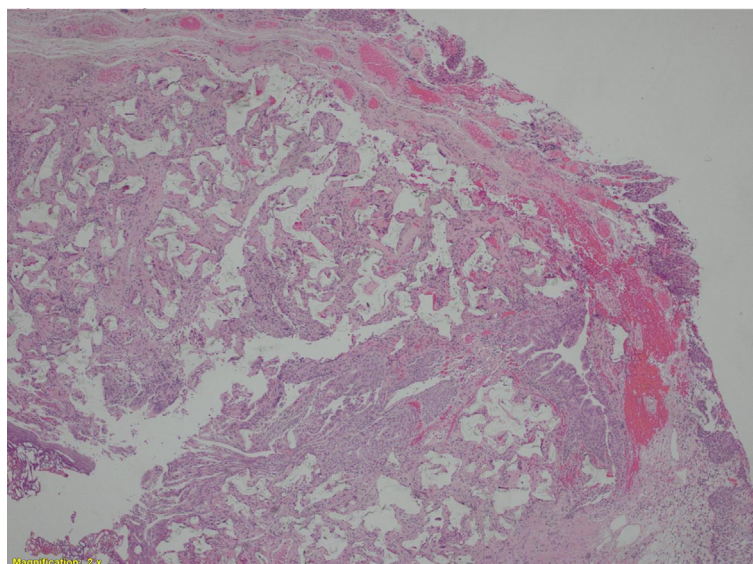


Fig. 1. \times magnification.

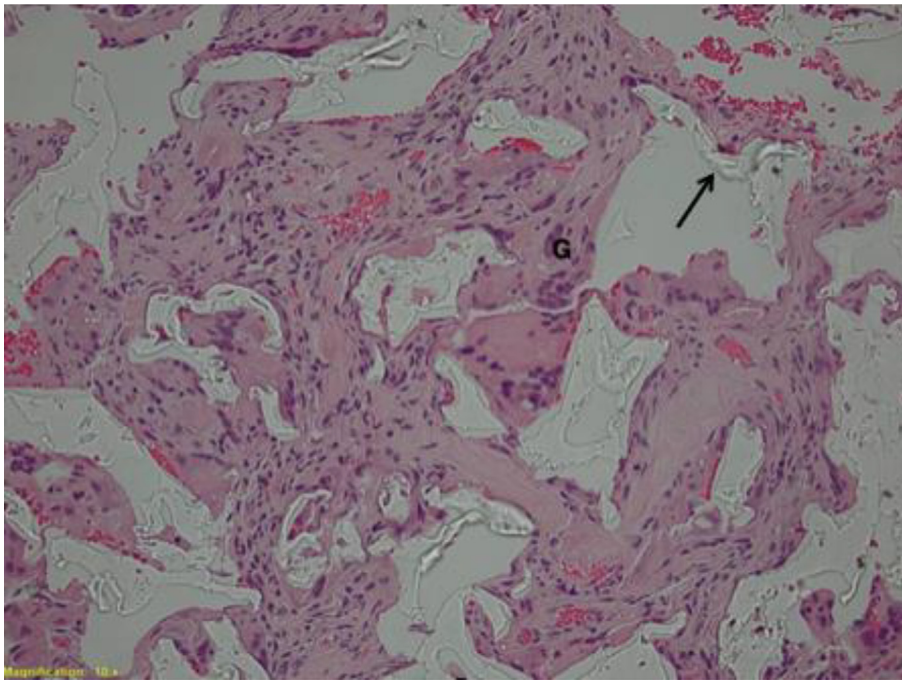


Fig. 2. 10 × magnification. Arrow points to example of foreign material. 'G' shows a multinucleate giant cell.

best treatment option for those presenting with symptoms. Topical oestrogen and anti-inflammatories are often used as a first-line treatment, with success rates of 33–92% [3], especially in the pre-pubertal group. However, this has shown recurrence in up to 67% [3], whereas excision biopsy has higher cure rates [11]. In general, surgery should be avoided where possible and this is particularly relevant in pre-pubertal girls. Cryotherapy may be seen as a compromise, but a biopsy may be needed first to obtain a histological diagnosis [13]. Excision of a caruncle may result in post-operative bleeding, urinary retention and recurrence [14]. Despite these risks, increasing evidence of a greater success rate of surgical intervention could suggest excision should be considered earlier on in treatment where appropriate. Further evidence for the argument to excise caruncles is the misdiagnosis of primary malignant melanomas of the urethra mistaken for a symptomatic urethral caruncle [15,16]. Consequently, if a caruncle fails to respond to topical oestrogen therapy, excision should be considered for both treatment and exclusion of more sinister pathology.

Urethral caruncles are generally excised using diathermy under general anaesthesia. Traction is applied to the caruncle and it is excised as close to the mucocutaneous junction as possible. Some patients may require a urethral catheter on discharge until postoperative pain settles. Other techniques include the Kelly–Burnham (or four-quadrant excisional) technique, which involves placing four stitches in the four quadrants of the prolapsed mucosa and incising each quadrant up to the mucocutaneous junction, followed by immediate approximation of the mucocutaneous junction with absorbable sutures [3]. Manual reduction under anaesthesia has also been suggested, but has a higher risk of recurrence [3].

There are no previous reported cases in of Macroplastique® being associated with a urethral caruncle. In this case, one theory is that the Macroplastique® was injected more distally than intended, although a more likely explanation may be that the urethral mucosa prolapsed out of the urethral meatus, dragging the Macroplastique® with it. The weight and mass effect of the bulking agent may have been a contributory factor. In this case, the caruncle was large, measuring about 3 cm, compared with a usual size of less than 1 cm [1]. Since the average female urethra is 3–4 cm [17] and the urethral mucosa had prolapsed

from the injection site (1 cm distal to the bladder neck), up to 3 cm distal to the urethral meatus, this represents a large urethral caruncle.

This case shows an unusual and unexpected finding at excision of a urethral caruncle. It highlights that surgical treatment of a urethral caruncle may be necessary if conservative measures fail and that the use of urethral bulking agents may be a risk factor.

Contributors

Christopher Savvas wrote the paper.

George Araklitis wrote the paper and gained patient consent.

Chirag Shah edited the paper.

Dudley Robinson generated the idea and edited the paper.

Linda Cardozo generated the idea and edited the paper.

All authors saw and approved the final version.

Conflict of Interest

The authors declare that they have no conflict of interest regarding the publication of this case report.

Funding

This research did not receive any specific grant from funding agencies in the public, commercial, or not-for-profit sectors.

Patient Consent

Obtained.

Provenance and Peer Review

Peer review was directed by Professor Margaret Rees independently of Dudley Robinson, one of the authors and Editor of *Case Reports in Women's Health*, who was blinded to the process.

References

- [1] A. Selk, Urethral Caruncle and prolapse, *Vulvar Dis.* (2019) 229–230.
- [2] V. Verma, A. Pradhan, Management of urethral caruncle—a systematic review of the current literature, *Eur. J. Obstet. Gynecol. Reprod. Biol.* 248 (2020) 5–8 (Mar 6).
- [3] A. Fornari, M. Gressler, J. Murari, Urethral prolapse: a case series and literature review, *J. Obstet. Gynecol. India* 70 (2) (2019) 158–162.
- [4] B.T. Haylen, D. De Ridder, R.M. Freeman, S.E. Swift, B. Berghmans, J. Lee, A. Monga, E. Petri, D.E. Rizk, P.K. Sand, G.N. Schaer, An international Urogynecological association (IUGA)/international continence society (ICS) joint report on the terminology for female pelvic floor dysfunction, *Neurourol. Urodyn.* 29 (1) (2010 Jan) 4–20.
- [5] Recommendations | Urinary Incontinence and Pelvic Organ Prolapse in Women: Management | Guidance | NICE [Internet], *Nice.org.uk* 2020 , [cited 14 October 2020]. Available from <https://www.nice.org.uk/guidance/ng123/chapter/Recommendations>.
- [6] D. Rodríguez, T. Carroll, F. Alhalabi, M. Carmel, P. Zimmern, Outcomes of Macroplastique injections for stress urinary incontinence after suburethral sling removal, *Neurourol. Urodyn.* 39 (3) (2020) 994–1001.
- [7] C.G. Nilsson, K. Palva, R. Aarnio, E. Morcos, C. Falconer, Seventeen years' follow-up of the tension-free vaginal tape procedure for female stress urinary incontinence, *Int. Urogynecol. J.* 24 (8) (2013 Aug 1) 1265–1269.
- [8] M.M. Zacche, S. Mukhopadhyay, I. Giarenis, Changing surgical trends for female stress urinary incontinence in England, *Int. Urogynecol. J.* 30 (2) (2019 Feb) 203–209.
- [9] Stress Urinary Incontinence Surgery in the UK 2008–2017. 1st National Report. BSUG Audit and Database Committee 2018.
- [10] A. de Vries, H. Wadhwa, J. Huang, F. Farag, J. Heesakkers, E. Kocjancic, Complications of urethral bulking agents for stress urinary incontinence, *Female Pelvic Med. Reconstr. Surg.* 24 (6) (2018) 392–398.
- [11] E.J. Wasenda, C.W. Nager, Suburethral mass formation after injection of polydimethylsiloxane (Macroplastique) urethral bulking agent, *Int. Urogynecol. J.* 27 (12) (2016 Dec 1) 1935.
- [12] K. Sonoda, R. Kato, H. Kojima, Y. Tokuda, Urinary tract bleeding from a urethral caruncle mimicking genital tract bleeding, *BMJ Case Rep.* 12 (2) (2019), e225540.
- [13] E. Cimentepe, Ö. Bayrak, A. Ünsal, A. Koç, Ö. Ataoğlu, M.D. Balbay, Urethral adenocarcinoma mimicking urethral caruncle, *Int. Urogynecol. J.* 17 (1) (2006 Jan 1) 96–98.
- [14] M. Hall, T. Oyesanya, A. Cameron, Results of surgical excision of urethral prolapse in symptomatic patients, *Neurourol. Urodyn.* 36 (8) (2017) 2049–2055.
- [15] N. Bansal, G. Garg, S. Vashist, Primary Malignant Melanoma of Urethra Mimicking as Urethral Caruncle, 2020.
- [16] A. Safadi, S. Schwalb, I. Ben-Shachar, R. Katz, Primary Malignant Urethral Melanoma Resembling a Urethral Caruncle, 2020.
- [17] B. Abelson, D. Sun, L. Que, R. Nebel, D. Baker, P. Popiel, et al., Sex differences in lower urinary tract biology and physiology, *Biol. Sex Differ.* 9 (1) (2018).