

Acute flank abdominal pain as the chief complaint of spontaneous adrenal hemorrhage secondary to metastatic lung cancer

Hu Han ¹, Peng Qiao ¹, Xue-wei Jiang, Biao Wang ^{*}, Xiao-dong Zhang

Department of Urology, Beijing Chao-Yang Hospital, Capital Medical University, Gong Ti Nan Lu 8, Chaoyang District, 100020, Beijing, China



ARTICLE INFO

Article history:

Received 27 August 2017
Received in revised form
3 October 2017
Accepted 5 October 2017
Available online 13 November 2017

Keywords:

Adrenal tumor
Adrenal hemorrhage
Metastasis
Lung cancer

1. Introduction

Compared to the frequent occurrence of metastatic tumors of the adrenal glands in autopsy reports, it is rare in clinic.¹ Adrenal gland metastases hemorrhages are exceedingly rare in clinic and difficult to diagnose by non-specific symptoms.^{1–3}

To our knowledge, the number of the case reports in spontaneous adrenal hemorrhage secondary to metastatic lung carcinoma is only 28 by the end of 2014.² We present one case in which patient was admitted in our medical center as flank acute abdominal pain.

2. Case presentation

A 51-year-old male asymptotically discovered a mass, approximately 5 cm in diameter, at the left adrenal area 10 days ago (Fig. 1a and b). After 4 days, he presented to the emergency department as acute left flank abdominal pain. He did not have a history of trauma. The enhanced CT scan demonstrated that space-occupying lesions with effusion around the left adrenal, including the possibility of hematoma (Fig. 1c and d). Left spontaneous

hemorrhage secondary was considered. An X-ray chest film showed pleural effusion in left side and no distinct pulmonary lesion. The patient smoked for 20 years uninterruptedly, and was diagnosed as psoriasis 10 years ago. Examination revealed poor general situation and painful face, left abdominal tenderness without rebound pain and tension, and percussion pain at the left renal area.

Laparoscopic left adrenalectomy was essential in this situation, the hemoglobin fell sharply to 70 g/L. The strong adhesions between the splenic hilum and the mass increased the difficulty in separating, so it was shifted to the open surgery. During the operation, 4U red blood cell and 200ml plasma were used, and the mass, 12 × 8 cm in size, was removed completely (Fig. 2a–c). After his discharge from our hospital, pathology demonstrated most parts of the left adrenal was full of necrotic tissue, the residual adrenal gland was on the margin with necrosis, and significant heterogeneous cells crowded in the middle, larger, rich cytoplasm, numerous mitoses (Fig. 2d), and immunohistochemistry showed CK (+), VIMENTIN (+), TIF-1 (+). Combining these two investigations, most likely poorly differential lung cancer was the origin of the mass.

In one month after surgery, the patient developed abdominal pain necessitating emergency admission, and abdominal enhanced CT indicated masses on the left adrenal area, 11.2 × 7.3 cm in size, considered space-occupying lesions, and local bleeding probably, may well be greater than the preoperative progress (Fig. 3). After admission, he received anti-inflammatory, rehydration, blood transfusion, analgesic and other treatments. Meanwhile PET examination revealed that lumps on the left adrenal area, mediastinum, and right upper lobe, uneven density with increased metabolism, were considered malignant lesions, and left lung hilar and jaw lymph nodes with metabolic enhancement. Biochemical tests showed that lactate dehydrogenase, α -hydroxybutyrate dehydrogenase, alkaline phosphatase increased significantly, but albumin decreased significantly, hemoglobin was 80g/L, serum sodium maintained at 120 mmol/L (137–147 mmol/L), potassium was at normal level. In spite of sodium supplement treatment, serum sodium levels are difficult to rise. Because the patient began to decline in appetite, weakness, vomiting, weight loss and chest tightness, pathological diagnosis of lung cancer wasn't performed for his dreadful condition. After conservative treatments, his condition deteriorated rapidly and respiratory failure occurred, causing

^{*} Corresponding author.

E-mail address: wangbiao6176@sina.com (B. Wang).

¹ Hu Han and Peng Qiao are equal to contribution to this paper.

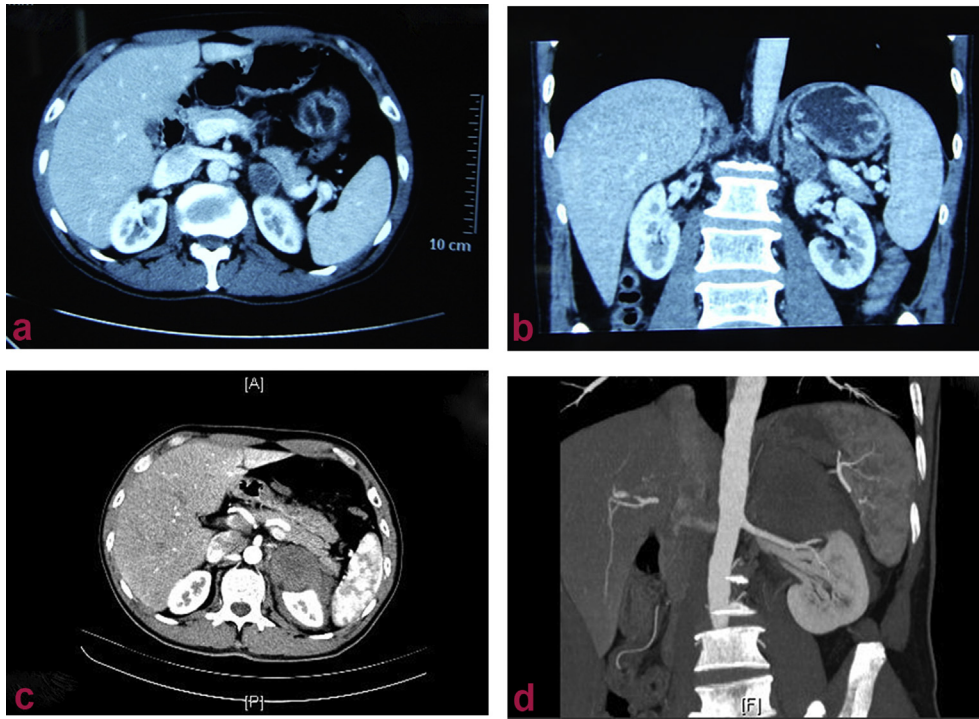


Fig. 1. CT scan of the abdomen was noted. (a), (b) CT scan indicated left adrenal mass by physical examination. (c), (d) CT scan demonstrated that space-occupying lesions with effusion around the left adrenal, including the possibility of hematoma after acute left flank abdominal pain.

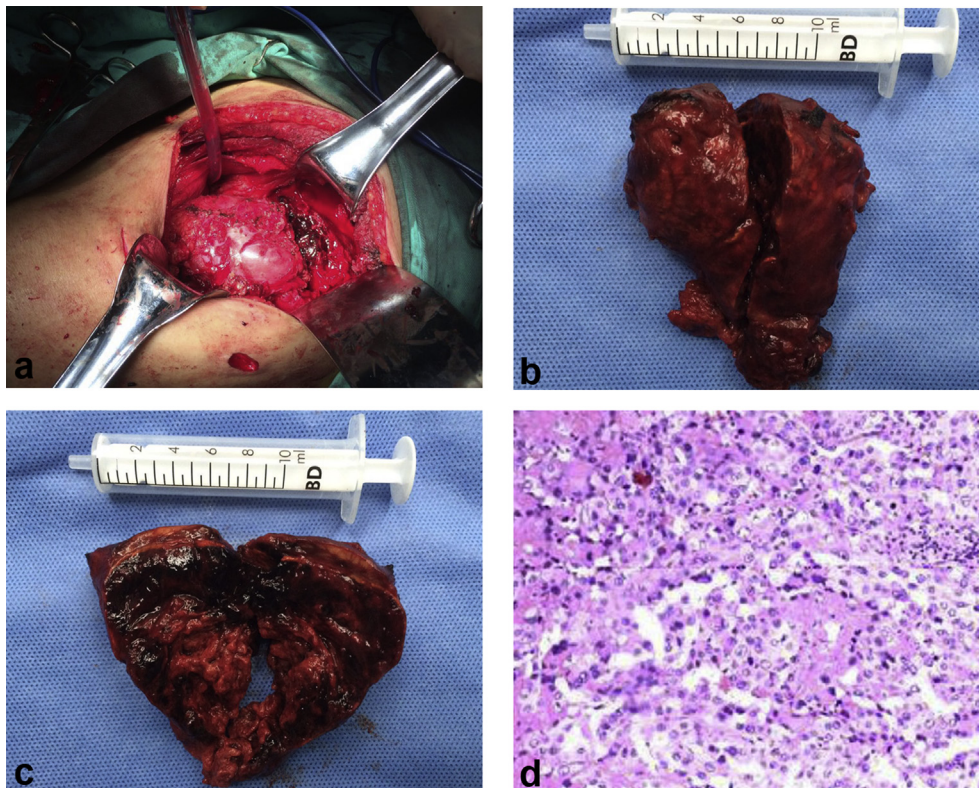


Fig. 2. Gross specimen and microscopic structure on the left adrenal tumor.

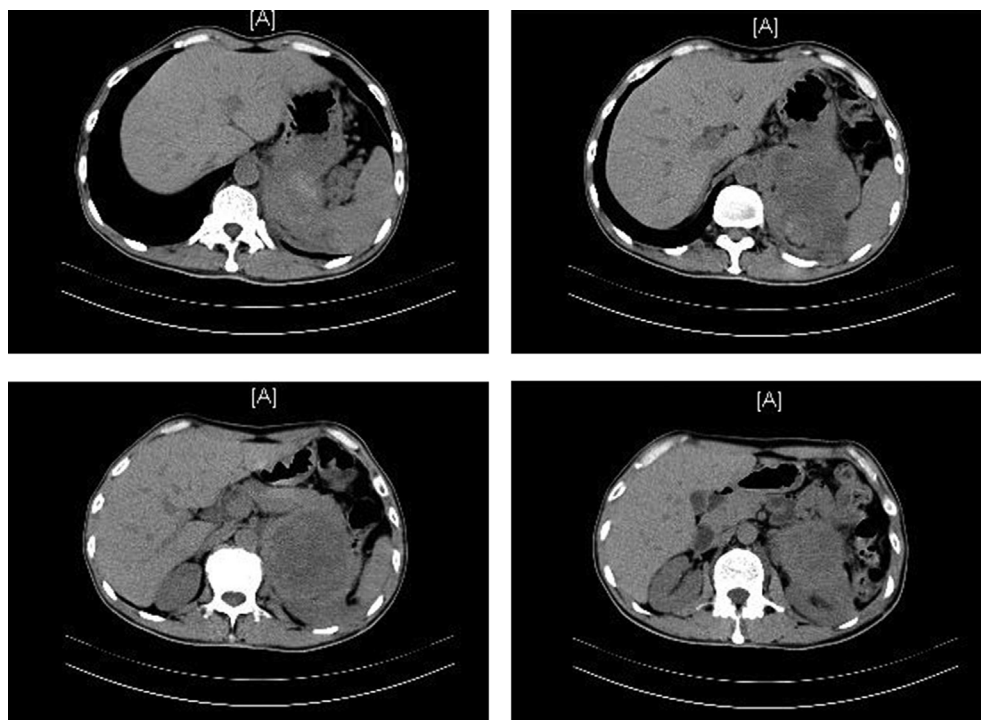


Fig. 3. CT scan indicated masses on the left adrenal area in one month after surgery.

his death on the 105th day in the whole management.

3. Discussion

Adrenal gland metastases were mainly from the lung, followed by the kidney, the breast, the gastrointestinal tract. In Hong Kong, lung and gastric area were the most common primary sites, however in China they were principally derived from renal cell carcinoma, non-small cell lung carcinoma and hepatocellular carcinoma.^{1,3,4}

In etiology of adrenal hemorrhage secondary to metastatic lung cancer, mainly included adenocarcinoma, large-cell carcinoma, squamous cell carcinoma, adenosquamous carcinoma, small-cell carcinoma. The presentations are various, including pain, anemia, nausea, vomiting, fatigue, weakness, hypotension, palpable mass, and flank ecchymoses.⁵

Adrenal hemorrhage occurs after the diagnosis or resection of lung cancer.^{2,5} Uniquely, it was the first clinical performance in our case, and then the CT or PET further confirmed pulmonary carcinoma according to the pathologic results of adrenal tumors, poorly differentiated carcinoma from lung. Especially, no lumps were found by chest X-ray before surgery, suggesting that the primary lesions were small and hidden with high degree of malignancy. Once the adrenal metastases hemorrhage arouses clinical manifestations, prognosis is poor and mortality is high.

It's worth noting that the patient presented the indifferent, nausea, and vomiting result from when he was re-admitted to the hospital. We analyzed that the adrenal cortical dysfunction, related to adrenal metastases, led to refractory hyponatremia, and contralateral adrenal cortical function was depleted for compensation, causing complicated by Addison's disease. Common etiologies of Addison's disease are: adrenal metastases and tuberculosis in Hong Kong.¹

The therapies of adrenal metastases consist of surgery, conservative treatment, analgesic, blood transfusion, steroid pulse,

chemotherapy, arterial embolism and other methods.^{1,2,4,5} Surgery is reported that can slightly elevate the survival rate.^{1,4} Laparoscopy should be chosen carefully on account of adhesion, caused by hemorrhage.

The patient survived for 105 days after diagnosis, suggesting this type of metastasis has a high degree of malignancy, and limited treatments can lead to sudden death, consistent with the literature.⁵ It is reported in some literatures that the average survival time is 3 months (0–75 months) after diagnosis as adrenal metastases, and surgical resection of adrenal metastases can extend the median survival period to 8 months or 24 month.^{1,4}

4. Conclusion

In our case, primary pulmonary carcinoma was too small to realize until it spread to the adrenal gland, and it had reached an advanced stage. Therefore, patients with acute flank abdominal pain as the chief of adrenal hemorrhage are recommend early lung CT or PET for early detection of primary lung lesions, timely identification of pathological diagnosis, early treatment of primary tumors, and extending the lifetime. Patients and his family should be informed in advance of the high mortality and the poor prognosis of these diseases.

Conflicts of interest

All authors have no conflicts of interest.

Appendix A. Supplementary data

Supplementary data related to this article can be found at <https://doi.org/10.1016/j.eucr.2017.10.007>.

References

1. Lam KY, Lo CY. Metastatic tumors of the adrenal glands: a 30-year experience in

- a teaching hospital. *ClinEndocrinol (Oxf)*. 2002;56:95–101.
2. Wang J, Packer CD. Acute abdominal pain after intercourse: adrenal hemorrhage as the first sign of metastatic lung cancer. *Case Rep Med*. 2014;2014, 612036.
 3. Hiroi N, Yanagisawa R, Yoshida-Hiroi M, et al. Retroperitoneal hemorrhage due to bilateral adrenal metastases from lung adenocarcinoma. *J Endocrinol Invest*. 2006;29:551–554.
 4. Ma X, Li H, Zhang X, et al. Modified anatomical retroperitoneoscopic adrenalectomy for adrenal metastatic tumor: technique and survival analysis. *Surg Endosc*. 2013;27:992–999.
 5. Oo TH, Martin L, Hesketh PJ. Adrenal hemorrhage secondary to metastasis from lung cancer. *Clin Lung Cancer*. 2002;4:183–185.