


Treatment of unexplained coma and hypokinetic-rigid syndrome in a patient with COVID-19

Devjit Roy ^{1,2}, Justin Song,² Nirvana Awad,¹ Paul Zamudio¹

¹Department of Medicine, Montefiore Nyack Hospital, Nyack, NY, USA

²Department of Medicine, Albert Einstein - College of Medicine, Bronx, NY, USA

Correspondence to

Dr Devjit Roy;
devjit.roy@gmail.com

Accepted 21 January 2021

SUMMARY

The COVID-19 pandemic has dealt a devastating blow to healthcare systems globally. Approximately 3.2% of patients infected with COVID-19 require invasive ventilation during the course of the illness. Within this population, 25% of patients are affected with neurological manifestations. Among those who are affected by severe neurological manifestations, some may have acute cerebrovascular complications (5%), impaired consciousness (15%) or exhibit skeletal muscle hypokinesia (20%). The cause of the severe cognitive impairment and hypokinesia is unknown at this time. Potential causes include COVID-19 viral encephalopathy, toxic metabolic encephalopathy, post-intensive care unit syndrome and cerebrovascular pathology. We present a case of a 60 year old patient who sustained a prolonged hospitalization with COVID-19, had a cerebrovascular event and developed a persistent unexplained encephalopathy along with a hypokinetic state. He was treated successfully with modafinil and carbidopa/levodopa showing clinical improvement within 3–7 days and ultimately was able to successfully discharge home.

BACKGROUND

In late 2019, a novel coronavirus known as SARS-CoV-2 was identified as the cause of a cluster of viral pneumonia cases. Infection with this virus results in COVID-19, a disease which was classified as a global pandemic in February 2020.¹ COVID-19 has resulted in over 1.5 million deaths globally.² Inpatient healthcare providers have experienced major challenges working with patients suffering from COVID-19 due to the varying degree of severity and unpredictability of the disease course, especially across different populations.³ The disease process is associated with numerous clinical complications including a hyperinflammatory state, severe pneumonia requiring mechanical ventilation, coagulopathy, and notably, significant neurological and cognitive impairment.⁴

Numerous clinical symptoms suggest neurological involvement in the pathogenesis of COVID-19.⁵ These include headaches, nausea, vomiting, myalgia, encephalopathy, ataxia, acute cerebrovascular disease, seizures, hypoxaemia and impaired consciousness.⁶ There has been no literature to date describing the neurophysiological cognitive state and treatment of these patients, particularly in the post-intensive care unit (ICU) setting.

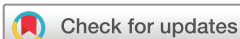One noteworthy neurological complication from COVID-19 is impaired consciousness, associated with a prolonged hypokinetic state.⁷

⁸ The coagulopathy seen in COVID-19 patients may contribute to this altered consciousness by causing cerebrovascular disease. Despite routine use of venous thromboembolism (VTE) prophylaxis, some patients suffer from VTEs and acute ischaemic strokes over the course of their disease.⁹ COVID-19 patients who enter the ICU are also at risk for post-ICU syndrome in which patients suffer from ventilator asynchrony.¹⁰ As a result, they require high doses of intravenous sedatives and the use of neuromuscular blockers for an extended duration. The combination of VTE complications, as well as extended ventilator days, has resulted in prolonged minimally conscious states in many patients with a severe form of the disease.

We propose that this cohort of patients has developed depleted dopamine stores in the brain resulting in preserved consciousness, tremors and intact eye movements. Pharmacodynamic approaches to dopaminergic stimulation in patients with depleted dopamine stores include reversing the disruption in the presynaptic biosynthesis of dopamine via the administration of L-dopa.¹¹ Additionally, the American Academy of Neurology recommends the use of 100–200 mg of amantadine twice daily to hasten functional recovery and reduce the degree of disability between 4 and 16 weeks postinjury based on the results of a randomised, placebo-controlled study.^{12–15} Neurostimulant medications, such as carbidopa-levodopa (sinemet), amantadine and modafinil, have all been shown to improve and accelerate functional recovery and sleep-wake cycles following an acute stroke or total brain injury in patients with depleted dopamine stores.^{16–19} We; therefore, present a case describing the clinical course of a patient infected with COVID-19 who was treated with a combination of 25–100 mg of carbidopa-levodopa three times a day and 200 mg of modafinil daily in the post-ICU, rehabilitation setting. This neurological resuscitation protocol proved successful in waking up this patient and improved cognition, function and movement. Due to the lack of literature regarding this medication treatment in patients with COVID-19, informed consent was obtained for this case.

CASE PRESENTATION

A 60-year-old man with a history of hypertension, diabetes and hypercholesterolaemia presented to the emergency department for worsening shortness of breath. Subjective and objective data lead



© BMJ Publishing Group Limited 2021. No commercial re-use. See rights and permissions. Published by BMJ.

To cite: Roy D, Song J, Awad N, et al. *BMJ Case Rep* 2021;**14**:e239781. doi:10.1136/bcr-2020-239781

to the preliminary diagnosis of bilateral pneumonia, being COVID-19 positive and soon thereafter developed acute hypoxic respiratory failure. As the patient's clinical condition began to deteriorate in the early days of the hospital stay, the patient was intubated, which led to transfer to the ICU. This patient had a prolonged ICU course complicated by septic shock, ventricular tachycardia and acute renal failure requiring haemodialysis. The patient was treated with convalescent plasma during the ICU course on day 8. Weaning trials off of the ventilator were started, but the patient was unable to be weaned due to critical illness, hypokinetic-rigid state and poor mental status. On day 30, despite all weaning attempts, he underwent a tracheostomy with percutaneous endoscopic gastrostomy (PEG) tube placement due to prolonged mechanical ventilation. He continued to remain in the ICU, with continued poor mental status and functional status. As a result of this continued poor neurological status, the patient underwent a MRI scan, which showed a basal ganglia and corona radiata stroke. These were both thought to be secondary to COVID-induced coagulopathy.

On day 35, all of his sedating medications were appropriately weaned and discontinued. He remained clinically stable, throughout the rest of the ICU stay and was transferred out of the ICU on day 41 to a step-down unit. Physical, occupational and speech therapy were started once out of the ICU, but due to having continued unexplained encephalopathy and functional quadriplegia he was unable to participate. He continued to be unweanable from his ventilator due to his poor mental status.

On day 47, after consent was obtained from the patient's healthcare proxy, he was started on 25–100 mg of carbidopa–levodopa three times a day and 200 mg of modafinil in the morning. On day 49, he was awake, alert and able to slowly move the right side of his body. Due to complications of stroke, the patient continued to have left-sided hemiparesis, but he was participating with physical, occupational, and speech therapy. On day 50, he was able to move the right side of his body with more purpose and strength, while also attempting to speak. The patient was not previously weaned off of the ventilator because of his mental status, but began weaning on day 52 as he improved. This patient remained in the hospital because he developed a pneumothorax on day 54 as well as ventilator-associated pneumonia on day 58. Weaning attempts from the ventilator were then suspended, and carbidopa–levodopa along with modafinil were withheld during this time, as the patient was having a decline. The patient's wakefulness did seem to worsen during this time, along with paucity of movement.

Once the pneumothorax resolved on day 60, and chest tube was removed, the patient was restarted on the 'wake-up' regimen, and within 2 days his movement and wakefulness began to improve. He was again restarted on ventilator weaning, which he was able to tolerate. On day 64–70, he continued to participate with physical and occupational therapy, and although he did develop a ventilator associated pneumonia, he continued to improve and get stronger. On day 74, he was able to be discharged to acute rehabilitation while on the carbidopa–levodopa regimen. He was able to have more intensive physical therapy and occupational therapy, and was able to complete his course of antibiotics. During the rehabilitation stay, he was able to be fully weaned off of the ventilator, and began eating more on his own; his tracheostomy was able to be removed, and as he was keeping up with his nutritional needs, his PEG tube was also removed. At the acute rehabilitation

centre, he began walking with a walker, and on day 90 his modafinil and carbidopa/levodopa regimen was stopped. He continues to maintain wakefulness, alertness and is sustaining movement. The patient was set to discharge to home from the acute rehab within the next month, and ultimately discharged to home.

TREATMENT

The main treatment used was the combination therapy of modafinil 200 mg in the morning, and carbidopa/levodopa 25/100 mg three times a day. The treatment was stopped after 30 days for the case described, so as to minimise complications and side effects from the medication. The modafinil was thought to help reset sleep/wake cycles, and maintain wakefulness along with the ability to participate in day-to-day therapy sessions. The carbidopa/levodopa was thought to have helped with dopamine depletion, which may have been causing the hypokinesia of skeletal muscle.

OUTCOME AND FOLLOW-UP

During the extended hospital stay, the patient in this case report was started on our 'wake-up' protocol: 25–100 mg of carbidopa–levodopa three times a day and 200 mg of modafinil every morning. Since there is not any current protocol for neurological resuscitation for COVID-19 patients, the rationale behind these doses were to use parallel diseases (impaired sleep and parkinsonism) as a reference point. The objective of this intervention was to improve mental status and alertness and to enable the patients to awaken on their own and become more arousable. It was also important to see that the patient could follow commands consistently, such as squeezing an examiner's hand or being able to give a 'thumbs up'. When sedating medications were discontinued before the start of the intervention, the typical physical examination consisted of very minimal neurological responses, scarcity of movement and severe lethargy. By day 2 or 3 of the carbidopa–levodopa and modafinil combination regimen, the patient began to show increased alertness and wakefulness for increased amounts of time. During the first week of the treatment, he was able to communicate meaningfully and demonstrated increased mobility of his upper limbs. The duration of treatment was chosen to be a total of 30 days so as to minimise any short and long-term side effects associated with both carbidopa–levodopa and modafinil. When the patient was medically stable for discharge to acute rehabilitation, he was continued on the regimen to continue to help with physical and occupational therapy. Follow-up phone calls revealed continued improvement, and ultimate weaning off of the tracheostomy, and ability to feed himself, and ambulate. The patient was able to discharge to home after 30 days at the acute rehabilitation centre.

DISCUSSION

COVID-19-related encephalopathy is a formidable problem to solve because there is no clear and effective treatment to help patients with this disorder. Many patients fall into a 'locked in'/parkinsonian state following COVID-19 infection. This case report demonstrates that a medication regimen featuring carbidopa–levodopa and modafinil may be an effective means of neurological resuscitation. Improved consciousness and cognitive function are associated with the use of carbidopa–levodopa following traumatic brain injury,^{16 17} the mechanism of which is believed to be due to replenishment of depleted

dopamine stores in striatal neurons.^{16 17} In patients with brain injury, modafinil enhanced cognition and restored patients' sleep-wake cycles by means of blocking inhibiting dopamine and norepinephrine transporters and decreasing GABA-mediated neurotransmission.^{18–21}

The patient in our hospital setting who suffered from COVID-19 infection and its neurological sequelae showed neurological improvement with the 'wake-up' protocol drug regimen. This is an important finding which could decrease the need for invasive procedures such as tracheostomy and PEG placement, as well as decrease the length of long term ventilation in 'long-haul' COVID-19 patients. As a result, patients' morbidity and mortality may improve. When started the 'wake-up' protocol, the patient we followed showed increased alertness, ability to communicate and capacity to follow commands. He was able to partake in physical, occupational and speech therapy, furthering his chances of meaningful recovery. No major side effects for either carbidopa-levodopa or modafinil were observed during the treatment period.

Due to the paucity of published studies on COVID-19-related neurological issues and treatments, no protocols or guidelines could be used to aid in our data collection and interpretation. Larger non-randomised studies would be able to take into consideration gender, race, comorbidities and severity of illness, treatments or other factors. We performed this case report to obtain information for future studies.

In summary, we report that carbidopa-levodopa in combination with modafinil may be an effective treatment regimen for COVID-19-related neurological dysfunction. This case report highlights the positive influence of neurostimulants following COVID-19 infection complicated by neurological sequelae. Further studies are warranted to examine the effectiveness of carbidopa-levodopa and modafinil or possibly

amantadine-modafinil in patients with COVID-19-related encephalopathy or comatose state.

Acknowledgements Anupama Kurra—author and psychiatry physician who helped with the clinical functional assessments of patients on the treatment regimen. She also authored, edited, and helped with literature review. Andrew Erian—author and neurologist who also helped with clinical neurological examination of patients on the treatment. He also helped with authoring, editing and literature review. They also were a part of the clinical team who helped to treat the patients discussed in this case report. They each authored and helped to edit this paper, and each section. Due to requirements of case report submission, their names were not able to be added.

Contributors DR: primary author, investigator and hospitalist who developed the treatment regimen of modafinil and carbidopa/levodopa and initiated the treatment on the patients. PZ: author, who is also the treating intensivist, who also used the treatment regimen on COVID-19 patients. In addition to authoring, he helped with literature review. NA: author and pharmacist helping with dosing on the case, as well as literature review. JS: author and medical student, who helped compiling the whole case, and helping during the submission process.

Funding The authors have not declared a specific grant for this research from any funding agency in the public, commercial or not-for-profit sectors.

Competing interests None declared.

Patient consent for publication Next of kin consent obtained.

Provenance and peer review Not commissioned; externally peer reviewed.

ORCID iD

Devjit Roy <http://orcid.org/0000-0002-3263-2083>

REFERENCES

- Meng L, Qiu H, Wan L, Li Wan YA, *et al.* Intubation and ventilation amid the COVID-19 outbreak: Wuhan's experience. *Anesthesiology* 2020;132:1317–32.
- Johns Hopkins coronavirus resource center. Available: <https://coronavirus.jhu.edu/map.html>
- Goyal P, Choi JJ, Pinheiro LC, *et al.* Clinical characteristics of Covid-19 in New York City. *N Engl J Med* 2020;382:2372–4.
- Li X, Xu S, Yu M, *et al.* Risk factors for severity and mortality in adult COVID-19 inpatients in Wuhan. *J Allergy Clin Immunol* 2020;146:110–8.
- Asadi-Pooya AA, Simani L. Central nervous system manifestations of COVID-19: a systematic review. *J Neurol Sci* 2020;413:116832.
- Divani AA, Andalib S, Di Napoli M, *et al.* Coronavirus disease 2019 and stroke: clinical manifestations and pathophysiological insights. *J Stroke Cerebrovasc Dis* 2020;29:104941.
- Mao L, Wang M, Chen S, *et al.* Neurological manifestations of hospitalized patients with COVID-19 in Wuhan, China: a retrospective case series study. *SSRN Journal*.
- Li Y-C, Bai W-Z, Hashikawa T. The neuroinvasive potential of SARS-CoV2 may play a role in the respiratory failure of COVID-19 patients. *J Med Virol* 2020;92:552–5.
- Iba T, Levy JH, Levi M, *et al.* Coagulopathy of coronavirus disease 2019. *Crit Care Med* 2020
- Rawal G, Yadav S, Kumar R. Post-intensive care syndrome: an overview. *J Transl Int Med* 2017;5:90–2.
- Fridman EA, Osborne JR, Mozley PD, *et al.* Presynaptic dopamine deficit in minimally conscious state patients following traumatic brain injury. *Brain* 2019;142:1887–93.
- Giacino JT, Katz DI, Schiff ND, *et al.* Practice guideline update recommendations summary: disorders of consciousness: report of the Guideline development, Dissemination, and Implementation Subcommittee of the American Academy of Neurology; the American Congress of rehabilitation medicine; and the National Institute on disability, independent living, and rehabilitation research. *Neurology* 2018;91:450–60.
- Giacino JT, Whyte J, Bagiella E, *et al.* Placebo-controlled trial of amantadine for severe traumatic brain injury. *N Engl J Med* 2012;366:819–26.
- Barra ME, Izzy S, Sarro-Schwartz A, *et al.* Stimulant therapy in acute traumatic brain injury: prescribing patterns and adverse event rates at 2 level 1 trauma centers. *J Intensive Care Med* 2020;35:1196–202.
- Leclerc AM, Riker RR, Brown CS, *et al.* Amantadine and modafinil as neurostimulants following acute stroke: a retrospective study of intensive care unit patients. *Neurocrit Care* 2020. doi:10.1007/s12028-020-00986-4. [Epub ahead of print: 20 May 2020].
- Haig AJ, Ruess JM. Recovery from vegetative state of six months' duration associated with Sinemet (levodopa/carbidopa). *Arch Phys Med Rehabil* 1990;71:1081–3.
- Krimchansky B-Z, Keren O, Sazbon L, *et al.* Differential time and related appearance of signs, indicating improvement in the state of consciousness in vegetative state traumatic brain injury (VS-TBI) patients after initiation of dopamine treatment. *Brain Inj* 2004;18:1099–105.

Patient's perspective

I am just so happy that these medications were tried. Everyone was telling me that my husband did not have a chance, and that I needed to think about hospice. I just couldn't and needed to make sure that I did everything that I could. This virus is a horrible thing. Everyone needs to know about this treatment, so we can help others. Thank you. Priscilla (wife)

Learning points

- ▶ COVID-19 encephalopathy and hypokinetic rigid syndrome occurs in patients who have contracted COVID-19, and have had prolonged intensive care unit (ICU) stays.
- ▶ These patient's unfortunately develop a neurological complication that prevents the patient from healing from this disease.
- ▶ By using modafinil 200 mg, we were able to help reset patient's sleep-wake cycles, to prevent ICU delirium and improve wakefulness and alertness during the post-ICU stay.
- ▶ By using carbidopa/levodopa, we were able to help fix the hypokinetic rigid syndrome, which was making it difficult to participate in physical therapy and rehabilitation
- ▶ By using this regimen, and minimising the comorbidity of poor neurological state during the course of their COVID-19 illness, patients may be able to make faster recoveries, and ultimately be weaned off of ventilators sooner.

- 18 Dhamapurkar SK, Wilson BA, Rose A, *et al*. Does modafinil improve the level of consciousness for people with a prolonged disorder of consciousness? A retrospective pilot study. *Disabil Rehabil* 2017;39:2633–9.
- 19 Mo Y, Thomas MC, Miano TA, *et al*. Effect of modafinil on cognitive function in intensive care unit patients: a retrospective cohort study. *J Clin Pharmacol* 2018;58:152–7.
- 20 Matsuda W, Komatsu Y, Yanaka K, *et al*. Levodopa treatment for patients in persistent vegetative or minimally conscious states. *Neuropsychol Rehabil* 2005;15:414–27.
- 21 Wolf AP, Gleckman AD. Sinemet and brain injury: functional versus statistical change and suggestions for future research designs. *Brain Inj* 1995;9:487–93.

Copyright 2021 BMJ Publishing Group. All rights reserved. For permission to reuse any of this content visit <https://www.bmj.com/company/products-services/rights-and-licensing/permissions/>
BMJ Case Report Fellows may re-use this article for personal use and teaching without any further permission.

Become a Fellow of BMJ Case Reports today and you can:

- ▶ Submit as many cases as you like
- ▶ Enjoy fast sympathetic peer review and rapid publication of accepted articles
- ▶ Access all the published articles
- ▶ Re-use any of the published material for personal use and teaching without further permission

Customer Service

If you have any further queries about your subscription, please contact our customer services team on +44 (0) 207111 1105 or via email at support@bmj.com.

Visit casereports.bmj.com for more articles like this and to become a Fellow