



# Paclitaxel-coated balloons angioplasties for extra-long femoropopliteal artery atherosclerotic lesions (> 30 cm):12 months outcomes from a single center

Tao Pan, Guodong Zhang, Zhen Liu, Tao Zhang, Cheng Li, Donghua Ji\*

The Interventional Therapy Department of the First Affiliated Hospital of Dalian Medical University, Dalian, 116011, China

## ARTICLE INFO

### Keywords:

Femoropopliteal artery  
Extra-long lesion  
Paclitaxel-coated balloon

## ABSTRACT

**Objective:** To evaluate the efficacy of paclitaxel-coated balloon (PCB) in the treatment of extra-long femoropopliteal artery atherosclerotic disease (>30 cm).

**Materials and methods:** Forty-nine patients with extra-long femoropopliteal artery atherosclerotic disease were treated with PCB alone in a single center from July 2016 to May 2018. Primary patency and freedom from clinically driven target lesion revascularization (FF-CDTLR) rates during 12 months were analyzed retrospectively.

**Results:** All patients were followed up for  $18.2 \pm 7.5$  months, and the mean treated lesion length was  $34.9 \pm 3.7$  cm. The primary patency rates were 87.8% (43/49) and 71.4% (35/49) at 6 and 12 months, respectively. FF-CDTLR was 91.8% (45/49) and 77.6% (38/49) at 6 and 12 months, respectively. No mortality or amputation occurred in these patients during the follow-up period.

**Conclusions:** PCB has favorable clinical efficacy in patients with extra-long femoropopliteal artery atherosclerotic lesions.

## 1. Introduction

Numerous clinical studies evaluating the use of percutaneous transluminal angioplasty (PTA) for the treatment of peripheral arterial disease have been published in the literature. The restenosis rates noted in these studies were as high as 40%–60% at 6–12 months. Treatment with paclitaxel-coated balloons (PCBs) has resulted in a significantly higher primary patency rate at 6–12 months when compared with conventional PTA (82.2% vs. 52.4%). The rates of improved freedom from target lesion revascularization (TLR) for PCBs have been remarkable with increased primary patency over time.<sup>1–7</sup> PCBs have been shown to be a safe and effective therapy for atherosclerotic disease in femoropopliteal lesions, with stent placement limited to bailout indications. Stent placement cross over the knee joint may be associated with potential negative consequences such as stent fracture, etc.<sup>8–10</sup> However, most published trials of treatment with PCBs have only included relatively simple and short lesions.<sup>1–6</sup> For some challenging lesions, especially for extra-long femoropopliteal lesions, treatment with PCBs is limited in the literature. In helping effective clinical decision making for such patients, this retrospective study was conducted to evaluate the safety and

effectiveness of PCB angioplasty in the treatment of extra-long femoropopliteal artery atherosclerotic disease (>30 cm).

## 2. Materials and methods

### 2.1. Subjects

A retrospective analysis of patients who underwent PCBs angioplasty for extra-long femoropopliteal artery atherosclerotic lesions (defined as de novo atherosclerotic lesions measuring >30 cm) was conducted at a single center between July 2016 and May 2018. No formal inclusion criteria were applied, and the exclusion criteria were patients in whom self-expanding nitinol stents were used as a bailout procedure in case of flow-limiting dissection or stenotic recoil post-treatment. Medical records were obtained at admission, and all patients underwent physical examination, measurement of ankle-brachial index (ABI) and computed tomography angiography. This retrospective cohort study was performed without financial support from industry. The study protocol was approved by the local ethics committee. The requirement for informed consent was waived in view of the retrospective study design.

\* Corresponding author.

E-mail address: [nickji@126.com](mailto:nickji@126.com) (D. Ji).

<https://doi.org/10.1016/j.jimed.2021.12.005>

Received 15 September 2021; Received in revised form 2 December 2021; Accepted 8 December 2021

## 2.2. Interventional procedure and medical therapy

All procedures were performed under local anesthesia. Depending on the location and characteristics of the target lesion, contralateral or ipsilateral femoral puncture was performed in the patients. A 6/7F sheath (Terumo Inc., Tokyo, Japan) was used for the ipsilateral approach, while a 6/7F contralateral sheath (Cook Inc., Bloomington, USA) was applied for the crossover approach. After sheath insertion, 3000–5000 IU of heparin was administered accordingly in these patients. A 0.014 or 0.018-inch guidewire and CXI supporting microcatheters (Cook Inc., Bloomington, USA) were used to cross over the lesion. Predilatation with a plain balloon was performed in the patient prior to the use of PCB (Orchid, Aoctec Scientific, Beijing, China). If more than one PCB was used per lesion and the overlap of the two devices was at least 5 mm. The routine inflation time was 3 min. Severe calcification was defined as one that was compromising both sides of the arterial lumen over a length of at least 5 cm. Procedural success was defined as <30% residual stenosis in the final angiogram.

Post successful procedure, all patients were administered a combination of antiplatelet agents including aspirin (100 mg/day), clopidogrel (75 mg/day), and cilostazol (100 mg/day) orally for at least 6 months, and then this was converted to dual antiplatelet therapy with daily aspirin (100 mg) and cilostazol (100 mg).

## 2.3. Follow-up

All patients underwent clinical examination, ABI measurement, and duplex ultrasound before discharge as the baseline of future follow-up. Follow-up was performed routinely at 3, 6 and 12 months with duplex ultrasound after the intervention and at 6-month intervals thereafter. The primary endpoint was vessel patency, defined as freedom from >50% restenosis, as determined by duplex ultrasound (peak systolic velocity ratio <2.4) and freedom from clinically driven target lesion revascularization (FF-CDTLR).

## 2.4. Statistical analysis

Continuous variables are presented as the mean  $\pm$  standard deviation. Categorical variables are presented as frequency and percentage. Patency rates and FF-CDTLR were described using Kaplan–Meier analyses. A p-value of <0.05 was considered statistically significant. Data were analyzed with SPSS version 24 (SPSS, Chicago, Illinois, USA) for windows.

## 3. Results

### 3.1. Baseline characteristics

A total of 49 patients (49 limbs) were treated with PCB for extra-long femoropopliteal lesions. The mean age was  $70.9 \pm 8.0$  years, and the number of male patients (59.2%) was more than that of female patients. There were 67.3% and 75.5% of patients who had diabetes and hypertension, respectively. The baseline characteristics are provided in Table 1.

### 3.2. Lesion and procedure characteristics

Lesion characteristics are given in Table 2. The mean lesion length was  $34.9 \pm 3.7$  cm, and chronic total occlusions (CTO) were present in 18.4% (9/49) of patients; 26.5% (13/49) of these lesions were classified as TASC II (TransAtlantic Inter-Society Consensus) type D lesions, with no lesions exhibiting severe calcification. For 36.7% of patients, the lesions were found within the superficial femoral artery (SFA) only, and in 63.3% of patients, the lesions involved both the SFA and popliteal arteries.

Technically, procedural success was achieved in all patients. Two

**Table 1**  
Baseline characteristics.

Variables	N = 49
Age, yrs	70.9 $\pm$ 8.0
Men	29 (59.2%)
Coronary artery disease	19 (38.8%)
Diabetes mellitus	33 (67.3%)
Kidney dysfunction	7 (14.3%)
Cerebrovascular disease	10 (20.4%)
Current smokers	19 (38.8%)
Arterial hypertension	37 (75.5%)
Hypercholesterolemia	14 (28.6%)
Rutherford stages	
2	5
3	16
4	24
5	4
Preprocedure ABI	0.48 $\pm$ 0.19
Postprocedure ABI	0.87 $\pm$ 0.21

**Table 2**  
Lesion characteristics.

Variables	N = 49
Lesion length, cm	34.9 $\pm$ 3.7
Mild or moderate calcification	49
TASC C	36
TASC D	13
CTO	9
Vessels involved	
SFA	18
SFA+PA	31
Outflow PTA	9

PCB balloons were used per limb. In stenotic lesions, we were able to cross over all the lesions intra-luminally. For CTOs lesions, crossing-over was subintimal in 44.4% (4/9) of patients. Of the patients treated, 16 (32.7%) patients had infra-popliteal outflow lesions and 9 (18.4%) patients had inflow lesions. There were no periprocedural complications noted in the study.

### 3.3. Clinical outcomes

Patients were followed up for a mean duration of  $18.2 \pm 7.5$  months. No patient was lost to follow-up. No major complications were observed, including major amputations, thromboses, or all-cause deaths during a period of 12 months.

Kaplan–Meier estimates of primary patency were 87.8% at 6 months and 71.4% at 12 months, while FF-CDTLR was 91.8% at 6 months and 77.6% at 12 months. Kaplan–Meier curves of primary patency and FF-CDTLR rates are shown in Figs. 1 and 2.

## 4. Discussion

Recent studies showed the superiority of PCBs as compared to standard angioplasty (plain old balloon angioplasty, POBA) in femoropopliteal ischemia.<sup>1–7</sup> However, these studies were largely performed in relatively short lesions. There is still uncertainty regarding the most appropriate treatment strategy for TASC types C and D in femoropopliteal artery disease. Despite its established limitations, PTA with or without stenting is widely used at many centers. Self-expandable bare-metal stents have recently been shown to be beneficial in comparison with standard PTA,<sup>11–13</sup> especially when new-generation devices are used<sup>14–16</sup> for relatively simple lesions. However, the inherent benefits of such permanent prostheses over PTA alone have not convinced all operators to use them in a routine fashion, especially for long lesions in which placement of full metal jackets is not considered the standard of care. Restenosis following stenting in long SFA lesions has been reported

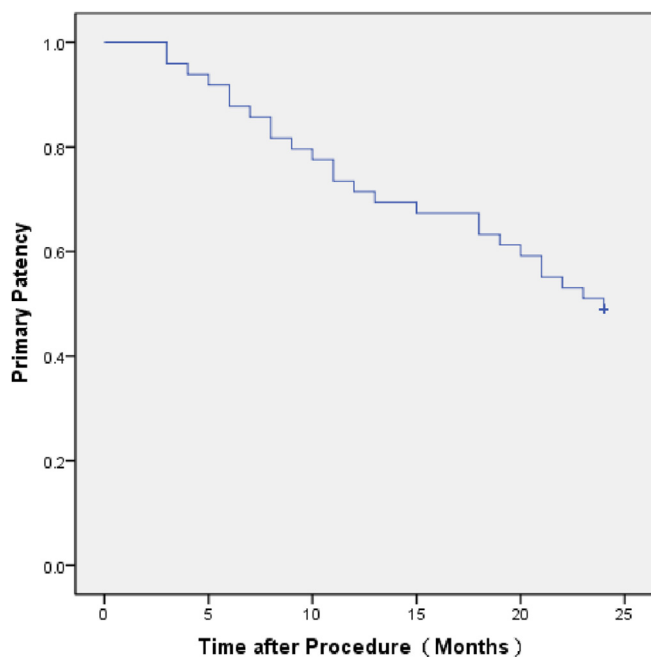


Fig. 1. Kaplan-Meier estimates of primary patency.

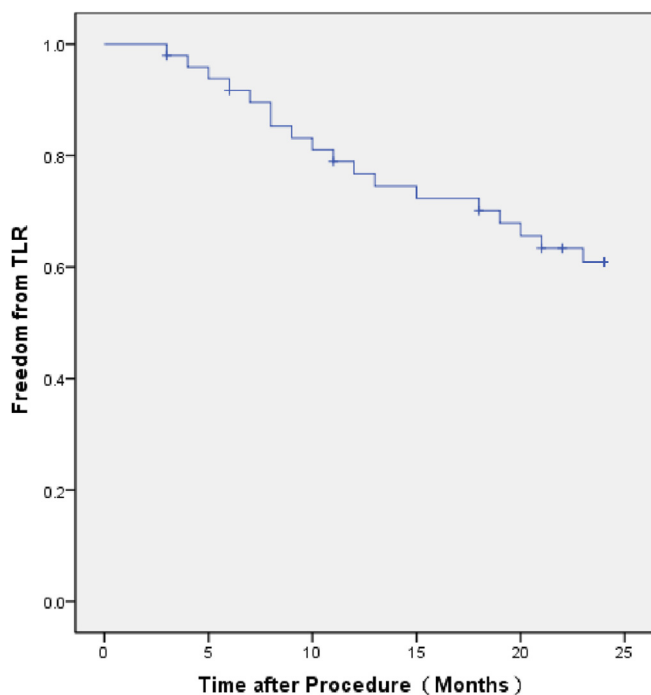


Fig. 2. Kaplan-Meier estimates of FF-CDTLR.

to occur at a frequency of up to 50%.<sup>17–19</sup> The pattern of restenosis in full metal jackets is diffuse in-stent restenosis or in-stent occlusion, which poses a challenge to treat accordingly.

As reported, the SFA-long trial<sup>20</sup> enrolled patients with 105 femoropopliteal long lesions, with a mean length of  $25.12 \pm 7.9$  cm. The 12-month follow-up primary patency was 83.2%, while the FF-CD TLR was 96% in this study. A total of 11 lesions (10.9%) accomplished technical success with bailout stenting; however, no subgroup analysis was performed for the 94 lesions treated with PCBs alone.

The Global SFA registry<sup>21</sup> enrolled 140 femoropopliteal long lesions with a mean length of  $21.2 \pm 6.5$  cm. The 12-month follow-up FF-CD

TLR was 97.3%. Furthermore, 25 long femoropopliteal lesions ( $\geq 25$  cm) treated with PCBs alone achieved a 96% FF-CD TLR at 12 months.

Our 6 and 12 months primary patency rates were 87.8% and 71.4%, respectively, in femoropopliteal lesions, with a mean lesion length of  $34.9 \pm 3.7$  cm. Meanwhile, the FF-CDTLR were 91.8% and 77.6% at 6 and 12 months, respectively. The rates of our 12-month primary patency and FF-CDTLR were not as ideal as those reported by the SFA-long trial and Global SFA registry. We believe that might be due to a much longer lesion length being treated in our study. We did vessel pre-dilation for PCBs with POBA, which must also have resulted in more dissections for the longer length. The mechanism of PTA consists of adventitial stretching, medial necrosis, and dissection or plaque fracture generally involving the external elastic lamina. The dissection severity and lesion length are additive to the risk of restenosis after balloon angioplasty.<sup>22</sup>

The efficacy of endovascular therapy for TASC D lesions of the FPA has been practically well documented<sup>23–26</sup>: a 12-month primary patency rate was 44%–54% (PTA with stent). Davaine et al.<sup>23</sup> reported a 12-month primary patency rate of 44% for 37 long lesions (mean length:  $33 \pm 8$  cm). Dosluoglu et al.<sup>24</sup> reported 12-month primary patency of 54% for only four long lesions (mean length:  $27 \pm 5.5$  cm). However, primary patency rates obtained in those studies were not as favorable as our 12-month primary patency rate of 71.4%. Furthermore, all the cases in this study were technically successful without bailout stenting.

The favorable results in this study represent our clinical outcomes in extra-long FPA atherosclerotic lesions treated by PCBs alone. Based on our results, we speculate that performing PCBs for extra-long femoropopliteal lesions ( $>30$  cm) is safe and effective. The patency rate is acceptable at 12 months following the primary intervention. However, patency rates obtained in this study are lower than those of most published outcomes of PCBs in long FPA lesions. This may be due to the differences in patient cohort and lesion characteristics (that is, all lesions in this study were much longer).

#### 4.1. Study limitations

There are limitations due to the retrospective and nonrandomized nature of this study. As this study represents our clinical outcomes, the ability to regulate patients' behaviors during the time of follow-up is limited after treatment. Furthermore, there may have been clinical and/or anatomic differences in patients treated with PCBs alone compared to PCBs with bailout stenting. Such differences could potentially influence patency outcomes, especially since this study was a 12-month follow-up with a small sample size.

## 5. Conclusions

PCB has favorable clinical efficacy in patients with extra-long femoropopliteal artery atherosclerotic lesions.

## Funding

This research received no specific grant from any funding agency in the public, commercial, or not-for-profit sectors.

## Ethical statement

This study protocol conforms to the ethical guidelines of the 1975 Declaration of Helsinki.

## Informed consent

The requirement for informed consent was waived in view of the retrospective study design.

## Declaration of competing interest

The authors declare that we have no conflict of interest.

## References

- Caradu C, Lakhli E, Colacchio EC, et al. Systematic review and updated meta-analysis of the use of drug-coated balloon angioplasty versus plain old balloon angioplasty for femoropopliteal arterial disease. *J Vasc Surg.* 2019;70:981–995. e10.
- Biondi-Zoccai G, Sangiorgi G, D'Ascenzo F, et al. Drug-eluting balloons for peripheral artery disease: a meta-analysis of 7 randomized clinical trials and 643 patients. *Int J Cardiol.* 2013;168:570–571.
- Scheinert D, Duda S, Zeller T, et al. The LEVANT I (Lutonix paclitaxel-coated balloon for the prevention of femoropopliteal restenosis) trial for femoropopliteal revascularization: first-in human randomized trial of low-dose drug-coated balloon versus uncoated balloon angioplasty. *JACC Cardiovasc Interv.* 2014;7:10–19.
- Werk M, Langner S, Reinkensmeier B, et al. Inhibition of restenosis in femoropopliteal arteries: paclitaxel-coated versus uncoated balloon: femoral paclitaxel randomized pilot trial. *Circulation.* 2008;118:1358–1365.
- Tepe G, Laird J, Schneider P, et al. Drug-coated balloon versus standard percutaneous transluminal angioplasty for the treatment of superficial femoral and/or popliteal peripheral artery disease: 12 month results from the IN. *PACT SFA randomized trial.* 2015;131:495–502.
- Rosenfield K, Jaff MR, White CJ, et al. Trial of a paclitaxel-coated balloon for femoropopliteal artery disease. *N Engl J Med.* 2015;373:145–153.
- Tepe G, Schmitzmeier S, Speck U, et al. Advances on drug-coated balloons. *J Cardiovasc Surg.* 2010;51:125–143.
- Tepe G, Gögebakan Ö, Redlich U, et al. Angiographic and clinical outcomes after treatment of femoro-popliteal lesions with a novel paclitaxel-matrix-coated balloon catheter. *Cardiovasc Intervent Radiol.* 2017;40:1535–1544.
- Tepe G, Zeller T, Albrecht T, et al. Local delivery of paclitaxel to inhibit restenosis during angioplasty of the leg. *N Engl J Med.* 2008;358:689–699.
- Micari A, Cioppa A, Vadalà G, et al. A new paclitaxel-eluting balloon for angioplasty of femoropopliteal obstructions: acute and midterm results. *EuroIntervention.* 2011;7(Suppl K):K77–K82.
- Schillinger M, Sabeti S, Loewe C, et al. Balloon angioplasty versus implantation of nitinol stents in the superficial femoral artery. *N Engl J Med.* 2006;354:1879–1888.
- Laird JR, Katzen BT, Scheinert D, et al. Nitinol stent implantation vs. balloon angioplasty for lesions in the superficial femoral and proximal popliteal arteries of patients with claudication: three-year follow-up from the RESILIENT randomized trial. *J Endovasc Ther.* 2012;19:1–9.
- Schillinger M, Sabeti S, Dick P, et al. Sustained benefit at 2 years of primary femoropopliteal stenting compared with balloon angioplasty with optional stenting. *Circulation.* 2007;115:2745–2749.
- Matsumura JS, Yamanouchi D, Goldstein JA, et al. The United States study for evaluating endovascular treatments of lesions in the superficial femoral artery and proximal popliteal by using the protege everflex nitinol stent system II (DURABILITY II). *J Vasc Surg.* 2013;58:73–83. e1.
- García L, Jaff MR, Metzger C, et al. Wire-interwoven nitinol stent outcome in the superficial femoral and proximal popliteal arteries: twelve-month results of the SUPERB trial. *Circ Cardiovasc Interv.* 2015;8, e000937.
- Gray WA, Feiring A, Cioppi M, et al. S.M.A.R.T. Self-Expanding nitinol stent for the treatment of atherosclerotic lesions in the superficial femoral artery (STROLL): 1-year outcomes. *J Vasc Intervent Radiol.* 2015;26:21–28.
- Bosiers M, Deloose K, Callaert J, et al. Results of the Protege EverFlex 200-mm-long nitinol stent (ev3) in TASC C and D femoropopliteal lesions. *J Vasc Surg.* 2011;54:1042–1050.
- Armstrong EJ, Saeed H, Alvandi B, et al. Nitinol self-expanding stents vs. balloon angioplasty for very long femoropopliteal lesions. *J Endovasc Ther.* 2014;21:34–43.
- Tosaka A, Soga Y, Iida O, et al. Classification and clinical impact of restenosis after femoropopliteal stenting. *J Am Coll Cardiol.* 2012;59:16–23.
- Micari A, Vadalà G, Castriota F, et al. 1-Year results of paclitaxel-coated balloons for long femoropopliteal artery disease: evidence from the SFA-long study. *JACC Cardiovasc Interv.* 2016;9:950–956.
- Thieme M, Von Bilderling P, Paetzel C, et al. The 24-month results of the lutonix global SFA registry: worldwide experience with lutonix drug-coated balloon. *JACC Cardiovasc Interv.* 2017;10:1682–1690.
- Armstrong EJ, Brodman M, Deaton DH, et al. Dissections after infrainguinal percutaneous transluminal angioplasty: a systematic review and current state of clinical evidence. *J Endovasc Ther.* 2019;26:479–489.
- Davaine JM, Azéma L, Guyomarch B, et al. One-year clinical outcome after primary stenting for Trans-Atlantic Inter-Society Consensus (TASC) C and D femoropopliteal lesions (the STELLA "STEnting Long de L'Artère fémorale superficielle" cohort). *Eur J Vasc Endovasc Surg.* 2012;44:432–441.
- Dosluoglu HH, Cherr GS, Lall P, et al. Stenting vs above knee polytetrafluoroethylene bypass for TransAtlantic Inter-Society Consensus-II C and D superficial femoral artery disease. *J Vasc Surg.* 2008;48:1166–1174.
- Grenville JL, Tan KT, Moshonov H, et al. Endovascular first strategy for de novo TransAtlantic Inter-Society Consensus C and D femoro-popliteal disease: mid-term outcomes from a single tertiary referral center. *Vascular.* 2015;23:31–40.
- Baril DT, Chaer RA, Rhee RY, et al. Endovascular interventions for TASC II D femoropopliteal lesions. *J Vasc Surg.* 2010;51:1406–1412.