

## Evolving consensus on managing vitreo-retina and uvea practice in post-COVID-19 pandemic era

Vishali Gupta, Anand Rajendran<sup>1</sup>, Raja Narayanan<sup>2</sup>, Shobhit Chawla<sup>3</sup>, Atul Kumar<sup>4</sup>, Mahesh Shanmugam Palanivelu<sup>5</sup>, NS Muralidhar<sup>6</sup>, Chaitra Jayadev<sup>7</sup>, Rajeev Pappuru<sup>2</sup>, Manoj Khatri<sup>8</sup>, Manisha Agarwal<sup>9</sup>, Ajay Aurora<sup>10</sup>, Pramod Bhende<sup>11</sup>, Muna Bhende<sup>11</sup>, Prashant Bawankule<sup>12</sup>, Pukhraj Rishi<sup>11</sup>, Anand Vinekar<sup>7</sup>, Hemant Singh Trehan<sup>13</sup>, Jyotirmay Biswas<sup>11</sup>, Rupesh Agarwal<sup>14</sup>, S Natarajan<sup>15</sup>, Lalit Verma<sup>16</sup>, Kim Ramasamy<sup>17</sup>, A Giridhar<sup>18</sup>, Ekta Rishi<sup>11</sup>, Dinesh Talwar<sup>16</sup>, Avinash Pathangey<sup>19</sup>, Rajvardhan Azad<sup>20</sup>, Santosh G Honavar<sup>21</sup>

The COVID-19 pandemic has brought new challenges to the health care community. Many of the super-speciality practices are planning to re-open after the lockdown is lifted. However there is lot of apprehension in everyone's mind about conforming practices that would safeguard the patients, ophthalmologists, healthcare workers as well as taking adequate care of the equipment to minimize the damage. The aim of this article is to develop preferred practice patterns, by developing a consensus amongst the lead experts, that would help the institutes as well as individual vitreo-retina and uveitis experts to restart their practices with confidence. As the situation remains volatile, we would like to mention that these suggestions are evolving and likely to change as our understanding and experience gets better. Further, the suggestions are for routine patients as COVID-19 positive patients may be managed in designated hospitals as per local protocols. Also these suggestions have to be implemented keeping in compliance with local rules and regulations.

**Key words:** COVID-19, preferred practice patterns, retinopathy of premat, Uveitis, Vitreoretina

### Access this article online

#### Website:

www.ijo.in

#### DOI:

10.4103/ijo.IJO\_1404\_20

### Quick Response Code:



The global Corona virus disease 2019 (COVID-19) pandemic has brought in several unprecedented challenges that the world has no experience in dealing with. The All India Ophthalmological Society (AIOS) – Indian Journal of Ophthalmology (IJO) recently published a consensus statement on preferred practices during the COVID-19 pandemic and suggested that these general practices be followed during the post-lockdown period as well.<sup>[1]</sup> However, as the super specialty clinics are gearing up to resume

their practices, there are lot of queries being generated that need to be addressed both by evidence and consensus. The pandemic has highlighted geopolitical differences in management and screening protocols. Thus, although there are guidelines being issued by several international ophthalmic societies, it may not be possible to apply them uniformly to a country like India with social and economic constraints.<sup>[2]</sup> Moreover, the practice patterns may be influenced by factors like the size of facility, number of patients being handled, strength of the staff and facilities available besides their capability and preparedness to handle COVID-19 positive patients. The present preferred practice patterns have been formulated by a leading group of experts constituted from the representatives of Vitreoretinal Society of India (VRSI), Uveitis Society of India (USI), iROP and from major institutes and the IJO leadership. These practice patterns are being formulated to help restart vitreo-retinal services amongst tertiary institutions, corporate and group practices as well as individual eye clinics. The suggestions are for routine patients as COVID-19 positive patients may be managed in designated hospitals as per local protocols.

Advanced Eye Centre, Post Graduate Institute of Medical Education and Research, Chandigarh, <sup>1</sup>Aravind Eye Hospital Chennai, <sup>2</sup>LV Prasad Eye Institute, Hyderabad, <sup>3</sup>Prakash Netra Kendr, Lucknow, <sup>4</sup>Dr. RP. Centre for Ophthalmic Sciences, All India Institute of Medical Sciences, New Delhi, <sup>5</sup>Sankara Eye Hospital, Bengaluru, <sup>6</sup>Retina Institute of Karnataka, Bengaluru, <sup>7</sup>Narayana Nethralaya Eye Institute, Bengaluru, <sup>8</sup>Eydox Eye Hospital, Chennai, <sup>9</sup>Shroff Charity Eye Hospital, New Delhi, <sup>10</sup>Vision Plus Eye Centre, NOIDA, <sup>11</sup>Sankara Nethralaya, Chennai, <sup>12</sup>Sarakshi Nethralaya, Nagpur, <sup>13</sup>Army Hospital R&R, Dhaua Kuan, New Delhi, <sup>14</sup>National Healthcare Group Eye Institute, Tan Tock Seng Hospital, Singapore, <sup>15</sup>Aditya Jyot Eye Hospital, Mumbai, <sup>16</sup>Centre for Sight, New Delhi, <sup>17</sup>Aravind Eye Hospital, Madurai, <sup>18</sup>Giridhar Eye Hospital, Kochi, <sup>19</sup>LV Prasad Eye Institute, Visakhapatnam, <sup>20</sup>Regional Institute of Ophthalmology Indira Gandhi Institute of Medical Institute of Medical Sciences, Patna, <sup>21</sup>Centre for Sight, Hyderabad, India

All Authors contributed equally to the manuscript

**Correspondence to:** Prof. Vishali Gupta, Vitreo-Retina and Uvea Services, Advanced Eye Centre, Post Graduate Institute of Medical Education and Research, Chandigarh, India. E mail: vishalisara@yahoo.co.in; vishalisara@gmail.com

Received: 08-May-2020

Revision: 09-May-2020

Accepted: 09-May-2020

Published: 25-May-2020

This is an open access journal, and articles are distributed under the terms of the Creative Commons Attribution-NonCommercial-ShareAlike 4.0 License, which allows others to remix, tweak, and build upon the work non-commercially, as long as appropriate credit is given and the new creations are licensed under the identical terms.

**For reprints contact:** reprints@medknow.com

**Cite this article as:** Gupta V, Rajendran A, Narayanan R, Chawla S, Kumar A, Palanivelu MS, *et al.* Evolving consensus on managing vitreo-retina and uvea practice in post-COVID-19 pandemic era. Indian J Ophthalmol 2020;68:962-73.

## Methods

This consensus was developed in continuation to the previous publication by Sengupta *et al.*<sup>[1]</sup> The experts included the representatives of VRSI, USI, iROP as well as the retina chiefs from major centres in India. The base document was prepared by the allocation of sections to different experts. The paper was then compiled and reviewed by the entire committee. In case there was any difference of opinion, a mutual consensus was reached by discussion amongst all the experts. The final version of the document was approved by all the authors.

## Practice Guidelines for Vitreo- Retina Services

### I. Tele-counseling for triage and appointments

The group encourages the use of tele-consults to maintain communication with patients and provide staggered appointments to avoid crowding in the clinic. With regard to new patients, this can also be used to fill up patient details, prior to patient’s arrivals in the clinic. Each clinic can design a flow chart to suit their practice to direct patient flow. A sample flow chart is shown in Fig. 1. Encourage tele-consultation to prioritize patients as well as reduce walk-ins. Any patient directly asking for a retinal consultation may need to be questioned further to ascertain the urgency of the condition. A trained assistant/fellow can be given the responsibility of talking to the patient to see if they need to be seen urgently.

The following list is to help prioritization for those with large number of patients to avoid the overcrowding. The clinics with lesser number of patients, however, can see patients who have been listed under semi-urgent or delayed appointments:

- A. Urgent: The following complaints would need to be attended on urgent basis at the earliest:
  - i. Sudden or rapid loss of vision

- ii. Acute onset Flashes, floaters,
- iii. Painful loss of vision,
- iv. Recent onset metamorphopsia/reading difficulty.
- v. Conditions needing urgent surgery<sup>[2]</sup> e.g., open globe injuries, rhegmatogenous retinal detachment (RRD), recent onset macular tractional retinal detachment (TRD) or combined RD, endophthalmitis, recent onset submacular haemorrhage, nucleus drop or retained cortical matter with secondary glaucoma as per guidelines of AIOS-IJO.<sup>[1]</sup>
- vi. New cases of retinoblastoma, ocular tumours or Retinopathy of Prematurity (ROP)
- vii. Conditions where early surgery should be considered including bilateral vitreous haemorrhage, vitreous haemorrhage in one-eyed patient etc. Or any other condition where treating physician feels the urgency to see the patient.

- B. Semi-urgent Appointments The next priority would be the patients with following complaints:
  - i. Patients with diabetes mellitus with complains of slow onset of vision loss.
  - ii. Any patient who has been treated with injections recently elsewhere/operated elsewhere seeking consultation.
  - iii. Any retina case referred by another colleague can be considered as semi urgent and given an appointment.
  - iv. Patients receiving injections for neovascular age related macular degeneration (AMD) and polypoidal choroidal vasculopathy (PCV).
  - v. Patients receiving injections for non AMD choroidal neovascular membrane (CNV)
  - vi. Retinal Vein Occlusion (RVO) and Diabetic Macular Edema (DME) patients needing frequent injections, and mono-ocular patients.
  - vii. Patients operated within the last 3 months and who have silicone oil will need to be reviewed soon.
  - viii. Patients on anti-glaucoma medications also need to be seen early.

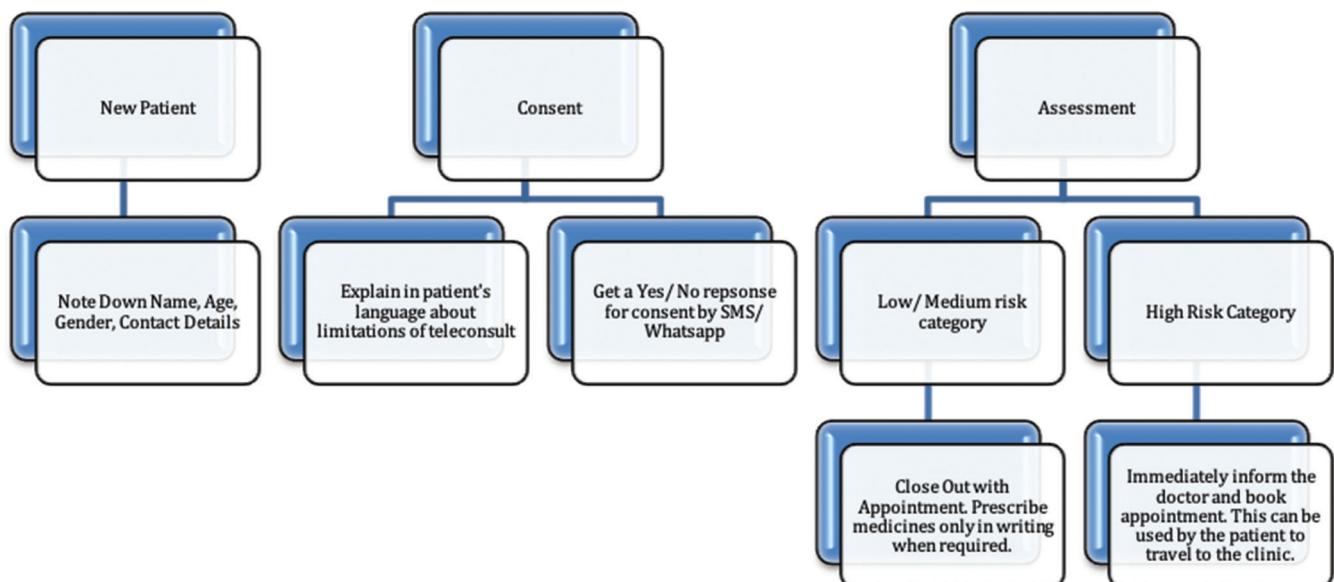


Figure 1: Flow chart demonstrating the triage during teleconsult

C. Delayed Appointments: The following patients can be given appointments later, depending upon the slots available and given tele-consult in the meantime:

- i. All patients who have been receiving regular injections but are stable
- ii. Routine follow up for wet AMD, DME and RVO
- iii. Patient who is stable and has not needed injection in the last visit
- iv. Regular patients with Non proliferative diabetic retinopathy (NPDR) and Proliferative Diabetic Retinopathy (PDR stable) post Laser/surgery
- v. Stable post RD surgery.

Patients who have maintained stable vision with infrequent injections are candidates for telephonic consultation. COVID-19 testing is not mandated for OPD examination, Lasers or Intravitreal injections.

## II. Techniques of retinal examination

### A. Home versus clinic dilation

Dilation at the hospital may increase the possibility of spread of infection during a pandemic due to:

1. Inadvertent spread by the assistant tasked to instil the eye drops if the dropper or the assistant's fingers come in contact with an infected person
2. Patients are usually clustered at the dilation area of the hospital which increases their time in hospital and risk of exposure. This risk can be mitigated by home dilation.

Revisit Patients: Home dilation is thus advisable for review patients where information regarding prior history of allergy to dilating drops and history of systemic hypertension can be obtained from their case records. An electronic prescription detailing the above may be given. The patient and family can preferably be counselled about the proper technique through appropriate visual aids such as a video or a graphic.

New Patients: In new patients and in those where home dilation is not possible, dilation at the hospital is necessary, we recommend following precautions:

1. The assistant should be wearing gloves and a face shield and disinfect her/his hand appropriately after each patient
2. Non-touch technique of applying the dilating drops – requesting the patient to retract the lower eye lid and extending the neck, instead of the assistant retracting the lid or touching the head of the patient [Fig. 2a]. In those unable to self-retract the lid, a disposable cotton tipped applicator may be used to retract the lid, taking care not to touch the end that has come in contact with the patient [Fig. 2b]. The cotton tipped applicator is then disposed appropriately
3. Dilation should be performed in an airy, open area, the patients being seated with distancing norms being followed.<sup>[1]</sup> We can also consider dilating the patient in the clinic area itself to avoid unnecessary movement of the patient.

### B. Slit-lamp examination

All precautions regarding the breath shield disinfection of slit lamp and lenses to be followed as per AIOS-IJO recommendations.<sup>[1]</sup> Indirect ophthalmoscopy may be preferred. In case of slit lamp biomicroscopy, the lenses used for retinal examination can be covered with cling film that can be cleaned easily without damaging the lens surface.

### C. Preferred method for Retinal examination

Retinal examination during the pandemic need not be significantly different except for some precautions:

1. Contact lens examination of the fundus should be avoided if possible
2. A face shield mounted on the indirect ophthalmoscope or on the examiner's head is recommended in addition to the personal protective equipment (PPE). The indirect ophthalmoscope mounted shield with a cut out for the eye piece, offers better visualization of the fundus [Fig. 3]. Patient should wear a mask during the examination, the upper border of which can be secured with an adhesive tape if ill-fitting to minimize the risk of patient's breath contaminating the examiner's hands
3. It is preferable to use alcohol sanitization of the hands prior to wearing the indirect ophthalmoscope and also prior to removing it to minimise the risk of it becoming a fomite
4. Scleral depression to be avoided unless essential in a given case. Cotton-tipped applicator maybe used as disposable depressor
5. Minimal or no talking during fundus examination is advisable. The desired direction of gaze during indirect ophthalmoscopy can be indicated to the patient by gently tapping, with a gloved hand, the appropriate periorcular region, rather than voicing it.

### D. Clinical Examination versus Imaging

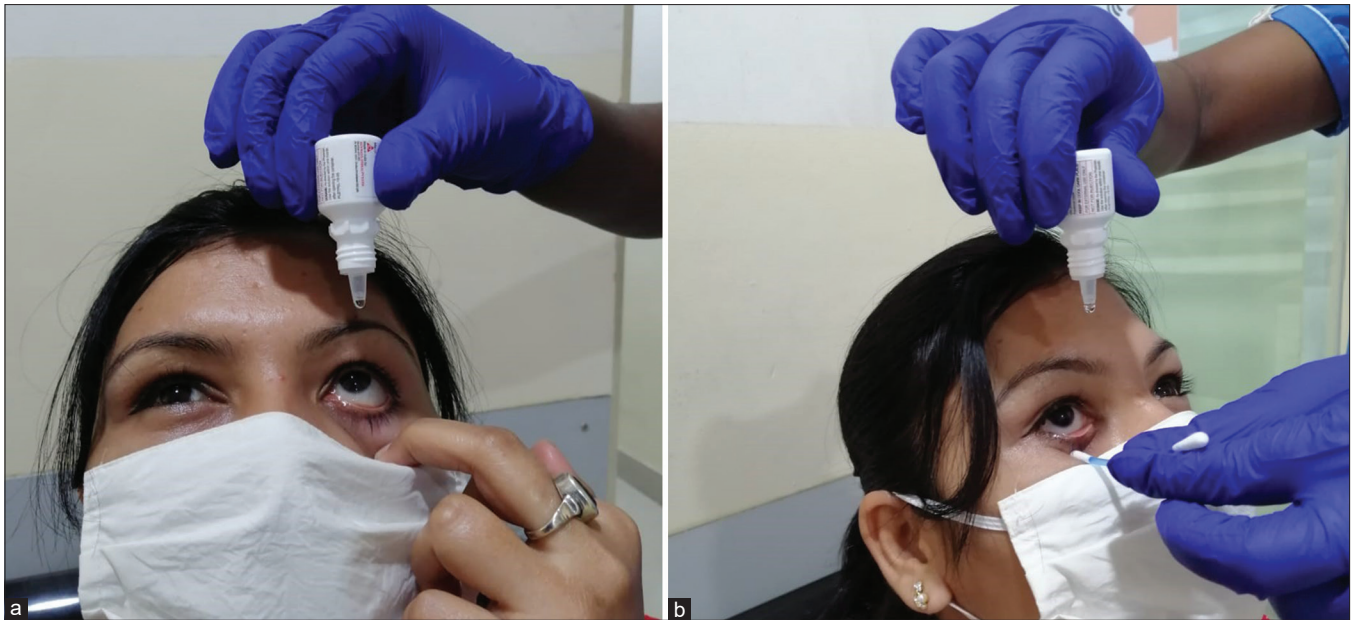A clinical exam performed with adequate precautions is preferable to relying on an image. Limitation of imaging are:

1. Even a wide-angle fundus image is not as thorough as an indirect ophthalmoscopic examination. A wide-angle fundus camera is rarely available to most practitioners as well
2. Media opacities can compromise an image while an indirect can most often circumvent it
3. Using an imaging device can result in clustering of patients, which is to be avoided.

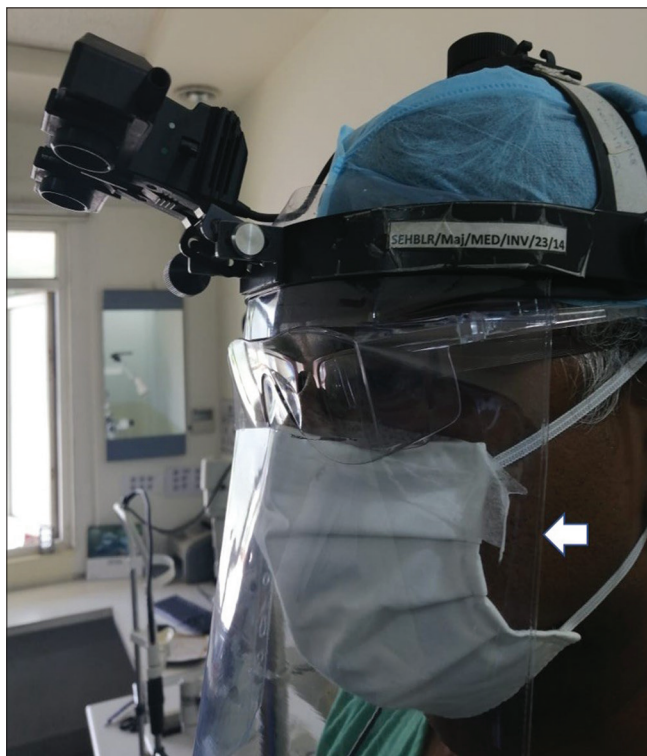On the other hand, an imaging device would be particularly useful for tele-consultation considering the limitation to travel during the pandemic.

## III. Retinal imaging

1. Clinicians should exercise caution while deciding about investigations. Essential and critical investigations may preferably be resorted to
2. Non-invasive investigative modalities that are less time-consuming or have no patient contact are preferred. Both optical coherence tomography (OCT) and optical coherence tomography angiography (OCTA) can be used as an alternative to dye-based angiography. Simple protocols that can be done in few seconds are preferred
3. Request tests only when critical to make a clinical decision. Procedures like Indocyanine Green Angiogram (ICG) which involve longer chair time are best avoided and should be performed only when other investigative modalities do not give the required information for a definite diagnosis or decisive treatment strategy
4. B-scan ultrasonography, though non-invasive modality, has contact of the probe with the patient's eye. If the scan



**Figure 2:** (a) Patient self-retracting her lower lid during instillation of dilator drop. (b) Using cotton tip applicator to retract lower lid



**Figure 3:** Face shield mounted on Indirect Ophthalmoscope

becomes mandatory, extra cleansing precautions should be taken

5. Electrophysiological tests are best avoided unless absolutely essential.

#### IV. Retinal lasers

##### A. Indications and priority

While the indications for laser treatment would remain same, we may have to prioritise them in practices that are overloaded

and wish to reduce the number of patients on any given day. We should prioritise them, as captured in Table 1 too, in the following way:<sup>[1,3-6]</sup>

Early lasers to be done on priority basis

1. Active Proliferative Diabetic Retinopathy (PDR)
2. ROP laser
3. Retinal tears or breaks (e.g., Horse shoe tears)
4. Laser barrage wherever required e.g., macula on RD, sub clinical RD
5. Extra foveal CNVM.

Lasers that can be delayed to next available appointments

1. Diabetic macular edema
2. Macular edema of other causes.

In patients with DME, Anti vascular endothelial growth factor (VEGF) injections may be preferred over laser photocoagulation and photo dynamic therapy (PDT) laser as well, wherever indicated.

##### B. Laser delivery modes

There are two modes of laser delivery: a) Contact delivery system- slit lamp delivery systems- single spot or multispot laser and b) Non-contact laser delivery - Indirect laser delivery system (ILO). The following consensus could be reached amongst experts on the preferred mode of delivery:

1. Prefer non-contact laser delivery system over slit lamp for non-macular lasers
2. If non-contact indirect laser delivery system is not available, then multispot laser is preferred over single spot laser in order to make the process faster with lesser number of sittings
3. Avoid sharing of drops such as Paracaine 1% eye drops and prefer to instil a drop of betadine in the cul-de-sac of the patient after the removal of the contact lens
4. The laser contact lenses or 20 dioptre lens to be washed with soap and water after every use or dip in sodium hypochlorite (0.5%) solution.

**Table 1: Prioritisation list of medical retina procedures**

Emergency procedures (< 1 week)	Semi-emergency procedures (1-3 weeks)	Elective procedures ( $\geq$ 4 weeks)
Intravitreal injections for Neovascular AMD, other CNV, PCV, Neovascular Glaucoma, (Treat and extend to maximum interval possible). Intravitreal Injections in One Eyed patients with severe vision reduction with Diabetic or other causes of Macular Edema Active proliferative diabetic retinopathy requiring treatment (PRP laser or intravitreal-anti VEGF) Barrage lasers for HSTs, Macula threatening RDs Lasers for extrafoveal CNVMs Malignant hypertensive retinopathy ROP screening, lasers and anti-VEGF treatment	Macular edema requiring treatment Severe NPDR, never lasered with macular edema and recent drop in VA Stable neovascular AMD where the routine Intravitreal injection has been deferred due to lock down CNVM on Treat & Extend regime Acute CSCR	Stable Macular Edema (DME, BRVO, CRVO) on followup AntiVEGF therapy Stable CNVM on followup AntiVEGF therapy Chronic or stable CSCR Macular telangiectasia Stable PDR post PRP Screening for macular drug toxicity Non-neovascular (dry) AMD Low-risk DR Screening Retinal Dystrophies Angioid streaks Hypertensive retinopathy (non-malignant) Choroidal Folds

## V. Intravitreal injections (IVI)

The guidelines for Intravitreal injections during these unprecedented COVID-19 times are only suggested where high volume practices have to use preferences. These can be modified based on the patient load in each health care facility and the presumed transmissibility of the virus in the region. The prioritization of these, as encapsulated in Table 1, can be done as follows:<sup>[7-9]</sup>

### A. Emergent Need for IVI (inject within 1 week)

1. Neovascular AMD, PCV: New/Follow-up
2. Neovascular glaucoma
3. New-onset central retinal vein occlusion (CRVO) with macular edema
4. ROP requiring Intravitreal injection of anti-VEGF
5. Active PDR, never lasered, recent Vitreous Haemorrhage, These patients will need PRP too
6. Treatment naive patients with PDR and macular edema may need IVI followed by laser.

### B. Urgent Need for IVI (inject within 3 weeks)

1. DME, monocular patient, Recent drop in VA  $<6/12$
2. Severe NPDR, never lasered with macular edema and recent drop in VA
3. Stable neovascular AMD where the routine Intravitreal injection has been deferred due to lock down
4. CNVM on Treat and Extend regime.

### C. Routine Need for IVI (may defer injections by $\geq 4$ weeks)

1. Stable DME with VA  $>6/12$ : can be maintained on observation, good metabolic control and receives intravitreal injection later on (Protocol V)<sup>[1]</sup>
2. Branched retinal vein occlusion (BRVO) with Macular Edema
3. Stable CRVO Macular Edema, having had multiple intravitreal injections
4. CNVM cases, stable on treat and extend.

In addition to the standard practices being followed in the post-COVID-19 era, few additional considerations are:

1. All our protocols for Intravitreal injections should be in sync with the measures being taken by the authorities and the consensus statement on preferred practices during COVID-19 pandemic by AIOS<sup>[1,7]</sup>
2. The injections should be given with patient wearing a mask, draped and the person injecting should wear gown, N95,

face shield (Personal protective equipment - PPE) or as per their institute's protocol

3. Between the injections 10-15 minutes time can be given during which scrubbing can happen
4. The injections must not be loaded and kept on the trolley in advance for all the Intravitreal injections scheduled that day
5. During the pre-COVID-19 times, numerous institutions have created separate areas (following all norms) for Intravitreal injections in the OPD to prevent disruption of OT workflow. If this is not possible, intravitreal injections should be given in the operation theatre
6. Longer acting drugs maybe preferred to reduce hospital visits.

### Follow-up after intravitreal injections

The main aim of follow-up is to ensure that the patient does not develop any post injection intraocular inflammation. Ideally, the patient may be called for review in 24-72 hours. However, in these COVID-19 times, patient can be asked to give a call next day. In case the patient is comfortable, he/she can be called after 4-8 weeks depending on the drug used and the disease process. Patient should also have the freedom to connect with the health care facility in case of any problem in-between.

## VI. Cleaning and maintenance of equipment and lenses: Special considerations

Contact Lenses for Laser and Examination: As mentioned previously, these should be avoided. If one needs to use them, the contact surface of the lens washed with detergent and running water for 20 seconds prior to applying it on the cornea, repeating the washing after the examination. The lens can be disinfected by immersing the contact surface in 0.5% sodium hypochlorite for 10 minutes after washing. Laser lenses can be covered with cling film that can be removed at the end of procedure [Fig. 4].

Lens for Indirect Ophthalmoscopy and slit lamp biomicroscopy: The condensing lens is washed with soap and water or wiped with 95-99.9% isopropyl alcohol between patients. Please refer to manufacturer's instructions for sterilization regarding the time of contact and also some may prohibit the use of alcohol. To minimize the risk of damaging the condensing lens, Shanmugam *et al.* have modified the lens

by mounting it on to a custom designed holder with a clear plastic barrier at the end facing the patient ([https://www.youtube.com/watch?time\\_continue=1&v=BC8DCTDkcg&feature=emb\\_title](https://www.youtube.com/watch?time_continue=1&v=BC8DCTDkcg&feature=emb_title)). This plastic barrier and the lens mount can be wiped with alcohol in between examinations.

**Slit Lamps, Lasers, OCT and OCTA:** Protecting the lens of these equipment from droplet contamination can be done by wrapping a cling film over the lens. The surface of the film is cleaned with an alcohol based disinfectant or is changed after every patient or the lens of the machine may be cleaned by the technique recommended by the manufacturer. Laser front lens too can be covered with cling film that allows reasonable quality of placement of laser burns [Fig. 5].

**Fundus Cameras:** Cling film causes compromise in image quality and thus fundus cameras can be left uncovered while the rest of the device is covered with cling wrap to allow for more frequent cleaning. The cleaning of the forehead band, chin rest, lens, the handles and the table which comes in contact with the patient has to be done with alcohol wipes routinely in between cases.

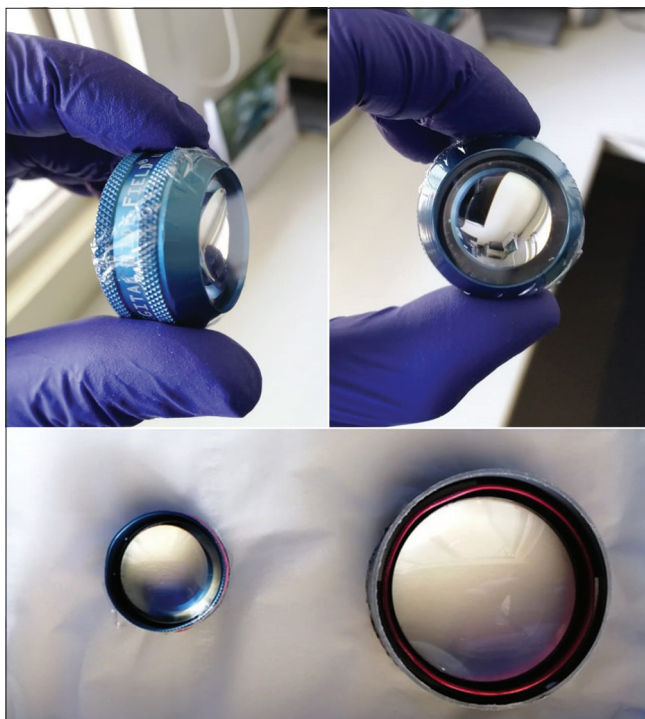
**Touch Screen Devices:** All touch screen devices also function well with a cling wrap

**B scan probe:** Since it is a contact procedure, please clean the probe with alcohol wipes between scans. A cap and mask should be worn by the patient while the procedure is being done with minimal or no patient contact.

**Electrophysiology:** Cleaning of equipment between patients, use of disposable electrodes and non-contact lens type.

### VII. Paediatric retina: Special considerations

Virtually all pediatric examinations and procedures are potential aerosol generating procedures (AGPs), therefore



**Figure 4:** Cling film to wrap the various ophthalmic lenses

the utmost care should be taken while managing these children.

Few extra precautions include:<sup>[10,11]</sup>

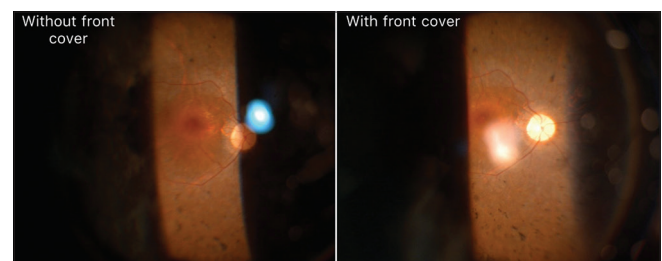
1. Only one person may be allowed to accompany the child for consultation
2. Since all children may not hold a mask on the face, social distancing becomes even more important
3. It is recommended to close the playing area for children in the OPD All the soft toys must be removed from the office as they can serve as potential fomites<sup>[10,12]</sup>
4. For a retina specialist seeing a regular OPD schedule, all children should be prioritised to maximize safety and efficiency
5. Home dilation is not encouraged in children because the examinations have to be staggered (within the pediatric group) and there may be variations in the schedule
6. Older children with documented 'stable' status can have non-contact wide-angle extended gaze fundus photographs (Optos/Clarus or Fundus photo-montage) wherever possible and it may avoid examination under anaesthesia (EUA) in many such patients, depending on physician discretion
7. Counselling the parents/other Neonatal Intensive Care Unit (NICU) staff must be done at a distance of 6 feet or more. This can be accomplished either in the same room or through tele-consultation via intercom/video call
8. EUAs for patients with ongoing care can be scheduled directly in the operating room (OR) list of the treating physician.

### VIII. ROP screening

New Standard operating procedures (SOP)s redefining Retinopathy of Prematurity management.

Unlike SOPs for other retinal conditions, Retinopathy of Prematurity (ROP) screening and treatment has some critical differences with respect to delay resulting in permanent blindness and medico-legal considerations for failing to execute the well-defined protocols.<sup>[12,13]</sup>

To address the issue of ROP management, the Indian Retinopathy of Prematurity (iROP) Society, has formulated guidelines in March 2020,<sup>[12]</sup> with the caveat that it is dynamic and requires to be customized for regional settings and in concurrence with evolving guidelines for COVID-19 management issued by the Government of India and other professional bodies. With the aim of reducing the number of screening visits and restricting them to have the highest yield of detection of vision threatening ROP, the following modification to the screening schedule are suggested and summarized in



**Figure 5:** Application of laser without cling film (left) and with cling film (right)

Table 2. Additionally, the following points may be kept in mind while dealing with these preterm babies:

1. Mothers with infants must maintain social distance while waiting for dilatation
2. The mother places the infant on a sanitized surface or table and moves more than 6 feet before the team approaches and handles the baby. The procedure is repeated for the next baby.
3. During counseling, social distancing norms must be maintained
4. Indirect ophthalmoscopy with 20 or 28 D lens or wide-field ROP cameras can be used and sanitized between babies as per the standard guidelines
5. Infant speculum and depressor if used must be single use or sanitized/autoclaved between babies
6. Tele-medicine must be encouraged.

#### ROP treatment modifications

The modifications to ROP treatment (outside early treatment for ROP (ETROP)) during this period are detailed in Table 3. Wherever possible, PPE prescribed by the ICMR must be used.

#### IX. Intraocular tumours and ocular metastasis

1. Prior assessment of fundus photographs and imaging studies in cases of suspected malignancy or an establish

case of treated intraocular tumour can be assessed over a video consultation for an initial assessment, and thereby help in reducing the consultation time when the patient is physically present in the clinic<sup>[14-16]</sup>

2. Patients with metastasis to the eye may be immunocompromised. These cases should be evaluated on an individual basis while assessing their visual potential for considering ocular treatment
3. Cases of intraocular lymphoma may continue to receive systemic chemotherapy and be brought in the clinic for periodic intraocular injections. Alternately, this can be arranged with the local retina specialist. Also, for such patients, converting the treatment to external beam radiation therapy (EBRT) may be considered. However, new patients suspected of vitreoretinal lymphoma must be promptly seen
4. EUA for newly suspected retinoblastoma and enucleation for retinoblastoma shall be performed within a week
5. EUA for children with active retinoblastoma undergoing treatment must follow continued care every 3-4 weeks. Systemic chemotherapy and focal consolidation/local ocular treatment can continue
6. EUA for children at high risk for retinoblastoma due to family history or known *RB1* mutation or with stable

**Table 2: Suggested ROP follow-up guidelines by the Indian ROP Society during COVID-19 restrictions**

Finding in either eye with respect to zone	Next follow up	Comment
Immature retina in zone 3 and zone 2 anterior	3-4 weeks or more	If the PMA is less than 34 weeks/ < 1500 grams / sick and admitted infant, consider a closer follow-up
ROP in Zone 3 and Zone 2 anterior	3-4 weeks	Spontaneously regressing ROP can be watched
ROP in Zone 2 Posterior	2 weeks	Unless associated with treatment requiring features (see below)
ROP in Zone 1	Urgent / less than a week / treat	Have a low threshold for treatment
Pre-plus	Consider early treatment or early follow-up if pupil does not dilate well and media is not clear	Individualize for each case based on the tempo of disease and PMA
Pre-plus	With good pupillary dilatation and clear media and other low risk features	Can delay the next screening by an additional 1 week from the current guidelines

**Table 3: Suggested ROP treatment guidelines by the Indian ROP Society during COVID-19 restrictions**

Disease	Comment
Type 1 ROP (ETROP)	Treat as soon as you possible, preferably on the day that screening was done. Laser recommended
Any Zone 1 disease	Consider treatment as soon as possible
Aggressive Posterior ROP / Hybrid ROP	Treat as soon as possible. Laser if disease is amenable. Intravitreal injections can be used, but caution to be exercised since follow-up may be a critical issue with travel restrictions for the family
"Less than Type 1 ROP" ROP Stage 2 with pre plus, ROP Stage 3 with no or early plus, high risk for APROP (but not yet full fledged), borderline Zone 1 disease / poor pupil dilatation, unclear media with pre-plus	Given the difficulty to closely follow-up consider treatment a 'little earlier' than classical Type 1 ROP
Stage 4A and 4B ROP	Surgery must be performed as soon as treating ROP specialist feels it is required with adequate precautions taken while providing anesthesia (as per prescribed guidelines)
Stage 5 ROP	Surgery is not urgent. Case-to-case based decision must be considered.

disease, who received treatment within the past 6 months can be performed within 1-2 months

7. Intraocular injection of chemotherapy agents for high-grade neoplasia (e.g., Rituximab/Methotrexate for Intraocular lymphoma) can be performed within 1-2 months
8. Systemic chemotherapy for adult patients with ocular metastasis may continue with the consultation of medical Oncologist.

#### X. Vitreo retinal (VR) surgery in post COVID era

It is emphasized that best practice protocols in VR surgery will be influenced by the practice situation of each facility and surgeon. These suggestions are advisory in nature and aim to provide means to achieve safe care in the best manner possible.

1. Preoperative COVID-19 Testing: Due to the difficulties around obtaining COVID-19 tests, the yield time and the presence of asymptomatic carriers, it is unlikely that every infected patient will be detected preoperatively. Hence, each surgeon and hospital administrator would be well advised to assume that every surgical patient is a potential COVID-19 spreader and the following practice patterns devolve from this premise.

- Emergency surgeries may be undertaken without mandating a COVID-19 test universally. A very strong suspicion, however, based on history or symptoms may prompt an urgent referral to a COVID-19 designated center
  - Definitively proven COVID-19 (Reverse transcription polymerase chain reaction (RT PCR)) positive patients should not be taken for ophthalmic surgery in non-designated COVID-19 centers
  - Asymptomatic patients, RT PCR negative patients and those who have not had the test done – all these patients are to be considered as potentially COVID-19 positive and all due precautions should be taken during surgery
  - Centres may consider mandating COVID-19 tests preoperatively in patients who have been in quarantine or have had people in their premises who have been in quarantine in the past one month.
2. Prioritization of Surgeries: The urgency of surgery should be an ophthalmologists' discretion taking into consideration the patient's clinical situation and the prevalent COVID-19 zone status and circumstances at that given time in their locale. Needless to say, emergency cases would take precedence and have to be prioritized for surgery at the earliest. The priority list for VR surgeries is detailed in Table 4, adapted from the recent AIOS – IJO publication.<sup>[1]</sup>
3. Operation Theater Engineering  
Since VR surgeries are prolonged, extra caution maybe required as the time of exposure to the surgeon and team is prolonged.

a. OT designation and flow: In Multispecialty hospitals, the designated surgical OT will be earmarked by the Hospital administration. In ophthalmic hospitals and clinics, the facility should designate a donning and doffing area for each OT. The doffing area should adjoin the OT but not be a considerable distance to avoid walking outside the OT in potentially contaminated garments. The donning of protective gear could be done in the usual washing area but will need adequate space. In case of surgeries under GA, the surgeon should not enter the OT until the patient is fully stabilized on the anesthesia circuit and the surgical team is adequately protected.<sup>[17]</sup>

b. OT Air conditioning:

- i. It is not a practical solution to switch off air conditioning in our environment. The consensus of this committee is that air conditioning should be operational during surgery with increased rate of air exchanges and increased ratio of fresh air mixing in the Air Handling Units (AHUs). Negative Pressure OTs are not considered mandatory and Positive Pressure OTs may continue to be used if it is not technically possible to convert to a negative pressure facility
- ii. If positive pressure air-conditioning is continued, care should be taken to switch off the air-conditioning momentarily at times of patient entry and exit<sup>[18]</sup>
- iii. Negative pressure OTs can be created within existing facilities by use of damper, altering fan speeds and various other engineering modifications. It is understood that this will be an adhoc modification that can only be tested up to the extent of a smoke test to confirm the presence of negative pressure in the OT. If an exhaust system is added, the exhausted air should be expelled after passing through a high-efficiency particulate air (HEPA) filter.<sup>[19,20]</sup>

4. Patient-related Protocols:

- a. Patients being operated should wear a surgical mask if being operated under local anesthesia. If the patient is uncomfortable, any device to keep the drapes away from the nose can be used. Under General anesthesia, the respiratory tract is isolated by the anesthesia circuit.
- b. It is all the more critical, in this COVID-19 period, to mandate that 5% Povidone iodine be instilled in the conjunctival sac 5-10 minutes before the surgery and also used for prepping. Povidone iodine is virucidal and disinfects the ocular surface and conjunctival cul-de-sac in 15 seconds.<sup>[21]</sup>

5. Personal protective equipment:

- a. The donning sequence differs significantly from that used for usual PPE wear in medical wards and clinics. The change in sequence is necessitated by the need to wear the N95 mask, boot covers and goggles before hand washing, so as to maintain sterility
- b. It is evident that coveralls are significantly difficult to wear in a sterile manner, therefore it is suggested that Gowns be worn for surgery, along with N95 masks, goggles and a hood and boot covers. Face shield are not easily compatible with surgery through a microscope; therefore, goggles are preferred and must be worn before the hood so that the hood fits nicely around the goggles and does not fall over the eyes. If the hood is worn first, it tends to ride over the eyes and the goggles then do not push it back. If any of the components of the PPE mentioned above are unavailable, a coverall can be used, and a sterile gown worn over it
- c. The doffing sequence is almost identical to standard protocols, but goggles can be reused after decontamination and N95 masks if reused on the same day must not be touched or reworn between cases. If an N95 with a respiratory valve is worn, it may be covered with a surgical mask which may also decrease the contamination on its surface
- d. We are aware that some institutions may modify the PPE made available to the surgical team depending



**Table 4: Prioritization of VR Surgeries**

Emergency Surgeries (Few Days)	Semi-emergency Surgeries (1-3 weeks)	Elective Surgeries ( $\geq 4$ weeks)
Acute retinal detachment	Acute full-thickness macular holes	Epiretinal membranes
Suspected retinal tears	Severe vitreomacular traction syndrome	Silicone oil removal (unless developing complications such as emulsification)
Open globe injuries: Including IOFB	Myopic traction maculopathy with foveal detachment	Secondary Intraocular lens Fixation procedures
Acute endophthalmitis	Heavy liquid removal	Symptomatic vitreous opacities
Vitreous hemorrhage (dense, requiring, vitrectomy)	Exposed scleral buckles at risk of infection	
Dropped nucleus requiring vitrectomy/lensectomy		
Submacular hemorrhage requiring vitrectomy		
Aqueous misdirection requiring vitrectomy		
Complex surgery post-operative (minimize visits)		
Diagnostic vitrectomy for infectious or oncological causes		
Surgery for ROP		
Drainage Surgery for appositional choroidal effusions, suprachoroidal hemorrhage or flat anterior chamber		

upon the perceived risk but urge that this be done with due deliberation after considering the consequences of inadequate protection.

#### 6. Sterilization Protocols and Re-use Practices:

There is no need to alter conventional preset institutional protocols regarding sterilization of the instruments that ideally should comply with the manufacturer's recommendations.

- It is preferable not to re-sterilize or reuse residual silicone oil and perfluorocarbon liquids
  - It is advisable to use a fresh bottle of Ringer Lactate or balanced salt solution (BSS)/BSS Plus for each case
- Sterile surgical consumables (trocar-cannulas, cutters, tubings, cassettes, endoilluminator, endolaser probes etc.) to be used in each case undergoing retinal surgery and all precautions to prevent cross-infection amongst consecutive surgical patients need to be stringently followed
- It has been suggested that using Ultraviolet (UV) light for 15 minutes after cleaning the OT, between cases, may have a beneficial effect.

#### 7. Surgical technique modifications:

- Draping: It is important to ensure that the draping is done properly. The edge of the drape should be adequately and properly stuck around the eye to create watertight sealing. This will minimize chances of aerosol dispersion from nose and mouth
- Post draping, the betadine maybe instilled into the conjunctival sac by using the syringe without cannula to minimize aerosol generation
- Valved vs. Non-valved cannulas: It is preferable to use valved cannulas as much of the fluid spills and bubbling during fluid air exchange may be avoided. Non-valved cannula system can cause spillage of fluid or air over the surgeon and assistant(s) especially with IOP controlled machines or a high bottle height. At present there is no substantial evidence to suggest presence or absence of virus in intraocular fluids. Hence, it is advised to avoid or minimize contact with intraocular fluid as far as possible and valved cannulas are recommended.
  - If a valved cannula system is not available, reduce the bottle height or intraocular pressure during instrument exchange to minimize sclerotomy leakage.

- Preferable to use viscoelastics over irrigation of eye to keep cornea wet.
- Non-contact viewing systems to be preferred over the contact systems.

d. Diathermy: A known source of aerosolization, any step needing diathermy should be considered carefully and a suction tubing used to evacuate the smoke from the surgical field<sup>[22]</sup>

e. Scleral Buckle vs. Vitrectomy: Scleral buckling involves more tissue contact and diathermy and would therefore be considered theoretically more of an aerosol generating procedure than vitrectomy which takes place in a closed chamber. At present there is no substantial evidence of COVID-19 transmission through blood or body fluids. The choice of procedure should be dictated primarily by the eye condition including patient age and lens status. Importance to be given to time and minimal intervention when choices are even

During a pars plana vitrectomy, the steps that merit care are prevention of fluid spill, prevention of high pressure bubbling at the ports or the flute needle during Fluid air exchange. This can be avoided by using active rather than passive aspiration. Minimize instrument exchanges as much as possible

f. Experienced surgeons should do the surgeries whenever possible. Over time, as protocols are crystallized, trainee surgeons would be expected to also operate.

#### 8. Resource management

- Due to the long hiatus and changed protocols, it is no longer advisable to operate more than one case at a time in one operation theatre
- Surgical camps should be deferred, and surgical times are likely to be prolonged due to the necessity to clean and decontaminate the OT after each surgery
- Also, expendables are likely to expire due to reduced caseloads and fresh supplies may not fructify due to broken supply chains. Therefore, inventory management at such a time assumes importance
- Extra items may be kept in in closed cupboards in the operation theatre to avoid a circulating nurse going back and forth to the instrument room. However, this will need to be balanced with keeping excess items in the OT which will result in all these extras being considered exposed

and needing decontamination after the OT. A suggested technique is to keep all the extra items in a common Ziploc bag or a transparent box so that the external surface of the box is cleaned after the procedure and every item does not then need to be individually wiped down if the box remains unopened during the surgery.

### XI. Financial impact of new SOPs

There is a genuine fear of an increased expenditure that would need to be incurred for the new set of SOPs. Also the patient inflow may decrease due to fear of traveling or visiting the hospital, reduced financial resources in the post-COVID-19 economy and decreased health care capacity. This can be overcome by increasing the number of working hours to compensate for reduced number of patients seen per hour as per physician's discretion, use of electronic medical records with automation wherever possible, online prepayment portal and pre-registration through online portals or WhatsApp. The additional cost including sanitization, cleaning, providing 3-ply mask to patient and PPE as per guidelines to ophthalmologists has been calculated to be about Rs 88/patient. This includes the cost of sanitizer: Rs. 16/- (for patient and attendant) +Rs. 16/- for cleaning instruments +Rs. 16/- for cleaning floors and fomites +Rs. 40/- cleaning person salary. The cost of face shields (varies from Rs 75/- to 200/-), and goggles (100/- to 300/-) is a one time. The estimate of the added cost can be demystified and remove the fear in peoples' minds. Thus, the potential extra cost per patient is an estimated Rs. 88/- that can be added to the consultation fee with added precautions. This is then likely to be completely revenue neutral. These estimates are being provided as a useful yardstick and may be variable.

### XII. Telemedicine and artificial intelligence (AI) for retinal disorder screening: Expanding role in post COVID-19 era

Telemedicine and artificial intelligence (AI) are two of the promising aspects of retina practice evolving in the recent years which can provide safer alternatives over conventional examination in various case scenarios in the post COVID-19 era.<sup>[23-29]</sup>

The utility of telemedicine has been well established for screening of DR, AMD and ROP.<sup>[24-29]</sup> A wide variety of non-mydratic fundus cameras have been in use with varying efficacy as far as image quality and field is concerned.<sup>[23]</sup> In the current scenario, hospitals can promote more of screening through telemedicine in order to avoid congestion and unnecessary hospital visits at tertiary eye care centers. Depending on the available resources, hospitals can install suitable fundus cameras and arrange for online consultation with retina specialists. Non-mydratic ultra-wide field cameras like Optos or Clarus can help detect a wide variety of retinal pathologies, apart from DR, ARMD and ROP, although cost can be a factor for their installation by general ophthalmologists.<sup>[28]</sup> Tertiary eye care centers which lack ROP screening through telemedicine can establish the same based on highly successful existing models.<sup>[24]</sup>

A lot has been done in the recent past to explore the utility of AI in enhancing the efficacy of telemedicine. Conventional machine learning has facilitated recognition of abnormalities like macular edema, exudates, cotton-wool, microaneurysms, neovascularization on optic disk, drusens and geographic

atrophy.<sup>[27]</sup> Deep learning algorithms have brought higher sensitivity and specificity in diagnosing retinal pathologies with higher accuracy. However, most of them need validation in larger patient cohorts.<sup>[27]</sup>

Chatbot, which uses a field of AI called natural language processing, can be yet another way of bringing AI to our aid in the current scenario to avoid the burden of routine questions from patients' phone calls, and also to ease the task of triaging patients who need urgent visit at a retina clinic.<sup>[29]</sup> It has the potential to resolve minor issues and complaints of many retina patients, who then need not make a hospital visit, once their queries are resolved on Chatbot. It can be developed by the individual hospitals with appropriate technical support on various available platforms and can cover a wide range of topics, right from the various ocular complaints suffered by the patient to the possible diagnosis and its seriousness. It also provides the necessary patient details as the patients answer to the questionnaires and the patients can be directed to online consultation or appointment, if the need be so, based on their response to the questionnaires. Consultation through video-conferencing can also be a useful way to re-assure post-operative patients and routine patients of retina clinic with minor issues.<sup>[1]</sup> Recently, the government has given the guidelines for telemedicine making it all the more legal and also encouraging its use especially in this crisis period.<sup>[30]</sup>

### XIII. Managing uveitis in post-COVID-19 era

General ophthalmologists as well as uveitis specialists are now faced with the dilemma about the usage of steroid and immunosuppressive agents. There are no published guidelines so far regarding this. The following consensus is being accepted by the International uveitis study group (IUSG), International Ocular Inflammation Society (IOIS) and Foster Ocular Inflammation Society (FOIS) have jointly released an evolving consensus experience with uveitis at the time of COVID-19 infection (latest version April 3<sup>rd</sup> 2020).<sup>[31]</sup>

Few specific points about Uveitis management:

- A. Anterior uveitis: Topical steroids may be started or continued at the discretion of the treating doctor
- B. Intermediate uveitis/posterior uveitis/panuveitis

#### 1. Guidelines for a new patient of uveitis:

- To prefer local therapy in the form of posterior sub-tenon triamcinolone or intravitreal dexamethasone implant over systemic corticosteroids
- Intravenous methyl prednisolone is best avoided and one should prefer local therapy (periocular or intravitreal steroids) alone or in combination with lower doses of systemic steroids
- Avoid starting high dose oral corticosteroids or immunosuppressants in high risk patients defined as the following: age  $\geq 70$  years, severe chronic lung disease (e.g., asthma, bronchiectasis, cystic fibrosis, chronic obstructive pulmonary disease (COPD), etc.), severe heart disease, CD4 count  $< 200$ , history of diabetes/hypertension/smoking/cardiovascular event
- Any one-eyed patient or one with a vision threatening condition requiring the initiation of corticosteroids or immunosuppressants maybe started on the treatment at the discretion of the treating doctor and after evaluation by a physician

- Strict vigilance has to be kept on the blood counts of the patient with a special precaution to maintain white blood count is kept above >4000 per microliter.
2. The COVID-19 pandemic is not a contraindication for the initiation of immunosuppressants. Patients need to be explained regarding the additional risk of secondary infections at the time of start of the therapy including the following precautions:
    - Hand and personal hygiene.
    - Avoiding crowds and working from home
    - To have the face mask on at all times
    - If they are sick with fever, malaise then should contact the infection control specialist and if advised then to consider stopping the therapy.
  3. Guidelines for uveitis patients on maintenance therapy
    - a. On Corticosteroids
      - Patient is stable then one may consider a gradual taper and stopping of the drug or maintain at a low dose <10 mg/day. However if there is a high risk of recurrence at it might be vision threatening then one may continue at the same dosage (as per the discretion of the treating doctor)
      - Strict monitoring of blood sugar and blood pressure is recommended
      - In case of any illness or symptoms suspicious of COVID-19 then to be referred to an infection control clinic
      - In a case of recurrence, then to prefer local therapy (sub-tenon or intravitreal) over systemic corticosteroids.
    - b. On Immunosuppressants
      - i. Patient with systemic immunosuppression without sign of COVID-19 infection or negative with COVID-19 test:
        - If the patient has been stable for the last two visits and one was considering the stoppage of the drugs then it may be done at the discretion of the treating doctor however they do not need to be discontinued due to COVID-19 pandemic
        - In addition, they should strictly follow the precautions like a) staying at home as much as possible b) practice social distancing approximately 6 feet from other individuals c) wearing a mask d) washing hands frequently with soap or alcohol based sanitizer. If such patients feel sick they should contact their doctor immediately
        - Patients on immunosuppressants are already primed to monitor their blood counts regularly, however we may need to reiterate the importance of the same again
        - Strict vigilance has to be kept on the blood counts of the patient with a special precaution to maintain white blood count is kept above >4000 per microliter and tele consultation maybe useful for the same
        - A patient on immunosuppressant if develops symptoms suspicious of COVID-19 infection, then needs to be referred to infection control specialist and if they feel necessary to stop the ongoing medication, it may be done at their discretion.
      - ii. Patient with systemic immunosuppression in either confirmed COVID-19 infection or clinical signs of COVID-19 infection
        - These patients should not be denied of treatment. If the patient is asymptomatic, they may continue with

immunosuppressive agents along with monitoring of blood counts under the close monitoring of infectious disease expert

- Symptomatic patients should temporarily stop immunosuppressive agents or biologics. Patients taking anti Tumor necrosis factor (TNF) agents like infliximab or adalimumab should omit their next dose until they fully recovered. In such cases local treatment options like intravitreal injection should be considered
- It is to be remembered that patients with immunosuppressive agents will have altered blood parameters like decrease of lymphocyte count, decrease albumin, decrease haemoglobin, increase C- reactive protein, increased erythrocyte sedimentation rate (ESR), increased lactate dehydrogenase (LDH) and increase D-dimer.

Patients on tocilizumab may be continued on the same as it reduces the cytokine storm.

Standard precautions should be followed in uveitis patients like other ophthalmic patients in this COVID-19 pandemic.

#### XIV: Training of the residents, fellows and students during the COVID-19 pandemic

As training the residents and post-graduates is one of the integral component of medicine, special attention needs to be given to the potential deficit in conventional training opportunities for the students during this COVID-19 era. New norms need to be established to train the residents and fellows. Innovative methods focussed training through webinars, online didactics, case presentations, review of electronic medical records may be considered as means of imparting teaching and engaging students.

### Conclusion

To conclude, our practices are going to be different in the post-COVID-19 era and we have to make modifications in every way that suits our practice, taking the government regulations and local rules under consideration. It is important to keep training the staff on a regular basis, so that we are able to manage these patients in a safe environment and prevent ocular morbidity as much as possible.

#### Acknowledgement

We would like to acknowledge AIOS governing Council Dr. Mahipal Sachdev, Prof Namrata Sharma, Dr. Partha Biswas, Dr. Chitra Ramamurthy and Prof Rajesh Sinha for their help in formulating these guidelines.

#### Declaration of patient consent

The authors certify that they have obtained all appropriate patient consent forms. In the form the patient(s) has/have given his/her/their consent for his/her/their images and other clinical information to be reported in the journal. The patients understand that their names and initials will not be published and due efforts will be made to conceal their identity, but anonymity cannot be guaranteed.

#### Financial support and sponsorship

Nil.

## Conflicts of interest

There are no conflicts of interest.

## References

- Sengupta S, Honavar SG, Sachdev MS, Sharma N, Kumar A, Ram J, *et al.* All India Ophthalmological Society – Indian Journal of Ophthalmology consensus statement on preferred practices during the COVID-19 pandemic. *Indian J Ophthalmol* 2020;68:711-24.
- ASRS Emergent Urgent OR procedures. Available from: <https://www.asrs.org/content/documents/asrs-emergenturgentorprocedures.1.pdf>. [Last accessed on 2020 May 08].
- Chodosh J, Holland GN, Yeh S. Important coronavirus updates for ophthalmologists. Available from: <https://www.aao.org/headline/alert-important-coronavirus-context>. [Last accessed on 2020 Apr 04].
- Romano MR, Montericchio A, Montalbano C, Raimondi R, Allegrini D, Ricciardelli G, *et al.* Facing COVID-19 in Ophthalmology Department. [published online ahead of print 2020 Apr 23]. *Curr Eye Res* 2020;23:1-6.
- VRSI Webinar on Retina Practice Guidelines in the COVID 19 Era. Available from: <https://vrsi.in/webinar/webinar-retina-practice-guidelines-in-the-covid-19-era/>. [Last accessed on 2020 May 08].
- Eggers M. Infectious disease management and control with povidone iodine. *Infect Dis Ther* 2019;8:581-93.
- Honavar SG, Sharma N, Sachdev MS for the Governing Council of the All India Ophthalmological Society. AIOS-Operational-Guidelines-COVID19. Available from: <https://aios.org/pdf/AIOSOperational-Guidelines-COVID19.pdf>. [Last accessed on 2020 May 05].
- Schmidt-Erfurth U, Lang GE, Holz FG, Schlingemann RO, Lanzetta P, Massin P, *et al.* RESTORE Extension Study Group. Three-year outcomes of individualized ranibizumab treatment in patients with diabetic macular edema: The RESTORE extension study. *Ophthalmology* 2014;121:1045-53.
- Rosenfeld PJ, Brown DM, Heier JS, Boyer DS, Kaiser PK, Chung CY, *et al.* MARINA Study Group. Ranibizumab for neovascular age-related macular degeneration. *N Engl J Med* 2006;355:1419-31.
- Abusive head trauma/shaken baby syndrome. Available from: <https://www.aao.org/clinical-statement/abusive-head-traumashaken-baby-syndrome>. [Last accessed on 2020 May 08].
- AAP Critical Updates on COVID 19. Available from: <https://services.aap.org/en/pages/2019-novel-coronavirus-covid-19-infections/#Information>. [Last accessed on 2020 May 04].
- Vinekar A, Azad RV, Dogra MR, Jalali S, Bhende P, Narendran V, *et al.* for the Indian Retinopathy of Prematurity Society. Retinopathy of prematurity screening and treatment guidelines during the COVID-19 lockdown 2020. Available from: <https://sites.google.com/view/iropsociety/newsroom?authuser=0>. [Last accessed on 2020 May 05].
- Project operational guidelines. Prevention of Blindness from Retinopathy of Prematurity in Neonatal Care Units. Available from: <https://phfi.org/wp-content/uploads/2019/05/2018-ROP-operational-guidelines.pdf>. [Last accessed on 2019 May 21].
- AAO Important coronavirus updates for ophthalmologists. Available from: <https://www.aao.org/headline/alert-important-coronavirus-context>. [Last accessed on 2020 May 04].
- Skalet AH, Allen RC, Shields CL, Wilson MW, Mruthyunjaya P, Gombos DS. Considerations for the management and triage of ocular oncology cases during the COVID-19 Pandemic. *Ocul Oncol Pathol* 2020;6:219-22.
- American Association of Ophthalmic Oncologists and Pathologist. Available from: <http://www.aaoop.org/corona-virus/>. [Last accessed on 2020 May 04].
- Wong, J, Goh QY, Tan Z, Lie Sa, Tay YC, Ng SY, *et al.* Preparing for a COVID-19 pandemic: A review of operating room outbreak response measures in a large tertiary hospital in Singapore. [published online ahead of print 2020 Mar 11] *Can J Anesth* 2020. doi: 10.1007/s12630-020-01620-9.
- Brücher BL, Nigri G, Tinelli A, Lapeña JFF, Espin-Basany E, Macri P. *et al.* COVID-19: Pandemic surgery guidance. 4 open 2020 (3):1. Accessed online on 13 May 2020.
- Park J, Yoo SY, Ko J, Lee SM, Chung YJ, Lee JH, *et al.* Infection prevention measures for surgical procedures during a middle east respiratory syndrome outbreak in a tertiary care hospital in South Korea. *Sci Rep* 2020;10:325.
- Chow TT, Kwan A, Lin Z, Bai W. Conversion of operating theatre from positive to negative pressure environment. *J Hosp Infect* 2006;64:371-8.
- Eggers M, Eickmann M, Zorn J. Rapid and effective virucidal activity of povidone-iodine products against middle east respiratory syndrome coronavirus (MERS-CoV) and modified vaccinia virus Ankara (MVA). *Infect Dis Ther* 2015;4:491-501.
- Coccolini F, Perrone G, Chiarugi M, Di Marzo F, Ansaloni L, Scandroglio I, *et al.* Surgery in COVID-19 patients: Operational directives. *World J Emerg Surg* 2020;25. doi: 10.1186/s13017-020-00307-2.
- Saha SK, Fernando B, Cuadros J, Xiao D, Kanagasigam Y. Automated quality assessment of colour fundus images for diabetic retinopathy screening in telemedicine. *J Digit Imaging* 2018;31:869-78.
- Adams MK, Date RC, Weng CY. The emergence of telemedicine in retina. *Int Ophthalmol Clin* 2016;56:47-66.
- Lim G, Bellemo V, Xie Y, Lee XQ, Yip MYT, Ting DSW. Different fundus imaging modalities and technical factors in AI screening for diabetic retinopathy: A review. [published online ahead of print 2020 Apr 14]. *Eye Vis (Lond)* 7:21. doi: 10.1186/s40662-020-00182-7.
- Ting DS, Pasquale LR, Peng L, Campbell JP, Lee AY, Raman R, *et al.* Artificial intelligence and deep learning in ophthalmology. *Br J Ophthalmol* 2019;103:167-75.
- Lu W, Tong Y, Yu Y, Xing Y, Chen C, Shen Y. Applications of artificial intelligence in ophthalmology: General overview. *J Ophthalmol* 2018;2018:5278196. doi: 10.1155/2018/5278196.
- Nagiel A, Lalane RA, Sadda SR, Schwartz SD. Ultra-widefield fundus imaging: A review of clinical applications and future trends. *Retina* 2016;36:660-78.
- Bibault JE, Chaix B, Guillemassé A, Cousin S, Escande A, Perrin M, *et al.* A chatbot versus physicians to provide information for patients with breast cancer: Blind, randomized controlled noninferiority trial. *J Med Internet Res* 2019;21:e15787.
- AIOS Governing Council. AIOS Telemedicine Practice Guidelines. Available from: <https://aios.org/pdf/AIOS-Telemedicine-PracticeGuidelines.pdf>. [Last accessed on 2020 Apr 04].
- Evolving Consensus Experience of the IUSG-IOIS-FOIS with Uveitis in the Time of COVID-19 Infection. Available from: [www.iusg.net/library](http://www.iusg.net/library). [Last accessed on 2020 April 03].