

Recurrent Intra Articular Osteochondroma of Left 4th Finger

Abstract

Osteochondromas are common benign bone tumors arising from metaphyseal region of long bones. They are notorious for undergoing malignant transformation. We present a case of a middle aged woman with recurrent episodes of swelling in the middle of left 4th finger post excision. Bone scan was performed to look for any malignant transformation of finger lesion and also to rule out skeletal metastases due to recent onset bone pains. ^{99m}Tc MDP (Technetium methylene diphosphonate) bone scan demonstrated a focal hot spot in middle of left 4th finger along the radial side. There was no evidence of skeletal metastases. Surgery is usually curative (70-90%). Limb sparing wide local excision is treatment of choice.

Keywords: ^{99m}Tc MDP bone scan, osteochondroma, recurrent phalangeal swelling

Case Summary

47-year-old lady presented to her family physician with recurrent protuberant swelling in the middle of the left 4th finger. Patient had similar swellings in the same location that were excised on two occasions (11 years and 5 years ago). No histopathology details were available. This swelling was slow-growing in nature and developed at the postoperative site [Figure 1a], 8 months ago with gradual increase in its size. Lesion is non tender, pedunculated, measures 7 cm × 5 cm, firm, with no joint immobility. No congenital bone deformity of phalanges noted. Three phase regional and whole-body ^{99m}Tc MDP (Methylene diphosphonate) bone scan was performed specifically to look for its malignant potential. SPECT CT (Single-photon emission computed tomography/computed tomography) showed focal intense tracer uptake in the left 4th finger at the mid region corresponding to the osseous exophytic mass from the radial aspect probably arising from the epiphyseal plate, not involving the metacarpophalangeal joint [Figure 1b-e].

Discussion

Osteochondroma is one of the most common benign bone tumors, frequently occurring in the metaphysis of the long bones.^[1] It is also

known as osteochondromatous exostosis. Osteochondroma is a cartilage-forming tumor and arises from an aberrant subperiosteal cartilage.^[2] It is thought to be a developmental disorder (pseudotumoral lesion) or a neoplasm, but it is certainly an exostosis (external bone proliferation deforming the bone). Usually, they are intra-articular in origin and arise in the distal end of the phalanges opposite the epiphyseal growth area. The common sites of involvement are in long bones, such as proximal and distal femur, proximal humerus, proximal tibia, pelvis, and scapula.^[3] They may be sessile or pedunculated and develop in the half side of the phalanges, either the ulnar or radial side. They may be solitary or multiple; the latter being associated with the autosomal dominant syndrome, hereditary multiple exostoses.^[4] Mutation in EXT gene is also thought to affect prehypertrophic chondrocytes of growth plate leading to osteochondroma. The most common symptom being nontender, painless cosmetic deformity related to the slowly enlarging exophytic mass. Additional complications that cause symptoms include osseous deformity, fracture, vascular compromise, neurologic sequelae, overlying bursa formation, and malignant transformation. Malignant transformation is the most feared sequelae of osteochondroma. It occurs in approximately 1% of solitary lesions and was first reported in 1886.^[5] Recurrence rate of

**Shanmuga
Sundaram
Palaniswamy,
Padma
Subramanyam**

*Department of Nuclear Medicine
and Molecular Imaging, Amrita
Institute of Medical Sciences,
Amrita Vishwa Vidyapeetham
University, Kochi, Kerala, India*

Address for correspondence:

*Dr. Padma Subramanyam,
Department of Nuclear Medicine
and Molecular Imaging, Amrita
Institute of Medical Sciences,
Amrita Vishwa Vidyapeetham
University, Kochi - 680 2041,
Kerala, India.
E-mail: drpadmasundaram@
gmail.com*

Received: 28-10-2021
Revised: 29-11-2021
Accepted: 30-11-2021
Published: 08-07-2022

Access this article online

Website: www.ijnm.in

DOI: 10.4103/ijnm.ijnm_169_21

Quick Response Code:



How to cite this article: Palaniswamy SS, Subramanyam P. Recurrent intra articular osteochondroma of left 4th finger. Indian J Nucl Med 2022;37:204-5.

This is an open access journal, and articles are distributed under the terms of the Creative Commons Attribution-NonCommercial-ShareAlike 4.0 License, which allows others to remix, tweak, and build upon the work non-commercially, as long as appropriate credit is given and the new creations are licensed under the identical terms.

For reprints contact: WKHLRPMedknow_reprints@wolterskluwer.com

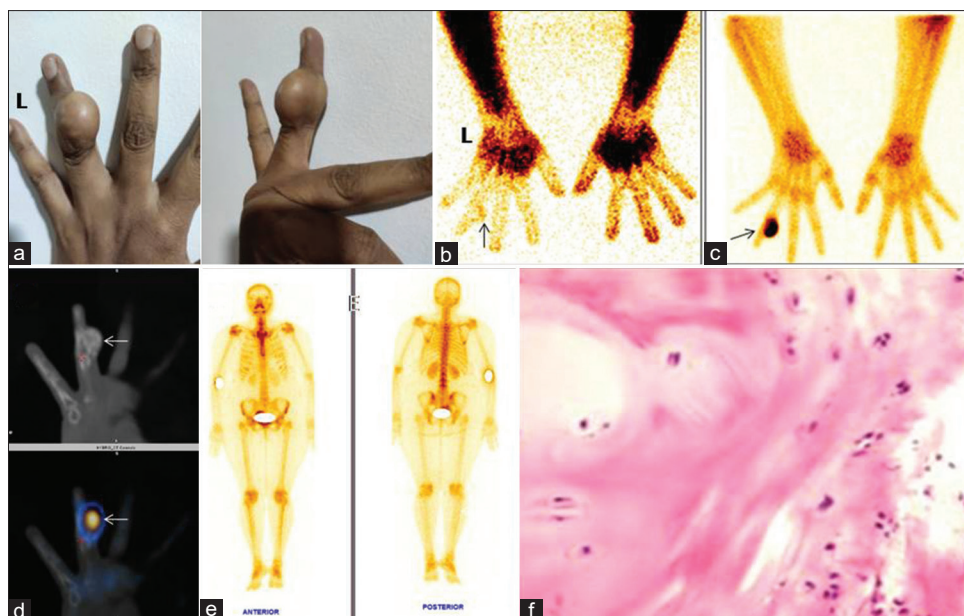


Figure 1: (a) Mass lesion in the left 4th finger mid region (b) Three phase ^{99m}Tc MDP bone scan-soft tissue phase images of hands show a subtle soft-tissue tracer uptake in the left 4th finger (arrow) (c) Skeletal phase image shows focal hotspot in the left 4th finger along the radial side (arrow) (d) Computed tomography and fused SPECT CT exhibits a focal intense tracer uptake in left 4th finger corresponding to the osseous exophytic mass from the radial aspect probably arising from epiphyseal plate, not involving the metacarpophalangeal joint. (e) ^{99m}Tc MDP Whole body bone scan shows no skeletal metastasis (f) Histology: Osteochondroma, cartilage cap with endochondral ossification

osteochondroma is varied and up to 30% has been reported in patients with femoral involvement.^[6] Most common three sites of local recurrence were the proximal tibia, distal femur, and proximal humerus. Tong *et al.* reported a local recurrence rate of osteochondroma of 8.12% with an interval of 27 months from first detection.^[3] The importance of bone scan in osteochondromas is directly correlated with the degree of enchondral bone formation. Increased tracer uptake is noted in osteochondromas affecting younger patients. It is found to be quiescent (no increased MDP uptake) in older patients,^[7] The first choice of treatment especially for solitary osteochondromas is surgery but can recur in the presence of open epiphyseal growth plates.^[7] Our patient also underwent excision of mass with histological confirmation of osteochondroma [Figure 1f]. Bone scan is incremental in further characterizing the bone lesion, to look for any malignant transformation also to rule out skeletal metastases.

Financial support and sponsorship

Nil.

Conflicts of interest

There are no conflicts of interest.

References

1. Tepelenis K, Papathanakos G, Kitsouli A, Troupis T, Barbouti A, Vlachos K, *et al.* Osteochondromas: An updated review of epidemiology, pathogenesis, clinical presentation, radiological features and treatment options. *In Vivo* 2021;35:681-91.
2. Motamedi K, Seeger LL. Benign bone tumors. *Radiol Clin North Am* 2011;49:1115-34, v.
3. Tong K, Liu H, Wang X, Zhong Z, Cao S, Zhong C, *et al.* Osteochondroma: Review of 431 patients from one medical institution in South China. *J Bone Oncol* 2017;8:23-9.
4. Lange RH, Lange TA, Rao BK. Correlative radiographic, scintigraphic, and histological evaluation of exostoses. *J Bone Joint Surg Am* 1984;66:1454-9.
5. Gunderman RB. *Essential Radiology: Clinical Presentation-Pathophysiology, Imaging*. 2nd ed. New York: Thieme Medical Publishers, Inc.; 2006.
6. de Souza AM, Bispo Júnior RZ. Osteochondroma: Ignore or investigate? *Rev Bras Ortop* 2014;49:555-64.
7. Lawrance SE. Recurrent pendunculated osteochondroma of the tibia. *Radiol Case Rep* 2015;10:1096.