

SHORT REPORT

Open Access



# Spindle cell variant of medullary thyroid carcinoma: a clinicopathologic study of four cases

Yan Xia Wang and Shou Jing Yang\*

## Abstract

**Background:** Medullary thyroid carcinoma (MTC) is a malignant tumor derived from C cells. It accounts for about 10% of all thyroid malignancies. More than 14 histological variants have been described. Among them, spindle cell variant is extremely rare.

**Case presentation:** Here we describe 4 cases of spindle cell variant of MTC collected from 2012 to 2019. Ultrasound showed solid and hypoechoic nodules. Three patients underwent total thyroidectomy and regional lymph node dissection, and 1 patient underwent thyroid mass resection. Histologically, the tumors showed spindle shaped cells in bundles or interlaced arrangement, separated by hyalinised fibrous stroma that contained amyloid deposits. Immunohistochemistry showed that the tumor cells were positive for calcitonin, chromogranin A, synaptophysin, CD56, and TTF-1, but negative for other lineage-specific markers.

**Conclusions:** We report 4 rare cases of spindle cell variant of MTC. Due to its rarity and special morphology, the diagnosis of spindle cell variant MTC relies on its morphology and immunohistochemical markers to avoid misdiagnosis.

**Keywords:** Spindle cell, Thyroid carcinoma, Morphology, Immunophenotype

## Background

Medullary thyroid carcinoma (MTC) is a malignant tumor with neuroendocrine characteristics, originated from parafollicular C cells secreting calcitonin. It accounts for 5 to 10% of all thyroid malignancies. Most patients are asymptomatic with lymph node metastasis in the early stage or distant metastasis in the later stage, and its mortality accounts for 13.4% of all thyroid malignancies. More than 14 histological subtypes of MTC have been described in current WHO classification. Spindle cell variant MTC is a rare variant, and only 5 cases have been reported to date [1–5]. It is easy to mistake for other lesions due to its rarity and spindle cell

morphology. Here we report 4 cases of MTC with predominantly spindle cell pattern in clinical and pathological features to enhance understanding of this type of MTC.

## Materials and methods

### Case presentation

Four cases of spindle cell variant MTC were collected from 2012 to 2019, including 2 males and 2 females, aged 26 to 54 years old. Patients visited hospital with the accidental discovery of painless neck mass accompanied by gradual enlargement. On clinical examination, mass was diffuse and firm, moving with deglutition. Family history was unremarkable. Biochemical examination showed normal serum parathormone level. Thyroid function test was within normal range. Ultrasound showed solid and hypoechoic nodules of 2~6 cm in

\* Correspondence: yangsj@fmmu.edu.cn

Department of Pathology, Xijing Hospital, 4th Military Medical University, No. 169 Chang Le Xi Road, Xi'an 710032, Shaanxi, China



© The Author(s). 2021 **Open Access** This article is licensed under a Creative Commons Attribution 4.0 International License, which permits use, sharing, adaptation, distribution and reproduction in any medium or format, as long as you give appropriate credit to the original author(s) and the source, provide a link to the Creative Commons licence, and indicate if changes were made. The images or other third party material in this article are included in the article's Creative Commons licence, unless indicated otherwise in a credit line to the material. If material is not included in the article's Creative Commons licence and your intended use is not permitted by statutory regulation or exceeds the permitted use, you will need to obtain permission directly from the copyright holder. To view a copy of this licence, visit <http://creativecommons.org/licenses/by/4.0/>. The Creative Commons Public Domain Dedication waiver (<http://creativecommons.org/publicdomain/zero/1.0/>) applies to the data made available in this article, unless otherwise stated in a credit line to the data.

diameter. Two cases occurred in the left lobe of thyroid, and another 2 cases occurred in the right lobe of thyroid, including 1 case with gravelly calcification and 1 case with ipsilateral lymph node metastasis.

## Methods

The tissue samples were fixed with 10% neutral formalin and embedded in paraffin. Tissue sections of 4~5 μm thickness were prepared and stained with hematoxylin and eosin (H&E), and additional sections were stained with Congo red. Immunohistochemical staining was performed using Dako EnVision Peroxidase detection system on Roche Ventana Benchmark XT autostainer (Ventana Medical Systems, Tucson, AZ). The primary antibodies panel consisted of calcitonin (CT) (clone SP17, Ready-to-Use), chromogranin A (CgA) (SP12, Ready-to-Use), synaptophysin (Syn) (SY38, 1:100), CD56 (1B6, 1:50, Novocastra, Newcastle upon Tyne, UK), TTF-1 (SPT24, prediluted), Thyroglobulin (TG) (2H11 + 6E1), Ki-67 (MIB-1, 1:100), carcinoembryonic antigen (CEA) (12-140-10, Ready-to-Use), cytokeratin (AE1/AE3, Ready-to-Use), epithelial membrane antigen (EMA) (E29, 1:100), vimentin (V9, 1:100), desmin (D33, 1:160), alpha-smooth muscle actin (SMA) (IA4, 1:100, Dako), HMB45 (HMB-45, 1:50), S-100 protein (polyclonal, 1:200), HBME-1 (HBME-1, Ready-to-Use), galectin-3 (9C4, Ready-to-Use), CK19 (A53-B/A2.26, Ready-to-Use), and CD99 (12E7, 1:50). Unless otherwise stated, all antibodies were mouse monoclonal and from DAKO Corporation (Dako North America, Inc., Carpinteria, CA, USA). Appropriate positive and negative controls were run in parallel.

## Results

### Pathological morphology

The clinicopathological features of patients are summarized in Table 1. Grossly, the mass of the four patients had clear boundary, 2~6 cm in diameter, solid shape, soft texture and grayish-white or grayish-brown in color.

Among them, the capsule of the tumor was intact in 3 patients, and incomplete in 1 patient.

Histological examination of the specimens showed that the tumors consisted predominantly of monomorphic spindle cells, arranged in fascicles or interweaves (Fig. 1a), separated by fibrovascular or amyloid stroma (Fig. 1b). Tumor cells showed short or long spindle nuclei, abundant cytoplasm, inconspicuous nucleoli and rare mitoses (Fig. 1c). The boundary between tumor tissue and peripheral thyroid tissue was clear.

### Congo red amyloid stain

Tumor tissue were positive (3/3) for Congo red staining.

### Immunohistochemistry

The immunohistochemical results are summarized in Table 1. The tumor cells were positive for CT (Fig. 2a), CgA (Fig. 2b), Syn (Fig. 2c), CD56 (Fig. 2d), and TTF-1 (Fig. 2e) in all 4 cases. In addition, the tumor cells were also positive for AE1/AE3 (2/2), CEA (3/3), EMA (1/1) and vimentin (2/2). Other markers such as TG, Desmin, SMA, S-100, galectin-3, CK19, HBME-1, and CD99 were negative. The Ki-67 proliferative index of these tumors ranged approximately 3%~10% (Fig. 2f).

### Treatment and follow-up

Three patients underwent total thyroidectomy and regional lymph node dissection, and 1 patient underwent thyroid mass resection. After a follow up of 7~84 months, all four patients were alive.

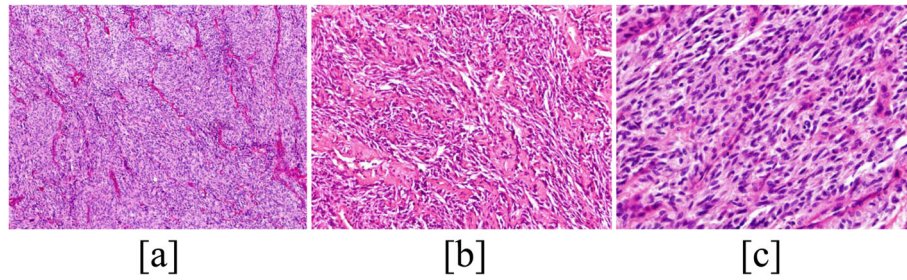
## Discussion

Spindle cell variant MTC is a rare type of MTC, and only 5 cases have been reported in literatures thus far [1-5]. We reviewed 99 cases of MTC confirmed in our hospital from 2012 to 2019, only 4 cases spindle cell variant MTC meet the criteria, accounting for 4% of all MTC.

**Table 1** Clinicopathological variables of patients with spindle cell variant of medullary thyroid carcinoma

Case	Sex	Age	Tumor site	Tumor size (cm)	Histological type	Immunophenotype	Recurrence	Follow-up (months)	Status
1	F	54	LLT	2 × 2 × 2.5	spindle cell variant MTC	CT+, CgA +, Syn+, CD56+, TTF-1+, TG-, AE1/AE3+, Ki-67+ (5%)	-	60	Alive
2	M	26	RLT	6 × 3 × 3	spindle cell variant MTC	CT+, CgA +, Syn+, CD56+, TTF-1+, TG-, CEA+, AE1/AE3+, SMA-, S-100-, HMB45-, CD99-, Ki-67+ (5%)	-	7	Alive
3	F	49	LLT	4 × 2 × 2	spindle cell variant MTC	CT+, CgA +, Syn+, CD56+, TTF-1+, TG-, CEA+, vimentin+, SMA-, S-100-, HBME-1-, galectin-3-, CK19-, Ki-67+ (3%)	-	84	Alive
4	M	51	RLT	2.4 × 1.6 × 2.2	spindle cell variant MTC	CT+, CgA +, Syn+, CD56+, TTF-1+, TG-, CEA+, EMA+, vimentin+, SMA-, S-100-, HBME-1-, Ki-67+ (10%)	-	72	Alive

Abbreviations: F female, M male, LLT the left lobe of thyroid, RLT the right lobe of thyroid, MTC Medullary thyroid carcinoma

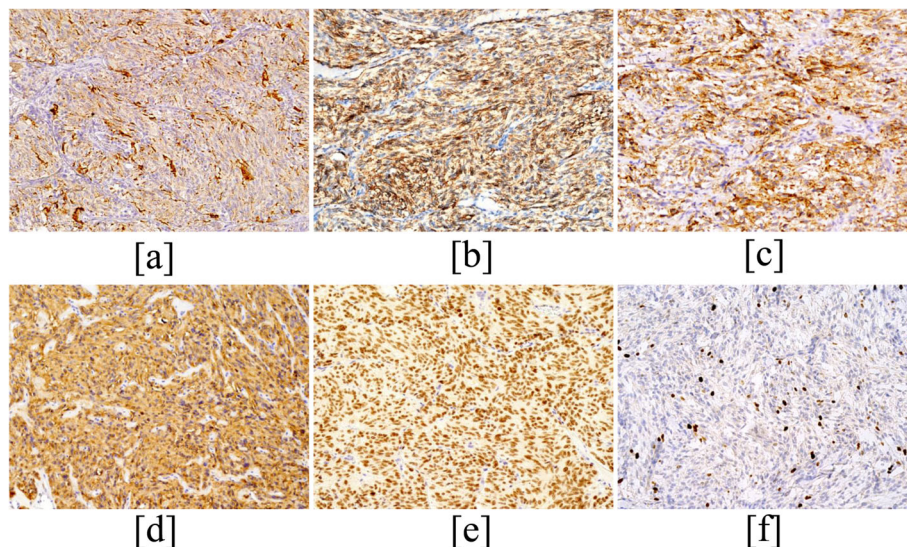


**Fig. 1** Histological findings. Tumor show predominantly monomorphic spindle cells, arranged in fascicles or interweave pattern (a), separated by fibrovascular amyloid stroma (b) (H&E, original magnification,  $\times 200$ ). Tumor cells show short or long spindle nuclei, abundant cytoplasm and rare mitoses (c) (H&E, original magnification,  $\times 400$ )

MTC is a neuroendocrine tumor, accounting for 5% ~ 10% of thyroid malignant tumors [6]. The clinical symptoms of spindle cell variant MTC are consistent with MTC. MTC patients generally have no specific clinical symptoms, only presenting with a painless thyroid mass, sometimes presenting with intractable diarrhea, facial flushing or other neuroendocrine symptoms. In addition, serum calcitonin (sCT) is the most sensitive and specific marker for preoperative diagnosis of MTC [7], and serum CEA is synchronous with sCT in some MTC patients [8, 9], which is of reference value for diagnosis and prognosis of the disease. When the tumor causes compression or invasion to the surrounding tissues, the corresponding clinical symptoms may appear, and lymph node metastasis is easy to occur in the early stage. All the patients in our series presented with cervical mass without increase of sCT and CEA.

Histological diagnosis of MTC depends on its cytological feature, growth pattern, and amyloid deposition,

as well as its immunophenotype. MTC with predominant spindle cell morphology is seen less commonly. The spindle cell variant MTC consists mainly of irregularly arranged bundles or interlaced spindle cells in which the stroma is separated by fibrous stroma or amyloid. Amyloid deposition is not a necessary condition for MTC diagnosis, since amyloid may not be present in atypical cases. The tumor cells showed short or long spindle nuclei, abundant cytoplasm, inconspicuous nucleoli and rare mitoses, as well as clear boundaries with surrounding tissues. Immunohistochemically, the most sensitive markers for the neoplasm are CT and calcitonin gene-related peptide, although they are not specific because they also can be found in endocrine tumors of nonthyroid origin, such as islet cell tumors and intestinal neuroendocrine carcinomas. In addition, MTC cells also are immunoreactive for cytokeratins, neuron-specific enolase, Syn, CEA, and CgA, whereas they are not stained by TG. In our cases, the tumors showed spindle cell



**Fig. 2** Immunohistochemistry. The tumor cells are positive for CT (a), CD56 (b), CgA (c) and Syn (d) in the cytoplasm (Original magnification,  $\times 200$ ). The tumor cells are positive for TTF-1(e) and Ki-67 (f) in the the nucleus (Original magnification,  $\times 200$ )

morphology, the positive expressions of TTF-1, CT, CgA, Syn and CD56 and amyloid deposition, confirming the diagnosis as spindle cell variant MTC, which were consistent with those reported in the literature [10].

Spindle cell variant MTC is necessary to differentiate it from other primary or secondary thyroid tumors that show spindle cell morphology [11]. Other spindle cell tumors occurring in the thyroid gland, such as spindle cell atypical thyroid adenoma, spindle epithelial tumor with thymus-like differentiation, poorly differentiated thyroid carcinoma, and anaplastic thyroid carcinoma, may show spindle cell morphology and positive expression of epithelial cell markers, TTF-1 and TG, but they are negative for neuroendocrine markers. Therefore, it is easy to distinguish these tumors by comprehensive staining of CT, TTF-1, CgA, Syn and CD56. Also, spindle cell variant MTC can mimic some spindle cell mesenchymal tumors occurring in the thyroid gland, such as leiomyoma, peripheral schwannoma, and spindle cell melanoma. These tumors have specific markers, but are negative for neuroendocrine markers. Therefore, the morphology in conjunction with immunohistochemistry is sufficient to render a diagnosis of these tumors.

Surgical treatment is still the best treatment for spindle cell variant MTC. When surgical treatment is difficult to control, the efficacy of radioactive iodine treatment, in vitro irradiation or chemotherapy is poor. Therefore, early detection and treatment is the most effective way to improve the therapeutic effect. In our series, all patients received local resection or regional lymph node dissection. During follow-up of 7 ~ 84 months in our series, all patients were alive and had no recurrence.

In conclusion, spindle cell variant MTC is an extremely rare histological subtype. It is easy to diagnose and differentiate from other spindle cell lesions of thyroid by histological morphology, immunohistochemical staining with CT, CgA, Syn, CD56, and TTF-1.

#### Abbreviations

MTC: Medullary thyroid carcinoma; WHO: World Health Organization; CT: calcitonin; CgA: chromogranin A; Syn: synaptophysin; TG: Thyroglobulin; CEA: carcinoembryonic antigen; EMA: epithelial membrane antigen

#### Acknowledgements

Not applicable.

#### Authors' contributions

Yan Xia Wang: data collection and drafting. Yang Shoujing: pathological diagnosis, guiding paper writing and revision. All authors approved the manuscript.

#### Funding

This present study was funded by the National Nature Science Foundation of China (grant nos. 81800046).

#### Availability of data and materials

The datasets used and/or analyzed during the current study are available from the corresponding author upon reasonable request.

## Declarations

#### Ethics approval and consent to participate

Not applicable.

#### Consent for publication

Written informed consent was obtained from the patient for the publication of short report.

#### Competing interests

The authors declare that they have no competing interests.

Received: 27 February 2021 Accepted: 22 September 2021

Published online: 27 November 2021

## References

- Ibarrola de Andres C, Castellano Megias VM, Ballester Carcavilla C, Alberti Masgrau N, PA PBADA. Hepatic metastases from the spindle cell variant of medullary thyroid carcinoma: report of a case with diagnosis by fine needle aspiration biopsy. *Acta cytologica*. 2001;45:1022–6.
- Laforga JBAranda FI. Pseudoangiosarcomatous features in medullary thyroid carcinoma spindle-cell variant. Report of a case studied by FNA and immunohistochemistry. *Diagn Cytopathol*. 2007;35(7):424–8. <https://doi.org/10.1002/dc.20656>.
- Satyrganov I. Spindle-cell variant of thyroid medullary carcinoma with favourable prognosis. *Arkh Patol*. 2000;62(3):42–4.
- Blonk DI, Talerman AVisser-van Dijk MN. The cytology of medullary carcinoma of the thyroid with spindle cell pattern. *Archiv fur Geschwulstforschung*. 1978;48(4):313–7.
- Das A, Nargotra N, Singh S, Deepak RKTyagi I. Rare presentation of medullary carcinoma of thyroid with predominant spindle cell pattern & abundant calcification. *Annals of Pathology and Laboratory Medicine*. 2016; 03:C130–4.
- Rusinek D, Chmielik E, Krajewska J, Jarzab M, Oczko-Wojciechowska M, Czarniecka A, et al. Current Advances in Thyroid Cancer Management. Are We Ready for the Epidemic Rise of Diagnoses? *International journal of molecular sciences*. 2017;18.
- Pazaitou-Panayiotou K, Chrisoulidou A, Mandanas S, Tziomalos K, Doumala EPatakioita F. Predictive factors that influence the course of medullary thyroid carcinoma. *Int J Clin Oncol*. 2014;19(3):445–51. <https://doi.org/10.1007/s10147-013-0588-8>.
- Wells SA Jr, Asa SL, Dralle H, Elisei R, Evans DB, Gagel RF, et al. Waguespack SG American thyroid association guidelines task force on medullary thyroid C. Revised American Thyroid Association guidelines for the management of medullary thyroid carcinoma Thyroid: official journal of the American Thyroid Association. 2015;25(6):567–610. <https://doi.org/10.1089/thy.2014.0335>.
- Raue F Frank-Raue K. Epidemiology and clinical presentation of medullary thyroid carcinoma. Recent results in cancer research. *Fortschritte der Krebsforschung. Progres dans les recherches sur le cancer*. 2015;204:61–90.
- Delellis RA, LiVolsi V, Al Ghuzlan A. X. M-G, Albores Saavedra J, mete O, Baloch ZW, Moley JF, Basolo F, Nikiforov YE, Elisei R, nose V, Kaserer KE. PA. Medullary thyroid carcinoma. In: Lloyd RV, Osamura RY, Kloppel G, Rosai J, editors. WHO classification of Tumours of endocrine organs. 4th ed. Lyon, France: IARC Press; 2017. p. 108–13.
- Papi G, Corrado SLiVolsi VA. Primary spindle cell lesions of the thyroid gland: an overview. *Am J Clin Pathol*. 2006;125(Suppl):S95–123. <https://doi.org/10.1309/4DQW6RQX3C6KRX1J>.

## Publisher's Note

Springer Nature remains neutral with regard to jurisdictional claims in published maps and institutional affiliations.