

Ipsilateral femoral head osteochondral transfers for osteochondral defects of the femoral head

Joshua D. Johnson, Nicholas M. Desy and Rafael J. Sierra*

Department of Orthopedic Surgery, Mayo Clinic, 200 First Street SW, Rochester, MN 55905, USA

*Correspondence to: R. J. Sierra. E-mail: sierra.rafael@mayo.edu

Submitted 30 December 2016; Revised 25 April 2017; revised version accepted 26 April 2017

ABSTRACT

Osteochondral defects of the femoral head are rare. Several treatment options have been described, though there is currently no consensus on the appropriate management of these lesions. Five patients underwent femoral head osteochondral autograft transfer for treatment of ipsilateral femoral head osteochondral defects via surgical hip dislocation between 2011 and 2014 at our institution. The mean age of the patients was 24.8 (16–37) years. There were four females and one male. Mean follow-up was 53.8 (30–64) months. Four patients reported complete resolution of preoperative pain, return to baseline activities and were satisfied with their results. Harris hip scores improved from a mean 60.8 (30–87) to 86.6 (44–100). There was no radiographic evidence of progression of the femoral head defects. There were no operative complications. Osteochondral autograft transfer from the ipsilateral femoral head using a surgical hip dislocation demonstrated good clinical and radiographic outcomes at midterm follow-up in our cohort and may be considered a suitable option for management of these lesions in select patients. Further research and follow-up is warranted to more clearly define the indications and outcomes of this procedure.

INTRODUCTION

Osteochondral defects of the femoral head are rare, but are a source of pain for the young active patient. They may be acute or chronic and of variable thickness. These lesions may arise secondary to several etiologies including osteonecrosis, trauma, femoroacetabular impingement, slipped-capital-femoral epiphysis and Leg-Calvé-Perthes Disease [1]. Prompt diagnosis and treatment are imperative as these lesions have limited capacity to heal with the production of biomechanically inferior fibrocartilage, are often symptomatic and cause significant functional impairment, and risk rapid progression to osteoarthritis [2]. The goal of treatment is to restore articular surface congruity in an effort to restore normal joint kinematics, thereby alleviating symptoms and preventing progression to degenerative joint disease. Several treatment options have been described, though there is currently no consensus on the appropriate management of these lesions, especially in young, active patients. Surgical options include microfracture, autologous chondrocyte implantation, osteochondral

autograft transfer (OATS), osteochondral allograft transfer, femoral osteotomy and hip arthroplasty [3–8].

There are few reports on the use of OATS for femoral head osteochondral defects. Some studies have documented success using osteochondral autografts from the distal femoral condyle [1, 9–13]. While this procedure can provide patient benefit, it requires an added incision and exposure of the knee which can cause additional morbidity. Hangody *et al.* reported on 831 mosaicplasties in which autologous osteochondral plugs were harvested from the distal femoral condyle for transfer to defects in the weightbearing zones of various diarthrodial surfaces. They noted a three percent incidence of slight donor site disturbances, most notably patellofemoral pain [9]. Therefore, some authors have attempted to harvest osteochondral autografts from the inferior non-weightbearing portion of the ipsilateral femoral head to eliminate the need for surgical dissection and exposure of the knee region [2, 5, 14, 20].

At our institution, we have used OATS from the ipsilateral femoral head in the management of femoral head

osteochondral defects in select patients for the past 5 years. Given the paucity of evidence for this procedure in the literature, we sought to review the early clinical and radiographic outcomes, as well as complications and need for further surgery in five patients who underwent OATS from the ipsilateral femoral head for osteochondral defects.

MATERIALS AND METHODS

Patients

Five patients who underwent femoral head OATS for ipsilateral femoral head osteochondral defects between 2011 and 2014 were included in this study. All patients had symptomatic femoral head osteochondral defects identifiable on advanced imaging [computed tomography (CT) or magnetic resonance imaging (MRI)] (Fig. 1). The defect in one patient resulted from an area of avascular

necrosis secondary to long-term corticosteroid therapy; the lesions in the other four patients were post-traumatic osteonecrosis. Two of the patients reported history of a traumatic subluxation episode while the other two both had history of a motor vehicle collision with pelvic trauma, though no femoral head defects were documented at the time of injury. All patients had at least 2 years of follow-up. Data collected included age, sex, symptoms at presentation, etiology and size of osteochondral defect, size and number of plugs harvested, length of follow-up, clinical and radiographic outcomes, complications and need for further surgery.

Operative technique

All procedures were performed by the senior author. The same approach was used for all cases. All patients underwent general anesthesia as well as psoas nerve blockade.

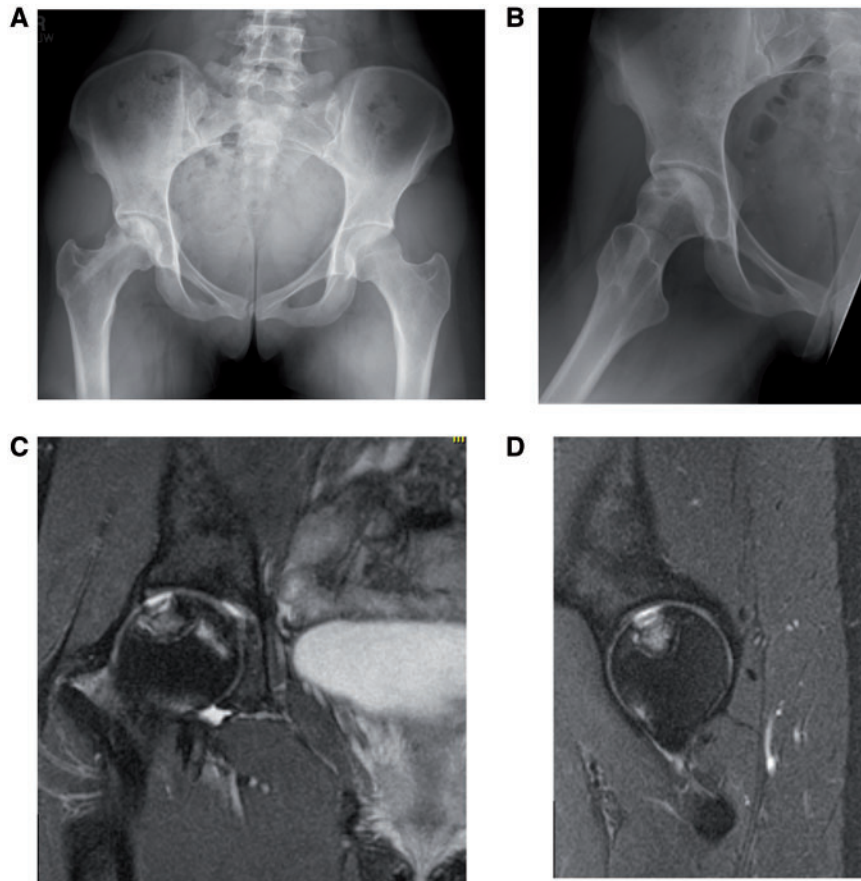


Fig. 1. Preoperative imaging. Anteroposterior X-ray view of the pelvis (A) and frog leg lateral view of the right hip (B) of a 25-year-old woman who presented with right hip pain. Her past medical history included nephrotic syndrome which required intermittent treatment with high dose corticosteroids. One year prior to her presentation, she was treated with a core decompression at an outside institution for osteonecrosis of the femoral head which is evident on her X-rays. However, she continued to have pain. Coronal (C) and sagittal (D) magnetic resonance images further characterized the osteochondral lesion with collapse that involved a large area of the weightbearing portion of the femoral head.

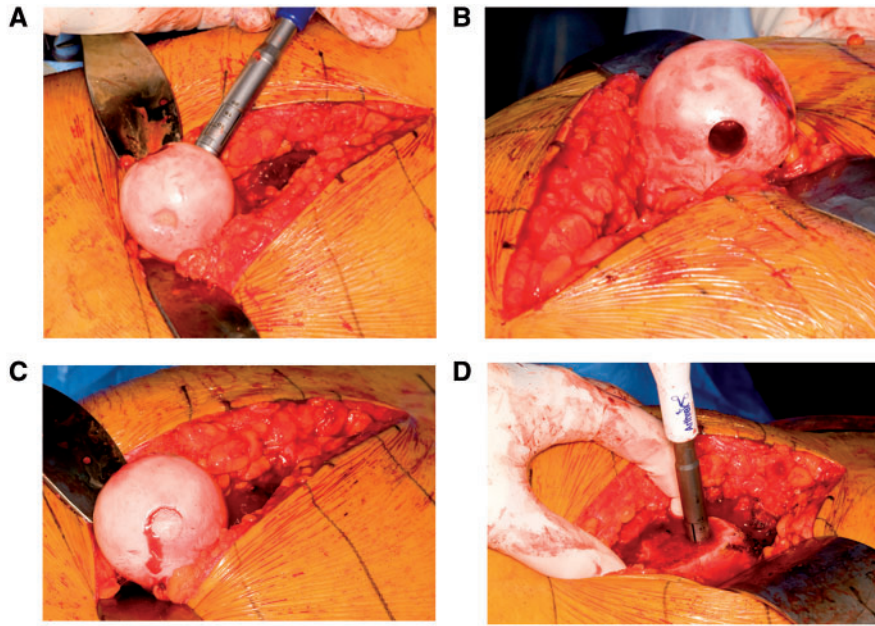


Fig. 2. Intraoperative pictures. (A) The osteochondral lesion is visualized with collapse. Note the donor site trochar is placed at the inferomedial aspect of the femoral head to harvest an osteochondral autograft plug. (B) The donor site is seen with the osteochondral autograft removed. (C) After the osteochondral defect area was prepared with a trochar, the osteochondral autograft was transferred to the recipient site and stabilized with a press-fit technique. (D) A trochar is used to remove autograft cancellous bone to place at the donor site along the inferomedial portion of the femoral head.

All patients received routine surgical antibiotic prophylaxis. A lateral decubitus position was used. A straight skin incision was made laterally, and the fascia split. The posterior aspect of the greater trochanter was then accessed and a trochanteric flip osteotomy performed taking care to make the osteotomy thick enough for repair yet protecting the vessels that supply the femoral head. A distal sub-vastus approach to the femur was then carried out. The greater trochanteric piece was flipped anteriorly and care taken not to break the anterior aspect of the fragment for later repositioning. The interval between the piriformis and gluteus minimus was dissected and a complete capsule exposure performed with good access anteriorly, superiorly and posteriorly. A capsulotomy was then carried out in a Z-shaped fashion with care taken not to injure the labrum proximally. Anterior and superior limbs were then made and the capsulotomy carried out distally to the level of the neck. The hip was then dislocated with external rotation, the round ligament cut close to the acetabular margin and the foot placed in a pocket. Attention was then turned to the acetabular cartilage with sharp debridement of any chondral defects, microfracture of the defects as indicated and labral repair. Focus was then directed to the femoral head with identification of the osteochondral defect (Fig. 2A). Donor osteochondral plugs were extracted from the non-

weightbearing portions of the anteroinferior medial and lateral portions of the femoral head using the OATS instrumentation (Athrex Inc., Naples, FL) with the number and size of plugs determined by the magnitude of the defect (Fig. 2B). Similar size plugs were then extracted from the recipient site followed by burring of any necrotic areas in those with osteonecrosis down to bleeding bone. Donor plugs were then press-fit into the recipient site(s) (Fig. 2C). Bone graft was then harvested from the trochanteric bed and impacted into the donor site(s) (Fig. 2D) or used to set the depth of the recipient site to hold the plugs in optimal position when needed. The contour of the OATS graft and head were then verified with offset plastic templates. The hip was then reduced and carried through range of motion. Irrigation of the joint was carried out. The capsule was closed loosely and the trochanteric flip osteotomy was reduced and fixed with screws. The trochanteric bursa was closed over the screws. The fascia, the subcutaneous tissue and the skin were all closed separately.

Patients were made Toe-Touch-Weight-Bearing on the operative extremity for a period of 6 weeks following surgery and were given continuous passive motion machines to use for 4–6 weeks. They were instructed to use the machines at least 4–6 h per day with range of motion beginning at 0–30° and progressing to 0–70° as tolerated.

Patients were seen in follow-up at 2 weeks for a wound check, and again at 8 weeks, 4 months, 1 year, 2 years and at 5 years with X-rays (anteroposterior view of the pelvis as well as anteroposterior, frog-leg lateral and cross table lateral views of the involved hip).

RESULTS

All patients were young with a mean age of 24.8 (16–37) years (Table I). There were four females and one male. All were right hips. Defect sizes ranged from 10 to 40 mm in diameter. In one case, only one osteochondral plug was harvested while the other four cases necessitated three plugs each. Mean follow-up was 53.8 (30–64) months. Four patients reported complete resolution of preoperative pain, return to baseline activities and satisfaction with their results. Two of these patients underwent hardware removal. The one patient with avascular necrosis secondary to long-term corticosteroid therapy noted continued discomfort with flexion and rotation and at 5 months post-operatively underwent a hip decompression procedure with injection of bone marrow concentrate into the femoral head. She continued to experience pain and reported no improvement at last follow-up but has not required further surgery as there has been no progression of the femoral head defect. Harris hip scores improved from a mean 60.8 (30–87) to 86.6 (44–100). The Harris hip scores were good to excellent (>95) in the four patients with post-traumatic osteonecrosis while poor in the patient with steroid-induced avascular necrosis. Radiographic outcomes at last follow-up in all cases demonstrated stable healed lesions with some mild degenerative changes, most notably sclerosis in the affected area but no evidence of progression to collapse (Fig. 3). There were no surgical complications in any patient (femoral head osteonecrosis, trochanteric non-unions, heterotopic ossification, etc.) (Table I).

DISCUSSION

Though rare, osteochondral defects of the femoral head can be debilitating for patients. Several treatment options have been described, though there is currently no consensus on the appropriate management of these lesions in young, active patients. At our institution, we have used OATS from the ipsilateral femoral head in select patients for the past 5 years. The results of the procedure have been excellent when the defect is a result of osteonecrosis secondary to trauma. The one patient with steroid-induced avascular necrosis had a poor clinical result, but no radiographic progression of the defect.

We do acknowledge limitations to the present study. First, this constitutes Level IV evidence from a retrospective case series. Second, we did not obtain post-operative

MRIs which may have demonstrated subtle evidence of disease progression or joint degeneration not seen on radiographs, but because these patients were not symptomatic, we did not feel that three dimensional imaging was necessary. In addition, the frog leg lateral radiograph is a good view to determine the presence of subchondral collapse and none of the hips demonstrated radiographic progression of defects. Finally, although our follow-up is short, we are very encouraged by the results obtained in these young patients with symptomatic defects. We are hopeful that improving the contour of the femoral head in these cases will produce successful long term results.

The principle of OATS is to fill an osteochondral defect with any number of small or large osteochondral plugs taken from a non-weightbearing portion of bone in order to provide a congruent articular surface covered with hyaline cartilage. The transported hyaline cartilage has been shown to have good survivability whereby histological analysis has demonstrated formation of a composite cartilage layer consisting of transplanted hyaline cartilage and fibrocartilage ingrown from the bony base of the defect which is believed to provide a more durable surface than reparative fibrocartilage alone [15]. In addition, donor sites have been shown to heal with cancellous bone and a fibrocartilage cap which seems to be sufficient for these non-weightbearing areas [15]. Autologous osteochondral transfer has been described for the successful management of osteochondral lesions in several diarthrodial joints including the knee, ankle, elbow and shoulder, though few studies have described its use in the femoral head [16–19]. Some studies have documented success with the use of distal femoral condyles as the donor site for femoral head osteochondral defects [1, 9–13]. Few papers in the form of case reports and one case series have described the use of the ipsilateral femoral head for osteochondral plug donation (Table II) [2, 5, 14, 20]. The combined results of this operation have been encouraging. We believe patients with osteochondral defects of the femoral head less than 40 mm in diameter located within the weightbearing zone may be amenable to this technique.

All patients in our cohort were young adults with debilitating symptoms secondary osteochondral defects identifiable on advanced imaging. Defect size ranged from 10 to 40 mm in diameter and in some cases resulted in incongruity with 1 or 2 mm of collapse. Comparably, Nam *et al.* [5] presented a young adult male who sustained a traumatic dislocation of the femur along with a femoral head fracture and osteochondral defect, Bastian *et al.* [14] presented the case of a 48-year-old male who sustained traumatic anterior dislocation of the hip compounded by a 10 × 20 mm osteochondral defect with 5 mm impaction depth in the

Table I. Patients who underwent ipsilateral femoral head osteochondral autograft transfer

Age	Sex	Laterality	Symptoms	Signs	Etiology	Defect Size	Number of plugs	Length of follow-up	Clinical outcomes at latest follow-up	Radiographic outcome at latest follow-up	Need for further surgery	Complications	
Patient 1	25	F	R	Right hip/groin pain, worse with activity	Pain with flexion/internal rotation, positive anterior impingement sign	Post-traumatic	10 mm	1	64 months	Asymptomatic, return to recreational activity, pleased with results HHS Pre-op: 71 Post-op: 98	Mild sclerosis of the lesion	Hardware removal 8 weeks post-op	None
Patient 2	21	F	R	Right hip/groin pain, worse with activity	Pain with flexion/internal rotation, positive Stinchfield sign	Post-traumatic	30 mm	3	62 months	No pain, return to running, pleased with results HHS Pre-op: 87 Post-op: 100	Mild degenerative change	None	None
Patient 3	37	F	R	Right hip/groin pain, worse with activity	Pain with flexion/internal rotation, antalgic gait	Osteonecrosis secondary to long-term corticosteroid therapy	17 mm × 10 mm × 10 mm	3	61 months	Continued symptoms, pain with flexion/internal rotation HHS Pre-op: 30 Post-op: 44	Stable AVN without evidence of collapse	Hip decompression 5 months post-op	None
Patient 4	25	F	R	Right hip pain, worse with activity	Pain with flexion/internal rotation, positive Stinchfield test, antalgic gait	Post-traumatic	40 mm	3	52 months	No pain, return to running, pleased with results HHS Pre-op: 52 Post-op: 95	Moderate degenerative changes, stable AVN without collapse	Hardware removal 7 months post-op	None
Patient 5	16	F	R	Right hip pain, worse with activity	Pain with flexion/internal rotation	Post-traumatic	30 mm × 12 mm	3	30 months	No pain, return to activity, pleased with results HHS Pre-op: 64 Post-op: 96	Stable radiographic lesion	None	None

AVN, Avascular necrosis; HHS, Harris hip score.

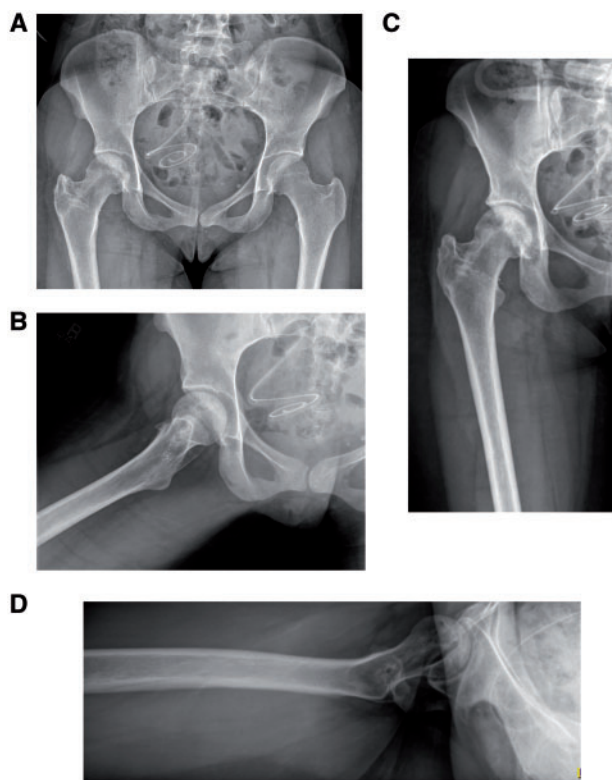


Fig. 3. Postoperative imaging. Anteroposterior view of the pelvis (A), anteroposterior X-ray of the right hip (B) as well as frog-leg (C) and cross-table (D) lateral X-rays of the right hip at 5 years of follow-up. She continues to be pain-free with her right hip and is satisfied with the procedure. Note preservation of her femoral head as a sphere and maintenance of her joint space without degenerative changes.

anterosuperior weight-bearing portion of the femoral head, and Sotereanos *et al.* [20] presented a case of a 36-year-old man diagnosed with bilateral femoral head osteonecrosis. Based on our current series, the best patient for this procedure is the young patient, with a relatively small defect (3–4 cm maximum diameter), with osteonecrosis secondary to trauma. The self-limiting nature of the trauma presents the best scenario for healing. Patients with osteonecrosis from other etiologies such as steroids have ongoing pathophysiologic stress to the femoral head and this may increase the risk of treatment failure.

Girard *et al.* [2] reported the largest existing series (10 patients) on such management of femoral head osteochondral defects. Their series consisted of seven males and three females with a mean age of 21 years old who presented with pain related to femoral head cartilage damage. The etiology of defects included sequelae of Legg-Calvé-Perthes disease, spondylo-epiphyseal dysplasia and epiphyseal dysplasia. They excluded patients with age greater

than 25 years, acetabular cartilage defects, and those with evidence of avascular necrosis. The mean area of osteochondral damage was 4.8 cm² (3–9 cm²). They noted improvement in pain and range of motion, as well as mean functional hip scores including Postel Merle d'Aubigne, Harris Hip, UCLA and Oxford Hip with mean follow-up of 29.2 months.

The patient with steroid-induced avascular necrosis in our cohort remained symptomatic post-operatively. She had an osteochondral lesion (17 × 10 × 10 mm) with evidence of subchondral collapse. The case was initially approached with plans for a trapdoor procedure with elevation of the osteochondral defect; however, this was aborted when the cartilage was found to be of poor quality. The decision was therefore made to do osteochondral transfer with elevation of the femoral head from within the graft area. At 2 months of follow-up, she noted continued hip pain. X-rays revealed radiolucency surrounding the level of known femoral head necrosis, but restoration of the articular surface without evidence of collapse. At 4 months of follow-up, her hip pain persisted though X-rays continued to demonstrate a congruent joint surface. She subsequently underwent a hip decompression and trochanteric hardware removal 5 months following her initial operation. At 1 year after OATS, she continued to have hip pain. Of note, follow-up imaging consistently demonstrated maintenance of joint surface congruity. No subsequent surgery has been required. Factors contributing to her outcome may include the magnitude of osteonecrosis and subchondral collapse, ipsilateral foot and ankle arthritis, social security disability status, obesity (BMI 35) and smoking. Atlas *et al.* [21] concluded that patients with disability compensation had worse symptoms, functional status and satisfaction outcomes compared to patients without disability compensation in the treatment of lumbar disk herniation.

Radiographic outcomes at latest follow-up in all patients in our cohort demonstrated stable lesions with some mild degenerative changes, most notably sclerosis of the involved head but no evidence of progression or collapse. This too is consistent with what has been reported by others. Girard *et al.* [2] noted intact cartilage overlying donor plugs in all cases demonstrated via CT arthrography at 6 months and all plugs to be well-incorporated on radiographic exam at latest follow-up.

Similar to our cases, the above authors all utilized the surgical hip dislocation technique described by Ganz *et al.* [22], in which anterior dislocation of the hip is achieved via trochanteric osteotomy, thereby avoiding division of the external rotators and preserving the blood supply to the femoral head. This approach provides excellent

Table II. Summary of the current cases reported in the literature that were treated with an ipsilateral femoral head osteochondral autograft transfer

Authors	Patients (No.)	Defect size	No. of plugs	Follow-up (range)	Clinical outcomes at latest follow-up	Radiographic outcomes at latest follow-up	Need for further surgery
Bastian <i>et al.</i> [10].	1	10 × 20 mm	1	2 years	HHS: 100/100 WOMAC-Pain: 0/20, Stiffness 0/8, Physical Activity 1/68	2 year MRI—no AVN	No
Girard <i>et al.</i> [2]	10	Mean 4.8 cm ² (3–9 cm)	Not reported	Mean 29.2 months (20–39 months)	Postel Merle d'Aubigne score Pre-op: 10.5 (8–13) Post-op: 15.5 (12–17) HHS Pre-op: 52.8 (35–74) Post-op: 79.5 (65–93) Oxford hip score Pre-op: 34.5 (22–48) Post-op: 19.2 (14–26) Devane activity score Pre-op: 2.1 (2–3) Post-op: 3.25 (3–4) UCLA score Pre-op: 3.7 (3–5)	6 month Radiographs and CT arthrography— osteointegration and res- toration of femoral head curvature	No
Nam <i>et al.</i> [5].	1	10 mm	1	5 years	Post-op: 5.8 (5–7). No pain with return to base- line physical activity	1 year MRI-autograft incorp- oration; No AVN	No
Sotereanos <i>et al.</i> [20].	1	15 mm	3	66 months	No pain, VAS = 0	Not reported	No

HHS, Harris hip score; WOMAC, Western Ontario and McMaster Universities Arthritis Index; MRI, magnetic resonance imaging; AVN, avascular necrosis.

exposure of both the acetabulum and femoral head allowing for not only accurate assessment of articular surface congruity but also concomitant treatment of labral pathology and/or impingement without risk of iatrogenic avascular necrosis thus making it quite suitable for addressing osteochondral defects involving the hip joint. Like the other reports outlined here, we noted no complications in any of our cases. Two of our patients did go on to have hardware removal secondary to discomfort with subsequent resolution of symptoms.

Comparable to our cases, the above authors all implemented post-operative weight bearing restrictions and hip dislocation precautions. In addition, our cases and those outlined by Girard *et al.* [2] utilized continuous passive motion (CPM) machines as part of the post-operative care regimen. While there have been some studies suggesting there may be no benefit to use of dislocation precautions and assistive devices following total hip arthroplasty [23–27], we are not aware of any studies analyzing their use in cases of surgical hip dislocation and OATS to the femoral head. Akin to the theory outlined by O’Driscoll *et al.* [28], it is our belief that use of CPM provides benefit in the early post-operative period by mechanically reducing hemarthrosis and extra-articular edema, thereby decreasing post-operative pain and potentially reducing risk for formation of undesirable granulation and subsequent fibrous tissue which may limit motion.

CONCLUSION

Osteochondral defects of the femoral head are a potentially devastating condition in young adult patients. While several management options have been described, there is no consensus on the most appropriate treatment method in this patient population. Osteochondral autograft transfer from the ipsilateral femoral head using a surgical hip dislocation demonstrated good clinical and radiographic outcomes at midterm follow-up in our cohort of patients with osteochondral defects of post-traumatic etiology. Long-term follow-up studies and post-operative MRI could help further determine the success of this procedure.

FUNDING

None.

CONFLICT OF INTEREST STATEMENT

None declared.

REFERENCES

1. Emre TY, Cift H, Seyhan B *et al.* Mosaicplasty for the treatment of the osteochondral lesion in the femoral head. *Bull NYU Hosp Jt Dis* 2012; **70**: 288–90.
2. Girard J, Roumazielle T, Sakr M *et al.* Osteochondral mosaicplasty of the femoral head. *Hip Int* 2011; **21**: 542–8.
3. McDonald JE, Herzog MM, Philippon MJ. Return to play after hip arthroscopy with microfracture in elite athletes. *Arthroscopy* 2013; **29**: 330–5.
4. Akimau P, Bhosale A, Harrison P *et al.* Autologous chondrocyte implantation with bone grafting for osteochondral defect due to posttraumatic osteonecrosis of the hip—a case report. *Acta Orthop* 2006; **77**: 333–6.
5. Nam D, Shindle MK, Buly RL *et al.* Traumatic osteochondral injury of the femoral head treated by mosaicplasty: a report of two cases. *HSS J* 2010; **6**: 228–34.
6. Khanna V, Tushinski DM, Drexler M *et al.* Cartilage restoration of the hip using fresh osteochondral allograft: resurfacing the pot-holes. *Bone Joint J* 2014; **96-B** (11 Suppl A): 11–8.
7. Yamamoto T, Iwasaki K, Iwamoto Y. Transtrochanteric rotational osteotomy for a subchondral insufficiency fracture of the femoral head in young adults. *Clin Orthop Relat Res* 2010; **468**: 3181–5.
8. Pierce TP, Elmallah RK, Jauregui JJ *et al.* Outcomes of total hip arthroplasty in patients with osteonecrosis of the femoral head: a current review. *Curr Rev Musculoskelet Med* 2015; **8**: 246–51.
9. Hangody L, Fules P. Autologous osteochondral mosaicplasty for the treatment of full-thickness defects of weight-bearing joints: ten years of experimental and clinical experience. *J Bone Joint Surg Am* 2003; **85** (Suppl 2): 25–32.
10. Krych AJ, Lorich DG, Kelly BT. Osteochondral autograft transfer for a posttraumatic osteochondral defect of the femoral head. *Am J Orthop* 2012; **41**: 472–6.
11. Cetinkaya S, Toker B, Taser O. Arthroscopic retrograde osteochondral autologous transplantation to chondral lesion in femoral head. *Orthopedics* 2014; **37**: e600–4.
12. Hart R, Janeczek M, Visna P *et al.* Mosaicplasty for the treatment of femoral head defect after incorrect resorbable screw insertion. *Arthroscopy* 2003; **19**: E1–5.
13. Kılıçoğlu Öİ, Polat G, Erşen A, Birişik F. Long-term result of mosaicplasty for femoral head osteochondral lesion: a case report with 8 years follow-up. *Hip Int* 2015; **25**: 589–92.
14. Bastian JD, Büchler L, Meyer DC *et al.* Surgical hip dislocation for osteochondral transplantation as a salvage procedure for a femoral head impaction fracture. *J Orthop Trauma* 2010; **24**: e113–8.
15. Hangody L, Vászárhelyi G, Hangody LR *et al.* Autologous osteochondral grafting—technique and long-term results. *Injury* 2008; **39** Suppl: S32–9.
16. Gudas R, Stankevicius E, Monastyreckiene E *et al.* Osteochondral autologous transplantation versus microfracture for the treatment of articular cartilage defects in the knee joint in athletes. *Knee Surg Sports Traumatol Arthrosc* 2006; **14**: 834–42.
17. Al-Shaikh RA, Chou LB, Mann JA *et al.* Autologous osteochondral grafting for talar cartilage defects. *Foot Ankle Int* 2002; **23**: 381–9.
18. Ansah P, Vogt S, Ueblacker P *et al.* Osteochondral transplantation to treat osteochondral lesions in the elbow. *J Bone Joint Surg Am* 2007; **89**: 2188–94.

19. Scheibel M, Bartl C, Magosch P *et al.* Osteochondral autologous transplantation for the treatment of full-thickness articular cartilage defects of the shoulder. *J Bone Joint Surg Br* 2004; **86**: 991.
20. Sotereanos NG, DeMeo PJ, Hughes TB *et al.* Autogenous osteochondral transfer in the femoral head after osteonecrosis. *Orthopedics* 2008; **31**: 177.
21. Zelken JA. First-person long-term follow-up using autologous mosaicplasty for osteochondral lesion accompanying femoral head fracture. *J Orthop Trauma* 2016; **30**: e70–4.
22. Atlas SJ, Chang Y, Keller RB *et al.* The impact of disability compensation on long-term treatment outcomes of patients with sciatica due to a lumbar disc herniation. *Spine* 2006; **31**: 3061–9.
23. Ganz R, Gill TJ, Gautier E *et al.* Surgical dislocation of the adult hip a technique with full access to the femoral head and acetabulum without the risk of avascular necrosis. *J Bone Joint Surg Br* 2001; **83**: 1119–24.
24. Peak EL, Parvizi J, Ciminiello M *et al.* The role of patient restrictions in reducing the prevalence of early dislocation following total hip arthroplasty. A randomized, prospective study. *J Bone Joint Surg Am* 2005; **87**: 247–53.
25. Ververeli PA, Lebby EB, Tyler C, Fouad C. Evaluation of reducing postoperative hip precautions in total hip replacement: a randomized prospective study. *Orthopedics* 2009; **32**: 889.
26. Mikkelsen LR, Petersen MK, Søballe K *et al.* Does reduced movement restrictions and use of assistive devices affect rehabilitation outcome after total hip replacement? A non-randomized, controlled study. *Eur J Phys Rehabil Med* 2014; **50**: 383–93.
27. Gromov K, Troelsen A, Otte KS *et al.* Removal of restrictions following primary THA with posterolateral approach does not increase the risk of early dislocation. *Acta Orthop* 2015; **86**: 463–8.
28. O'Driscoll SW, Giori NJ. Continuous passive motion (CPM): theory and principles of clinical application. *J Rehabil Res Dev* 2000; **37**: 179–88.