

## First report of closure of an iatrogenic recto-vesical fistula solely using endoscopic negative pressure therapy

OPEN  
ACCESS

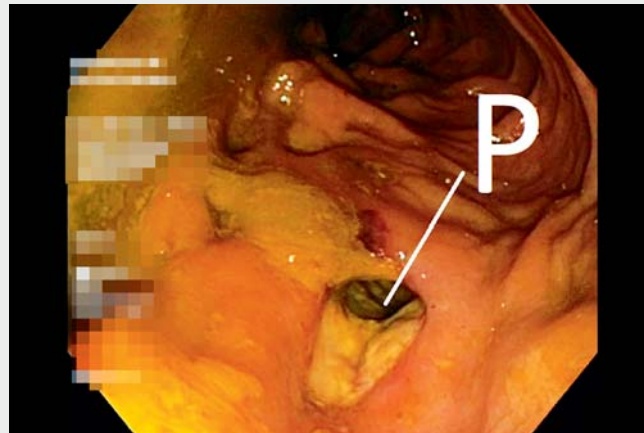A 70-year-old man presented with a recto-vesical fistula (rectal urinary leakage, pneumaturia, fecaluria). Four days earlier, he had injured himself during anal manipulation with a stick. Endoscopically and cystographically, a transmural perforation, 1.5 cm in diameter, and a fistula canal, 5 cm long, was found (► **Video 1**).

We started endoscopic negative pressure therapy (ENPT) on Day 5 after injury. The colon was lavaged and urine collection performed with a conventional transurethral urinary catheter.

For the first cycle of intracavitary ENPT, we used an open-pore polyurethane foam drain (OPD; EndoSponge; B. Braun, Melsungen, Germany). The customized foam was inserted into the fistula canal through the rectal perforation opening. Negative pressure (−125 mmHg, continuous; ActiV.A.C.; KCI, San Antonio, Texas, USA) was applied. At the first drain change after 3 days, the wound surface was debrided with suction and showed an irregular granulation pattern (► **Fig. 1**). The sponge had already become very firmly adherent.

For this reason, we continued ENPT with an open-pore film drain (OFD). In OFD, a thin perforated double membrane with a liquid-conducting interspace (Suprasorb CNP Drainage Film; Lohmann & Rauscher International GmbH, Neuwied, Germany) is used as the drainage element [1–3] (► **Fig. 2**). It has good drainage properties but does not adhere as strongly to the wound.

For the first OFD, we wrapped multiple layers of the thin drainage film around the distal end of the tube (► **Fig. 3**). The diameter of the drainage element can be adjusted easily to the diameter of the fistula canal by increasing or reducing the number of windings. Very thin as well as large-diameter drains can be prepared in any length [1–3] (► **Fig. 4**). The final OFD that was used had a diameter of only 4 mm.



► **Video 1** Closure of an iatrogenic recto-vesical fistula using endoscopic negative pressure therapy and open-pore film drain. P, perforation.

ENPT with OFD was performed for a further 10 days. After removal of the OFD (► **Fig. 5**), the shrinking fistula canal showed typical regular aspiration patterns of the film (► **Fig. 5**).

After completion of ENPT, the patient continued to irrigate the rectum with an enema twice daily for 1 week [4]. The defect healed completely leaving a tiny scar, with fully preserved organ function of the rectum and bladder [5].

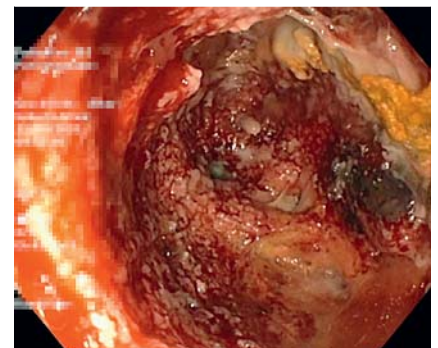
Endoscopy\_UCTN\_Code\_TTT\_1AQ\_2AG

### Acknowledgment


We would like to thank the nursing staff of the interdisciplinary endoscopic unit of Marienkrankenhaus Hamburg for their excellent technical assistance.

### Competing interests

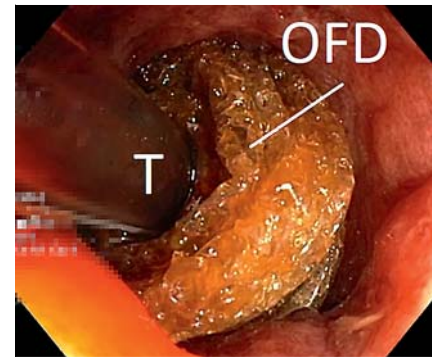
Gunnar Loske is a consultant for Lohmann & Rauscher GmbH & Co.KG. The remaining authors declare that they have no conflict of interest.



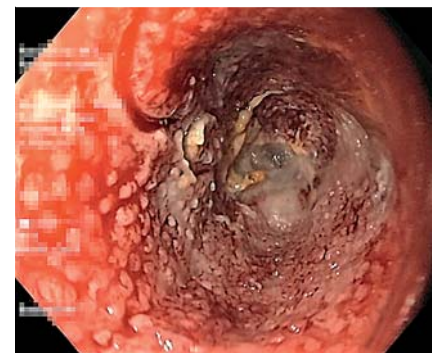► **Fig. 1** Endoscopic image after 3 days of endoscopic negative pressure therapy (ENPT) with an open-pore polyurethane foam drain in the fistula canal. The debrided wound surface showed an irregular granulation pattern, with very firm adhesion of the sponge. We therefore changed to ENPT with an open-pore film drain.



► **Fig. 2** For construction of an open-pore film drain (OFD), only one or a number of layers of the thin open-pore drainage film (oF; Suprasorb CNP Drainage Film, Lohmann & Rauscher International GmbH, Neuwied, Germany) are wrapped around the distal end of a drainage tube (T). In this way, the desired diameter of the drainage element can be easily adapted to the lumen of the fistula canal. Very thin as well as large-diameter OFDs can be prepared in any length by winding or unwinding the film layer(s). The arrows indicate the winding direction of the film. The open-pore polyurethane foam drain (OPD) shown is an unmodified EndoSponge (B. Braun, Melsungen, Germany).



► **Fig. 3** An open-pore film drain (OFD) was inserted into the opening of the fistula canal. Multiple windings of the film around the tube (T) can be seen clearly.



► **Fig. 5** After endoscopic negative pressure therapy with an open-pore film drain (OFD), the typical regular suction pattern of the open-pore drainage film can be seen in the shrinking wound canal.

### The authors


Gunnar Loske<sup>1</sup>, Wolfgang Schulze<sup>1</sup>, Ralf-Uwe Kiesow<sup>2</sup>, Marcus Kurzidem<sup>2</sup>, Salvador Fernandez de la Maza<sup>2</sup>, Christian Theodor Müller<sup>1</sup>

- 1 Department for General, Abdominal, Thoracic and Vascular Surgery, Katholisches Marienkrankenhaus Hamburg gGmbH, Hamburg, Germany
- 2 Department for Urology, Katholisches Marienkrankenhaus Hamburg gGmbH, Hamburg, Germany

### Corresponding author

**Gunnar Loske, MD**

Department for General, Abdominal, Thoracic and Vascular Surgery, Katholisches Marienkrankenhaus Hamburg gGmbH, Alfredstrasse 9, 22087 Hamburg, Germany  
loske.chir@marienkrankenhaus.org



► **Fig. 4** Removed multilayer open-pore film drain (OFD) after several days of therapy. E, endoscope.

## References

- [1] Loske G, Schorsch T, Rucktaeschel F et al. Open-pore film drainage (OFD) – a new multipurpose tool for endoscopic negative pressure therapy (ENPT). *Endosc Int Open* 2018; 6: E865–E871
- [2] Loske G, Müller CT. Tips and tricks for endoscopic negative pressure therapy. *Chirurg* 2019; 90 (Suppl. 01): 7–14
- [3] Müller J, Goerdts AM, Müller CT et al. Endoscopic negative pressure therapy for a broad rectal fistula using pull-through open-pore film and polyurethane foam drains. *Endoscopy* 2021. doi:10.1055/a-1519-6825
- [4] Kantowski M, Kunze A, Bellon E et al. Improved colorectal anastomotic leakage healing by transanal rinsing treatment after endoscopic vacuum therapy using a novel patient-applied rinsing catheter. *Int J Colorectal Dis* 2020; 35: 109–117
- [5] Loske G, Schorsch T, Kiesow RU et al. First report of urinary endoscopic vacuum therapy: for large bladder defect after abdomino-perineal excision of the rectum. Video paper. *Chirurg* 2017; 88 (Suppl. 01): 42–47

## Bibliography

*Endoscopy* 2022; 54: E879–E881

DOI 10.1055/a-1860-1650

ISSN 0013-726X

published online 24.6.2022

© 2022. The Author(s).

This is an open access article published by Thieme under the terms of the Creative Commons Attribution-NonDerivative-NonCommercial License, permitting copying and reproduction so long as the original work is given appropriate credit. Contents may not be used for commercial purposes, or adapted, remixed, transformed or built upon. (<https://creativecommons.org/licenses/by-nc-nd/4.0/>)

Georg Thieme Verlag KG, Rüdigerstraße 14, 70469 Stuttgart, Germany



## ENDOSCOPY E-VIDEOS

<https://eref.thieme.de/e-videos>



*Endoscopy E-Videos* is an open access online section, reporting on interesting cases and new techniques in gastroenterological endoscopy. All papers include a high quality video and all contributions are freely accessible online. Processing charges apply (currently EUR 375), discounts and waivers acc. to HINARI are available.

This section has its own submission website at

<https://mc.manuscriptcentral.com/e-videos>