

## Case Series

# Pulmonary resection for metachronous metastatic gastric cancer diagnosed using multi-detector computed tomography: Report of five cases

Noriyuki Nishiwaki<sup>a,b</sup>, Hideaki Kojima<sup>c</sup>, Mitsuhiro Isaka<sup>c</sup>, Etsuro Bando<sup>a</sup>, Masanori Terashima<sup>a</sup>, Yasuhisa Ohde<sup>c,\*</sup>

<sup>a</sup> Division of Gastric Surgery, Shizuoka Cancer Center, 1007 Shimonagakubo, Nagaizumi-cho, Sunto-gun, Shizuoka, 411-8777, Japan

<sup>b</sup> Department of Gastroenterological Surgery, Okayama University Graduate School of Medicine, Dentistry and Pharmaceutical Sciences, 2-5-1 Shikata-cho, Kita-ku, Okayama, 700-8558, Japan

<sup>c</sup> Division of Thoracic Surgery, Shizuoka Cancer Center, 1007 Shimonagakubo, Nagaizumi-cho, Sunto-gun, Shizuoka, 411-8777, Japan

## ARTICLE INFO

## Article history:

Received 14 May 2020

Received in revised form 16 July 2020

Accepted 17 July 2020

## Keywords:

Gastric cancer

Pulmonary metastasis

Pulmonary resection

## ABSTRACT

**INTRODUCTION:** As pulmonary resection for metastatic gastric cancer has been rarely reported on, the role of metastasectomy remains unclear in such settings. We reviewed the clinicopathological characteristics and surgical outcomes of patients with metachronous pulmonary metastasis from gastric cancer (MPMGC) diagnosed using multi-detector computed tomography (MDCT) who underwent pulmonary resection.

**PRESENTATION OF CASE:** From September 2002 to May 2018, five patients underwent pulmonary resection for MPMGC at Shizuoka Cancer Center. All patients received curative resection for initial gastric cancer. Three patients received adjuvant chemotherapy. The median age at pulmonary resection was 70 years. The median disease-free interval between initial gastrectomy and MPMGC diagnosis was 41 months. The first site of recurrence was the lung in all patients. All patients were diagnosed as having primary lung cancer using MDCT before pulmonary resection and fit the surgical indication for primary lung cancer. Lobectomy was performed in three patients, while wedge resection was performed in two. The median overall survival following pulmonary resection was 79 (range, 18–89) months. Two patients experienced recurrence. While one showed recurrence in the mediastinal lymph node, in the other it was observed in the remnant lung; the latter underwent repeated pulmonary resection followed by systemic chemotherapy. Four patients survived for longer than 4 years after pulmonary resection.

**CONCLUSIONS:** Of the five patients with MPMGC diagnosed using MDCT who underwent pulmonary resection, long-term survival was achieved after pulmonary resection in four. Thus, pulmonary resection may be considered for those diagnosed with lung nodules after surgery for gastric cancer, and who fit the surgical indication for primary lung cancer.

© 2020 Published by Elsevier Ltd on behalf of IJS Publishing Group Ltd. This is an open access article under the CC BY-NC-ND license (<http://creativecommons.org/licenses/by-nc-nd/4.0/>).

## 1. Introduction

Following curative resection for gastric cancer, the most commonly observed sites of recurrence are the peritoneum and lymph nodes, while the most frequently noted site of hematogenous recurrence is the liver, followed by the lungs, brain, and bones [1–4]. Although the standard treatment for metastatic gastric cancer is systemic chemotherapy, surgical resection for liver metastasis is considered a treatment option for select patients according to Japanese gastric cancer treatment guidelines [5]. In our institute, surgical resection is performed for cases with liver metastasis from gastric cancer as clinical practice, with an associated median overall survival time of 49 months and 5-

**Abbreviations:** MPMGC, metachronous pulmonary metastasis from gastric cancer; MDCT, multi-detector computed tomography; PS, performance status; DFI, disease-free interval; TTF-1, thyroid transcription factor-1; CT, computed tomography.

\* Corresponding author.

**E-mail addresses:** [nori.nishiwaki@gmail.com](mailto:nori.nishiwaki@gmail.com) (N. Nishiwaki), [look\\_look\\_word@yahoo.co.jp](mailto:look_look_word@yahoo.co.jp) (H. Kojima), [mi.isaka@scchr.jp](mailto:mi.isaka@scchr.jp) (M. Isaka), [e.bando@scchr.jp](mailto:e.bando@scchr.jp) (E. Bando), [m.terashima@scchr.jp](mailto:m.terashima@scchr.jp) (M. Terashima), [y.ohde@scchr.jp](mailto:y.ohde@scchr.jp) (Y. Ohde).

<https://doi.org/10.1016/j.ijscr.2020.07.062>

2210-2612/© 2020 Published by Elsevier Ltd on behalf of IJS Publishing Group Ltd. This is an open access article under the CC BY-NC-ND license (<http://creativecommons.org/licenses/by-nc-nd/4.0/>).

year survival rate of 32% [6]. In contrast, the role of surgical resection for pulmonary metastasis from gastric cancer remains unclear.

The use of pulmonary metastasectomy has been proposed for solid tumors, such as sarcomas, adrenal cortical carcinomas and gastrointestinal cancers [7–9]. Although pulmonary resection for metastatic colorectal cancer is commonly performed in clinical practice, this is only based on retrospective studies; no randomized controlled trials have focused on the topic [9,10]. The in-progress Pulmonary Metastasectomy in Colorectal Cancer trial [11] is the first randomized control trial to be conducted in such settings.

Pulmonary metastasis from gastric cancer is normally associated with carcinomatous lymphangitis, malignant pleural effusion, numerous lesions, or concomitant metastatic sites [12,13], whereas solitary pulmonary metastasis from gastric cancer occurs extremely rarely. Therefore, pulmonary resection for metastatic gastric cancer has been rarely reported on. Moreover, the surgical outcomes of this procedure are not satisfactory as per previous reports [14–19], with a recent systematic review showing a median overall survival after lung resection of 45 (range, 1–123) months, and a median disease-free survival duration of 9 (range, 3–65) months [14]. However, that review was based on single-center retrospective reports of relatively small sample sizes, and the diagnostic modalities used for pulmonary metastasis were not described in detail [14–17]. As the efficacy of multi-detector computed tomography (MDCT) for pulmonary tumor diagnosis has been demonstrated [20], we unified the diagnoses of the present cases with modern diagnostic technology.

In this report, we present a review of the clinicopathological characteristics and surgical outcomes of patients with metachronous pulmonary metastasis from gastric cancer (MPMGC) diagnosed using MDCT who underwent pulmonary resection at Shizuoka Cancer Center [21]. Further, we evaluated the significance of surgical resection for patients with pulmonary nodules following surgery for gastric cancer.

## 2. Presentation of case

From September 2002 to May 2018, five patients underwent pulmonary resection for MPMGC at Shizuoka Cancer Center. The collection and analysis of data in this retrospective cohort study were approved by the Institutional Review Board of the Shizuoka Cancer Center (Approval No. 29-J31-30-1-3). Tumor stage and histological classification were determined according to the 3rd English edition of the Japanese Classification of Gastric Carcinoma [22] (Table 1). All patients underwent curative resection for initial gastric cancer. The initial tumor stage was Stage II or III in four patients; however, it was Stage IA in one. The histological type of gastric cancer was predominantly well-differentiated adenocarcinoma. The median disease-free interval (DFI) between initial gastrectomy and pulmonary metastasis diagnosis was 41 (range, 25–56) months. The first site of recurrence was the lung in all patients. The median interval between initial gastrectomy and pulmonary resection was 42 (range, 29–59) months.

The clinical courses are shown in Fig. 1. Three patients received adjuvant chemotherapy for initial gastric cancer. None of the patients received chemotherapy for the treatment of pulmonary metastasis before pulmonary resection.

The characteristics of the pulmonary metastases are shown in Table 2. The median age at pulmonary resection was 70 (range, 59–78) years. The Eastern Cooperative Oncology Group performance status (PS) was 0 in all patients. All patients were diagnosed using MDCT; four were diagnosed as having a single nodule, and

one as having two nodules (Fig. 2). Preoperative biopsy of the pulmonary nodules was performed in two patients bronchoscopically, leading to the diagnosis of adenocarcinoma; in the other patients, biopsy was not performed because of the nodule location. As it was difficult to differentiate the MPMGC from the primary lung cancer histologically and radiologically, all patients were diagnosed as having primary lung cancer before surgery.

Data on the surgical procedures used and pathological diagnoses are shown in Table 3. Although frozen section examinations were conducted on specimens obtained from four patients during surgery, only two patients received an MPMGC diagnosis. Lobectomy was performed in three patients, while wedge resection was performed in two; those two patients received limited resection according to the diagnosis of MPMGC by frozen section examination during surgery. The median surgery time was 226 (range, 67–305) minutes, and the median bleeding amount was 14 (range, 0–68) g. The median postoperative stay duration was 8 (range, 7–20) days, and no postoperative complications were observed.

The pulmonary nodules were histologically diagnosed as MPMGC with morphological similarity to the primary gastric cancer. In addition, immunohistochemistry was performed by staining thyroid transcription factor-1 (TTF-1) for diagnosis confirmation; all patients were negative for TTF-1. One patient had lymph node metastasis at the hilum. Although there was a divergence in the diagnosis of the number of nodules in one patient, the radiological and pathological diagnoses were almost identical regarding the number of metastases and nodule diameters.

The median overall survival duration following pulmonary resection was 79 (range, 18–89) months (Table 4). Three patients received chemotherapy after pulmonary resection and the other two did not due to patient preference. Two patients showed recurrence. One experienced recurrence in the mediastinal lymph node during systemic chemotherapy following pulmonary resection. Although the patient continued chemotherapy after recurrence with a regimen change, he died due to disease progression. The other patient showed recurrence in the remnant lung, underwent repeated pulmonary resection followed by systemic chemotherapy, and achieved long-term survival. Of the five patients, four survived for longer than 4 years following pulmonary resection.

## 3. Discussions

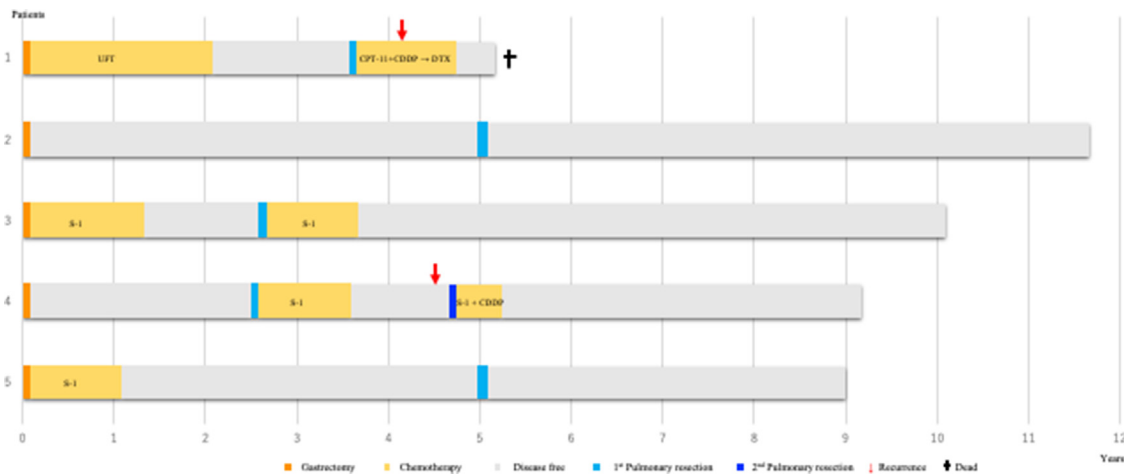
In this report, we present the cases of five patients who underwent pulmonary resection for MPMGC, demonstrating remarkably better survival values following resection compared to previous reports [14–18]. All patients showed good PS and DFI values, and the preoperative diagnosis was primary lung cancer across all cases. Three patients were pathologically diagnosed as having a single lesion and achieved long disease-free survival, while two with multiple lesions showed recurrence after surgery; one patient underwent repeated resection and achieved long-term survival.

Pulmonary resection for MPMGC could be the treatment option for select patients. According to current treatment guidelines, the standard treatment for MPMGC is systemic chemotherapy [5]; however, the associated survival outcomes are not satisfactory. The median OS in patients with pulmonary metastasis is 4 months, and even in those treated with chemotherapy, the 5-year survival rate is only 2–4% [12,23]. Pulmonary resection for MPMGC has been rarely reported on owing to its low frequency of use; additionally, it has previously been considered futile [19]. Recently, however, several reports have demonstrated long-term survival following pulmonary resection for MPMGC [15,24]; therefore, pulmonary metastasectomy has been reconsidered as a treatment option in such settings.

**Table 1**  
Clinicopathological features of the five patients.

Patient	Age at gastrectomy (y)	Sex	Type of gastrectomy	Residual tumor	Pathological stage	Histological type	DFI following gastrectomy (months)	First site of recurrence	Interval between gastrectomy and pulmonary resection (months)
1	67	Male	DG	R0	IIA	differentiated	41	Lung	42
2	54	Female	TG	R0	IIA	undifferentiated	56	Lung	59
3	63	Male	TG	R0	IIIA	differentiated	27	Lung	30
4	67	Male	DG	R0	IA	differentiated	25	Lung	29
5	74	Male	DG	R0	IIA	differentiated	47	Lung	49

DFI, disease-free interval; DG, distal gastrectomy; TG, total gastrectomy.

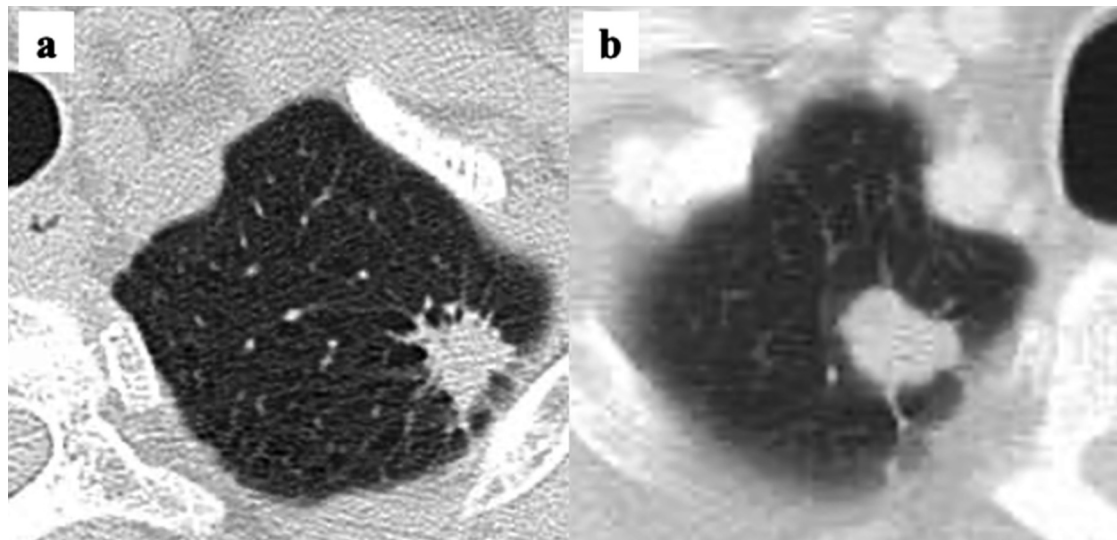


**Fig. 1.** Clinical courses of the five patients.

**Table 2**  
Characteristics of pulmonary metastases.

Patient	Age at pulmonary resection (y)	PS	Tumor location	Preoperative number of lesions	Preoperative tumor size (cm)	Preoperative clinical diagnosis	Biopsy	Histological diagnosis
1	70	0	Apical segment of right upper lobe	1	2.8	Primary > Meta	+	adenocarcinoma
2	59	0	Apical segment of left upper lobe	1	1.4	Primary > Meta	-	-
3	65	0	Apical segment of right upper lobe	1	1.0	Primary > Meta	-	-
4	70	0	Apical segment of right upper lobe lateral segment of right lower lobe	2	1.0, 0.8	Primary or Meta	-	-
5	78	0	Apical segment of right upper lobe	1	1.8	Primary or Meta	+	adenocarcinoma

PS, performance status.



**Fig. 2.** Multi-detector computed tomography showed pulmonary nodules. (a) In patient 2, the nodule was found at the apical segment of the left upper lobe and was considered to be primary lung cancer rather than metachronous pulmonary metastasis from gastric cancer (MPMGC). (b) On the other hand, in patient 3, the nodule was found at the apical segment of the right upper lobe, making it difficult to differentiate between MPMGC and primary lung cancer.

**Table 3**  
Surgical procedures and pathological diagnoses of the five patients.

Patient	Surgical procedure	Frozen section examination	Histological diagnosis	Pathological maximum tumor size (cm)	LN metastasis
1	Lobectomy + systematic nodal dissection	–	–	3	4.0 Hilar
2	Lobectomy + systematic nodal dissection	+	adenocarcinoma	1	1.2 None
3	Lobectomy + systematic nodal dissection	+	adenocarcinoma	1	2.0 None
4	Wedge resection	+	metastatic gastric cancer	2	1.0 None
5	Wedge resection	+	metastatic gastric cancer	1	1.7 None

LN, lymph node.

**Table 4**  
Outcomes of the five patients.

Patient	Patterns of recurrence	DFS following pulmonary resection (months)	OS following pulmonary resection (months)	OS following gastrectomy (months)	Status
1	Mediastinal LN	6	18	61	Dead
2	Disease-free	79	79	138	Alive
3	Disease-free	89	89	120	Alive
4	Lung	21	79	108	Alive
5	Disease-free	49	49	96	Alive

DFS, disease-free survival; OS, overall survival; LN lymph node.

Although previous systematic reviews were conducted with the aim of selecting patients in whom long-term survival can be achieved by pulmonary metastasectomy, they failed to demonstrate any statistically significant prognostic factors [14,15]. However, those studies consistently reported a trend for better survival in cases with a single metastasis and long DFI [7,14,15,17]. These studies may have failed to show significant prognostic factors in part due to the wide range of study periods that were included, and the diagnostic modalities used for pulmonary metastasis. MDCT has greater sensitivity than conventional computed tomography (CT) in the detection of small lesions [20]. In the present report, all tumors were diagnosed using modern diagnostic technologies, and the diagnoses were almost identical to those achieved through pathological study. Our patients achieved better survival values than those in previous studies as we diagnosed tumors at an early stage and did not miss the presence of small duplicate lesions using sensitive MDCT. Although no study has previously demonstrated a diagnostic modality for metastatic gastric cancer or compared radiological and pathological diagnoses, there is a chance that small multiple metastases were presented and missed. In our study, the patient with a single pulmonary metastasis diagnosed using modern diagnostic technology who showed a long DFI after surgery for gastric cancer may be considered a good candidate for metastasectomy.

It may be reasonable to consider pulmonary resection for patients with pulmonary nodules after surgery for gastric cancer who fit the surgical indication for primary lung cancer. All the patients in this study were clinically diagnosed with primary lung cancer before pulmonary resection; this is consistent with previous reports that stated that lung cancer is among frequently presenting secondary malignancies following gastric cancer surgery [25], and that the lungs are less commonly the initial sites of postoperative gastric cancer recurrence [26]. Nakamura et al. reported difficulties in the performance of differential histological diagnosis between primary lung cancer and metastasis; thus, surgical resection is the only accurate evaluation method [27]. With regards to the surgical procedures used for metastatic gastric cancer, previous studies failed to show the advantages of lobectomy over limited resection [14,15]. In our study, two patients underwent wedge resection; one survived without recurrence while the other showed recurrence in the remnant lung. Although a very small number of cases

were included in this present report, even limited resection may aid in the achievement of long disease-free durations in cases with a single lesion. These findings suggest that when a lung tumor is observed after surgery for gastric cancer, it is reasonable to indicate pulmonary resection according to the primary lung cancer. Furthermore, even if the tumor is diagnosed as MPMGC pre-operatively or during surgery, limited resection may be sufficient.

Iida et al. proposed that metastases to the lung and upstream organs, or liver, can be regarded as “semilocal” disease, explaining the favorable outcomes after metastasectomy [28]. Therefore, pulmonary metastasectomy still has the potential to yield better survival values as long as the lung’s defense system is functioning and is capable of preventing tumor cells from spreading to the downstream organs. As previous studies have reported, the most commonly observed site of recurrence after pulmonary metastasectomy is the lung, and patients with multiple lesions have a high risk of recurrence. However, some patients achieve long-term survival after repeat metastasectomy [14,29]. Thus, careful follow-up using periodic CT for early detection is strongly recommended after pulmonary metastasectomy, especially for patients with pathologically proven multiple lesions.

The present study has a few limitations. It was a retrospective study performed in a single institution; thus, the study population was relatively small. Although this study was underpowered, we only included patients who were diagnosed using modern diagnostic technology. In the future, large-scale multicenter studies should be performed to investigate pulmonary resection for MPMGC diagnosed using MDCT.

#### 4. Conclusions

In this report, we presented our experiences with five patients in whom MPMGC was diagnosed using MDCT and who underwent pulmonary resection, and we observed survival outcomes that were remarkably better than those in previous reports. Pulmonary resection may be considered for patients diagnosed with pulmonary nodules after surgery for gastric cancer, who fit the surgical indications for primary lung cancer; moreover, in select patients, such as those with good PS and DFI values, long-term survival may be achieved even if the nodule is diagnosed as MPMGC post-operatively.

## Declaration of Competing Interest

The authors have no financial or personal circumstances with pharmacists or organizations that could influence the originality of this manuscript.

## Funding

There is no financial funding that contributes to collecting, interpreting data, writing, and publishing the manuscript.

## Ethical approval

The collection and analysis of data in this retrospective cohort study were approved by the Institutional Review Board of the Shizuoka Cancer Center (Approval No. 29-J31-30-1-3).

## Consent

All patients provided consent for the publication of images.

## Author contribution

NN and HK were involved in gathering the patients' clinical data. NN, HK, MT, and YO wrote the manuscript. MI and EB participated in the study design. All authors read and approved the final manuscript.

## Registration of research studies

Research registry UIN: TCTR20200708004.

## Guarantor

Dr. Yasuhisa Ohde.

## Provenance and peer review

Not commissioned, externally peer-reviewed.

## Acknowledgements

The authors acknowledge the following participating investigators in this study: Hayato Konno, Tetsuya Mizuno, Satoshi Kamiya, Makoto Hikage, Yutaka Tanizawa, and Hirofumi Yasui. We would like to thank Editage ([www.editage.com](http://www.editage.com)) for English language editing.

## References

- [1] Y. Maehara, S. Hasuda, T. Koga, Postoperative outcome and sites of recurrence in patients following curative resection of gastric cancer, *Br. J. Surg.* 87 (2000) 353–357.
- [2] Y.W. Moon, H.C. Jeung, S.Y. Rha, Changing patterns of prognosticators during 15-year follow-up of advanced gastric cancer after radical gastrectomy and adjuvant chemotherapy: a 15-year follow-up study at a single Korean institute, *Ann. Surg. Oncol.* 14 (2007) 2730–2737.
- [3] C.H. Yoo, S.H. Noh, D.W. Shin, Recurrence following curative resection for gastric carcinoma, *Br. J. Surg.* 87 (2000) 236–242.
- [4] S. Sakuramoto, M. Sasako, T. Yamaguchi, Adjuvant chemotherapy for gastric cancer with S-1, an oral fluoropyrimidine, *N. Engl. J. Med.* 357 (2007) 1810–1820.
- [5] Japanese Gastric Cancer Association, Japanese gastric cancer treatment guidelines 2014 (ver. 4), *Gastric Cancer* 20 (2017) 1–19.
- [6] T. Tatsubayashi, Y. Tanizawa, Y. Miki, Treatment outcomes of hepatectomy for liver metastases of gastric cancer diagnosed using contrast-enhanced magnetic resonance imaging, *Gastric Cancer* 20 (2017) 387–393.
- [7] T. Treasure, M. Milosevic, F. Fiorentino, Pulmonary metastasectomy: what is the practice and where is the evidence for effectiveness? *Thorax* 69 (2014) 946–949.
- [8] H. Suzuki, M. Kiyoshima, M. Kitahara, Long-term outcomes after surgical resection of pulmonary metastases from colorectal cancer, *Ann. Thorac. Surg.* 99 (2015) 435–440.
- [9] T. Treasure, Pulmonary Metastasectomy for Colorectal Cancer: recent reports prompt a review of the available evidence, *Curr. Colorectal Cancer Rep.* 10 (2014) 296–302.
- [10] M. Gonzalez, A. Poncet, C. Combescure, Risk factors for survival after lung metastasectomy in colorectal cancer patients: a systematic review and meta-analysis, *Ann. Surg. Oncol.* 20 (2013) 572–579.
- [11] T. Treasure, L. Fallowfield, B. Lees, Pulmonary metastasectomy in colorectal cancer: the PulMiCC trial, *Thorax* 67 (2012) 185–187.
- [12] J.H. Kong, J. Lee, C.A. Yi, Lung metastases in metastatic gastric cancer: pattern of lung metastases and clinical outcome, *Gastric Cancer* 15 (2012) 292–298.
- [13] K. Hirakata, H. Nakata, T. Nakagawa, CT of pulmonary metastases with pathological correlation, *Semin. Ultrasound CT MR* 16 (1995) 379–394.
- [14] P. Aurello, N. Petrucciani, D. Giulitti, Pulmonary metastases from gastric cancer: is there any indication for lung metastasectomy? A systematic review, *Med. Oncol.* 33 (2016) 9.
- [15] C.D. Kemp, M. Kitano, S. Kerkar, Pulmonary resection for metastatic gastric cancer, *J. Thorac. Oncol.* 5 (2010) 1796–1805.
- [16] Y. Iijima, H. Akiyama, M. Atari, Pulmonary resection for metastatic gastric cancer, *Ann. Thorac. Cardiovasc. Surg.* 22 (2016) 230–236.
- [17] S. Shiono, T. Sato, H. Horio, Outcomes and prognostic factors of survival after pulmonary resection for metastatic gastric cancer, *Eur. J. Cardiothorac. Surg.* 43 (2013) e13–16.
- [18] Y. Kobayashi, T. Fukui, S. Ito, Pulmonary metastasectomy for gastric cancer: a 13-year single-institution experience, *Surg. Today* 43 (2013) 1382–1389.
- [19] Y. Kanemitsu, H. Kondo, H. Katai, Surgical resection of pulmonary metastases from gastric cancer, *J. Surg. Oncol.* 69 (1998) 147–150.
- [20] Y. Zhang, J.W. Qiang, Y. Shen, Using air bronchograms on multi-detector CT to predict the invasiveness of small lung adenocarcinoma, *Eur. J. Radiol.* 85 (2016) 571–577.
- [21] R.A. Agha, M.R. Borrelli, R. Farwana, The PROCESS 2018 statement: updating consensus preferred reporting of CasE series in surgery (PROCESS) guidelines, *Int. J. Surg.* 60 (2018) 279–282.
- [22] Japanese Gastric Cancer Association, Japanese classification of gastric carcinoma: 3rd English edition, *Gastric Cancer* 14 (2011) 101–112.
- [23] M. Ohkuwa, A. Ohtsu, N. Boku, Long-term results for patients with unresectable gastric cancer who received chemotherapy in the Japan Clinical Oncology Group (JCOG) trials, *Gastric Cancer* 3 (2000) 145–150.
- [24] C. Tanai, T. Hamaguchi, S. Watanabe, A case of long-term survival after surgical resection of solitary pulmonary metastasis from gastric cancer, *Jpn. J. Clin. Oncol.* 40 (2010) 85–89.
- [25] T. Sano, M. Sasako, T. Kinoshita, Recurrence of early gastric cancer. Follow-up of 1475 patients and review of the Japanese literature, *Cancer* 72 (1993) 3174–3178.
- [26] M. Katai, T. Aizawa, N. Ohara, Acquired amegakaryocytic thrombocytopenic purpura with humoral inhibitory factor for megakaryocyte colony formation, *Intern. Med.* 33 (1994) 147–149.
- [27] T. Nakamura, Y. Homma, N. Miyata, Only surgical resection can identify the second primary lung cancer out of the metastasis after gastric cancer surgery, *Jpn. J. Clin. Oncol.* 42 (2012) 609–611.
- [28] T. Iida, H. Nomori, M. Shiba, Prognostic factors after pulmonary metastasectomy for colorectal cancer and rationale for determining surgical indications: a retrospective analysis, *Ann. Surg.* 257 (2013) 1059–1064.
- [29] H. Nakayama, S. Ichinose, Y. Kato, Long-term survival after a surgical resection of pulmonary metastases from gastric cancer: report of a case, *Surg. Today* 38 (2008) 150–153.

## Open Access

This article is published Open Access at [sciencedirect.com](http://sciencedirect.com). It is distributed under the [IJSCR Supplemental terms and conditions](#), which permits unrestricted non commercial use, distribution, and reproduction in any medium, provided the original authors and source are credited.