

Available online at [www.sciencedirect.com](http://www.sciencedirect.com)

ScienceDirect

journal homepage: [www.elsevier.com/locate/radcr](http://www.elsevier.com/locate/radcr)

## Case Report

# A case of a myxoma within the obturator externus muscle

Ana C. Belzarena, MD\*, Michael Wright, BS, David M. Joyce, MD

Moffitt Cancer Center, 12902 Magnolia Dr., Tampa, FL 33612, USA

### ARTICLE INFO

#### Article history:

Received 7 April 2019

Revised 27 April 2019

Accepted 27 April 2019

Available online 10 May 2019

#### Keywords:

Intramuscular myxoma

Myxoid neoplasm

Obturator externus

### ABSTRACT

Intramuscular myxomas (IM) are rare benign tumors of mesenchymal origin. These tumors have a high myxoid content and a nonspecific radiologic appearance. Here we describe the case of a patient with an IM in an infrequent location; within the obturator externus muscle. A singular approach was utilized for the resection of this tumor in such rare location.

Despite IM being benign tumors, patients may require a surgical excision due to the difficulty of differentiating these tumors, with unreliable imaging features, from other myxoid soft tissue masses.

© 2019 The Authors. Published by Elsevier Inc. on behalf of University of Washington.

This is an open access article under the CC BY-NC-ND license.

(<http://creativecommons.org/licenses/by-nc-nd/4.0/>)

## Background

Myxomas are mesenchymal benign tumors of unknown etiology, characterized by abundant extracellular myxoid matrix secreted by the tumor cells [1]. Intramuscular myxomas (IM) were initially described by Enzinger in 1965, as a solitary myxoid mass arising in a large skeletal muscle [2]. Other than intramuscular, other subtypes of myxomas exist such as juxta-articular myxoma, aggressive angiomyxoma, superficial angiomyxoma, and nerve sheath myxoma [3]. IM usually occur in patients between the fourth and sixth decade and have female predominance [4]. The clinical presentation is of a slow growing painless mass, nonetheless the majority of the patients are asymptomatic. Other possible presentations are usually nonspecific and depend on the affected area and the size of the mass [5]. Most frequently they appear as a solitary mass, but they can also be a part of a syndrome such as Mazabraud's and present with multiple masses in

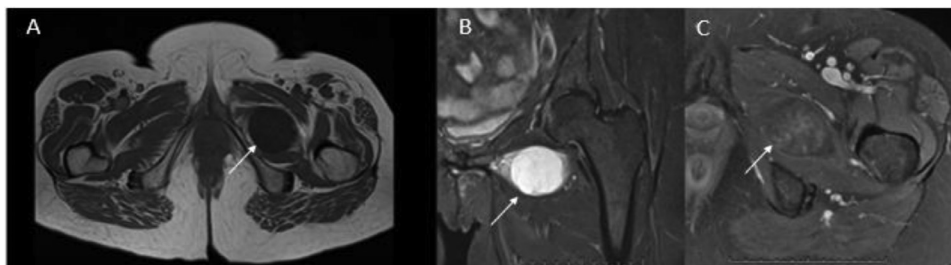
association with fibrous dysplasia [6]. McCune-Albright is another syndrome characterized by the presence of myxomas, polyostotic fibrous dysplasia, café-au-lait spots, and precocious puberty [7]. Almost half of these tumors are present in the thigh, with much less frequency they occur in the buttock, leg, and arm [8]. These rare tumors have an incidence of one case per million population a year [9]. Imaging studies should be performed prior to any surgical procedure, with contrasted Magnetic Resonance Imaging (MRI) being the gold standard for the diagnosis of soft tissue tumors. Myxomas imaging characteristics may overlap with some other neoplasms with a myxoid component including soft tissues sarcomas such as a myxoid liposarcoma or a myxofibrosarcoma among others, thus correct imaging tools and careful assessment of the diagnostic images is paramount [10,11]. The treatment of choice for this benign tumor is a marginal complete excision; local recurrences are rare and there is no risk of metastases or malignant differentiation [12].

\* Corresponding author.

E-mail address: [belzarenaa@hss.edu](mailto:belzarenaa@hss.edu) (A.C. Belzarena).

<https://doi.org/10.1016/j.radcr.2019.04.018>

1930-0433/© 2019 The Authors. Published by Elsevier Inc. on behalf of University of Washington. This is an open access article under the CC BY-NC-ND license. (<http://creativecommons.org/licenses/by-nc-nd/4.0/>)



**Picture 1 – MRI images of the pelvic region. T1-weighted image on the axial plane (A) showing a well-defined hypointense mass centered in obturator externus muscle (arrow). On a T2 fat-suppressed sequence (B) we observe the same mass (arrow) on the coronal plane with hyperintensity and internal septations, no surrounding edema is observed. A gadolinium contrasted image of the axial plane (C) depicting the tumor (arrow) with weak enhancement.**

Here we report the case of a patient with an IM in the obturator externus muscle that was managed surgically. A singular approach was utilized for the resection of this tumor in such rare location.

### Case presentation

A 61-year-old previously healthy woman presented with a recent complaint of pain and discomfort over her left anterior ischium, elicited only at extreme ranges of motion in her left hip. There was no history of trauma, weight loss, fever, swelling, or erythema. No masses were appreciated on physical exam. Strength and range of motion of her hip, knee, and ankle were normal and equal bilaterally. Sensation to light touch remained intact in all dermatomes of both legs.

The patient had a pelvis and left hip radiographs performed at an outside institution prior to reaching care at our center. On the radiographs no mass or abnormality is observed on the area of discomfort. MRI with contrast was then obtained and revealed a 4.5-cm heterogeneous mass within the body of the left obturator externus muscle. The mass presented with heterogeneous, patchy internal enhancement as well as weak peripheral enhancement on postgadolinium sequences. On T2 sequences the mass demonstrated hyperintensity and internal septations, no peripheral edema was seen (Picture 1). Imaging was reported as most concerning for myxoma, atypical peripheral nerve sheath tumor, or sarcoma such as a synovial sarcoma or a myxoid liposarcoma.

### Treatment

We elected to not to pursue an anterior approach through the pectineus muscle to avoid the femoral artery, vein and nerve, as well as to avoid the medial circumflex artery that lies lateral and deep to pectineus. The tumor was not palpable and based on the imaging a 7-cm length incision was made in the medial proximal thigh starting at the groin crease and extending distally (Picture 2). A plane was identified between the adductor longus and the gracilis muscle. The adductor brevis was re-

tracted, and the tumor was palpated behind it, in the obturator externus muscle substance (Picture 2). The mass was well encapsulated and most of it easily separated from the surrounding muscle. The tumor was of gelatinous consistency and a whitish-gray color; it measured 4.5 cm by 3.3cm by 3.5cm. The histologic examination confirmed the diagnosis of an IM. The partially encapsulated mass under the microscope revealed uniform spindle to stellate-shaped cells with eosinophilic cytoplasm and small nuclei surrounded by abundant myxoid stroma. Mitoses, pleomorphism, hyperchromasia, or necrosis were not present.

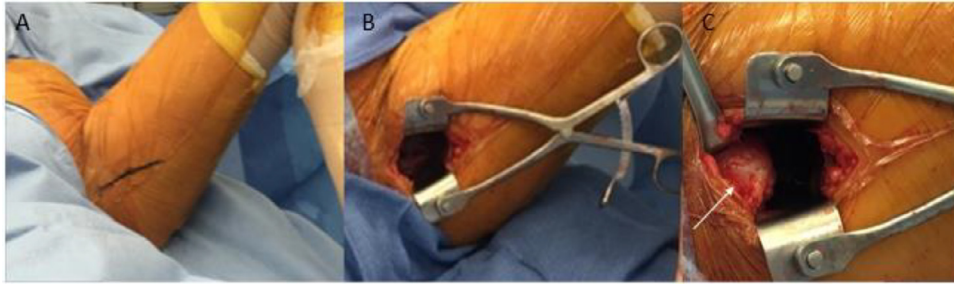
In the follow-up the patient presented with total resolution of the previous symptoms.

### Discussion

Even though the true etiology of this rare tumor remains unknown, some authors tried to explain the pathogenesis behind it, proposing that this tumor is the result of the failure to produce mature collagen by stellate cells that may actually be altered fibroblasts [2]. Enzinger was the first one to describe an IM, but prior to him Virchow reported on a benign tumor with a consistency similar to the tissue in the umbilical cord. He was then followed by Stout, who in 1948 characterized this tumor histologically as composed by a myxoid stroma with undifferentiated stellate cells embedded in it [1,13].

In most patients IM are asymptomatic, when they do present symptoms, they could range from a painless growing mass or like in our patient a mildly painful mass. These benign tumors do not invade the surrounding structures, but they can cause symptoms by compression of structures such as nerves, vessels, or even the nearby muscles. It is important in these patients to look for other masses or bone lesions to rule out syndromes such as Mazabraud's or McCune-Albright's [6,7]. Our patient had a solitary mass and presented with no associated bone abnormalities, as observed in the MRI (Picture 1).

In the case presented we opted for obtaining a contrasted MRI previous to the surgical procedure since this was the study that could provide us with more information regarding the diagnosis and the planning of the resection and is the



**Picture 2 – Clinical images obtained during the procedure. On the left image (A) a 7-cm skin incision is drawn over the proximal medial aspect of the left thigh. On the center image (B), deeper dissection, creating a plane between the adductor longus, retracted superiorly, and the gracilis muscle, retracted inferiorly, is shown. On the right image (C) the tumor (arrow) is visualized prior to resection, the mass is of whitish color, soft, and well circumscribed. (Color version of figure is available online.)**

current standard of care for patients with soft tissue neoplasms. On radiograph these tumors may present as a nonspecific mass with no calcifications and on ultrasound they appear as a cystic hypoechoic lesion. Under computed tomography the classic image is of a cystic homogenous mass with low attenuation [11]. On MRI, IM can be observed as homogenous masses with sharp borders, hypointense to muscle on T1-weighted sequences and brighter than fat on T2-weighted ones. Myxoid matrix has a high content of water resulting in those characteristic MRI images, that can also be observed in other myxoid tumors [14]. The potential list of differential malignant diagnoses should include myxoid liposarcoma, myxoid malignant fibrous histiocytoma, low-grade fibromyxoid sarcoma, and extra skeletal myxoid chondrosarcoma among others. On the contrasted sequences internal enhancement can be observed. According to some authors a peripheral fat rim and enhancement in the surrounding muscles under T2-weighted sequences are the most reliable findings to diagnose an IM [10]. In the case of our patient, the tumor did present with a fat layer surrounding it, but we did not observe enhancement in the adjacent muscles. Previous studies have characterized myxomas under Fluorine-18 fluorodeoxyglucose positron emission tomography-computed tomography (F-18 FDG PET-CT), as a mass with low uptake, with SUV values ranging from 1.3 to 3.2 for diagnostic and control of residual disease purposes [15–17].

In the setting of a doubtful diagnosis a biopsy would be indicated the majority of times prior to the surgical resection, after a thorough multidisciplinary discussion at a sarcoma tumor board we elected not to perform it in this patient. Tumors beyond 5 cm in their longest dimension are considered suspicious of malignancy, which was not the scenario encountered [18]. Additionally, if the tumor was ultimately diagnosed as malignant after its resection, with its small size we could have easily achieved negative margins, the treatment of choice for soft tissue sarcomas smaller than 5 cm. Furthermore, diagnosing myxoid tumors on a fine or core needle biopsy can be extremely challenging for the pathologist and in previously published series, the accuracy of needle biopsies for the correct diagnosis of IM was only 38% [12].

On gross examination IM have a round-oval shape and are well circumscribed, though they only possess a partial pseudocapsule [2]. Under histologic examination myxomas are composed of undifferentiated stellate cells in a myxoid stroma with reticulin fibers, vascularization is poor, and necrosis or atypia are not expected [19]. In the year 2000 the GNAS mutation associated to myxomas was discovered and though it is only present in 29%-61% of the tumors it can be helpful in differentiation IM from low-grade myxofibrosarcomas [20,21].

Other approaches have been described to access the obturator muscles, for instance to drain abscess in the pediatric population or to access the ischium during the Tonnis periacetabular osteotomy, but the plane described was between the adductor longus and pectineus muscle [22,23]. A similar approach is also utilized in general surgery for the treatment of obturator hernias, but then again, this approach is over the adductor longus and cuts through the pectineus muscle to get to the obturator foramen [24]. For our patient we chose the path that would have rendered the easiest approach to get to the tumor. Thus, we performed an intermuscular plane between the adductor longus and the gracilis, followed by finger dissection through the adductor brevis, since the tumor was easily felt just behind it.

## Conclusion

In summary, IM are benign tumors with good prognosis however they may be sometimes difficult to characterize on imaging. For such reason patients may opt to undergo a surgical resection. Our case presented with an unusual location, which required an unusual approach to reach the mass within the deep root of the lower extremity.

## Supplementary materials

Supplementary material associated with this article can be found, in the online version, at doi:[10.1016/j.radcr.2019.04.018](https://doi.org/10.1016/j.radcr.2019.04.018).

## REFERENCES

- [1] Stout AP. Myxoma, the tumor of primitive mesenchyme. *Ann Surg* 1948;127:706–19.
- [2] Enzinger FM. Intramuscular myxoma; a review and follow-up study of 34 cases. *Am J Clin Pathol* 1965;43:104–13.
- [3] Dormand EL, Prabhu-Desai A, Rice AJ, Rosin RD. Not all pain in the left iliac fossa is diverticular disease: a case study of a psoas myxoma and review. *Surgeon* 2006;4:239–43. doi:10.1016/S1479-666X(06)80066-1.
- [4] Rachidi S, Sood AJ, Rumboldt T, Day TA. Intramuscular myxoma of the paraspinal muscles: a case report and systematic review of the literature. *Oncology Letters* 2016;11(1):466–70. doi:10.3892/ol.2015.3864.
- [5] Miettinen M, Höckerstedt K, Reitamo J, Tötterman S. Intramuscular myxoma—a clinicopathological study of twenty-three cases. *Am J Clin Pathol* 1985;84:265–72.
- [6] Kabukcuoglu F, Kabukcuoglu Y, Yilmaz B, Erdem Y, Evren I. Mazabraud's syndrome: intramuscular myxoma associated with fibrous dysplasia. *Pathol. Oncol. Res.* 2004;10(2):121–3. doi:10.1007/BF02893467.
- [7] Diaz A, Danon M, Crawford J. McCune-Albright syndrome and disorders due to activating mutations of GNAS1. *J Pediatr Endocrinol Metabolism* 2007;20(8):853–80.
- [8] Allen PW. Myxoma is not a single entity: a review of the concept of myxoma. *Ann Diagn Pathol* 2000;4(2):99–123. doi:10.1016/S1092-9134(00)90019-4.
- [9] Baltu Y, ŞM Arikan, Dölen UC, Uzun H, Bı Alkan, Aydın O. Intramuscular myxoma: clinical and surgical observation notes on eleven cases. *Int. Orthop* 2017;41(4):837–43. doi:10.1007/s00264-016-3396-8.
- [10] Bancroft LW, Kransdorf MJ, Menke DM, O'Connor MI, Foster WC. Intramuscular myxoma: characteristic MR imaging features. *AJR Am J Roentgenol* 2002;178:1255–9.
- [11] Murphey MD, McRae GA, Fanburg-Smith JC, Temple HT, Levine AM, Abouafia AJ. Imaging of soft-tissue myxoma with emphasis on CT and MR and comparison of radiologic and pathologic findings. *Radiology* 2002;225:215–24.
- [12] Silver WP, Harrelson JM, Scully SP. Intramuscular myxoma: a clinicopathologic study of 17 patients. *Clin Orthop Relat Res* 2002;403:191–7. doi:10.1097/00003086-200210000-00028.
- [13] Virchow R. Cellular pathology. As based upon physiological and pathological histology. Lecture XVI-Atheromatous affection of arteries. 1858. *Nutr Rev* 1989;47:23–5. doi:10.1111/j.1753-4887.1989.tb02747.x.
- [14] Petscavage-Thomas JM, Walker EA, Logie CI, Clarke LE, Duryea DM, Murphey MD. Soft-tissue myxomatous lesions: review of salient imaging features with pathologic comparison. *RadioGraphics* 2014;34(4):964–80. doi:10.1148/rg.344130110.
- [15] Miyake M, Tateishi U, Maeda T, Arai Y, Seki K, Hasegawa T, et al. F-18 fluorodeoxyglucose positron emission tomography finding of Mazabraud syndrome. *Clin Nucl Med* 2006;31:627–9.
- [16] Zade A, Ahire A, Shetty S, Rai S, Bokka R, Velumani V, et al. Fluorine-18 fluorodeoxyglucose positron emission tomography-computed tomography in evaluation of residual intramuscular myxoma. *Indian J Nucl Med* 2015;30(1):75–7.
- [17] Ho L, Wassef H, Henderson R, Seto J. F-18 fluorodeoxyglucose positron emission tomography/computed tomography imaging in left thigh intramuscular myxoma. *Clin Nucl Med* 2009;34:224–5.
- [18] Johnson CJD, Pynsent PB, Grimer RJ. Clinical features of soft tissue sarcomas. *Ann R Coll Surg Engl* 2001;83(3):203–5.
- [19] Luna A, Martinez S, Bossen E. Magnetic resonance imaging of intramuscular myxoma with and without fibrous dysplasia and a review of the literature. *Skeletal Radiol* 2005;34(1):19–28. doi:10.1007/s00256-004-0848-9.
- [20] Okamoto S, Hisaoka M, Ushijima M, Nakahara S, Toyoshima S, Hashimoto H. Activating Gs(alpha) mutation in intramuscular myxomas with and without fibrous dysplasia of bone. *Virchows Arch* 2000;437(2):133–7. doi:10.1007/s004280000217.
- [21] Delaney D, Diss TC, Presneau N, Hing S, Berisha F, Idowu BD, et al. GNAS1 mutations occur more commonly than previously thought in intramuscular myxoma. *Mod Pathol* 2009;22(5):718–24. doi:10.1038/modpathol.2009.32.
- [22] Menge TJ, Cole HA, Mignemi ME, Corn WC, Martus JE, Lovejoy SA, et al. Medial approach for drainage of the obturator musculature in children. *J Pediatr Orthopaedics* 2014;34(3):307–15. doi:10.1097/bpo.0000000000000118.
- [23] Bilgili F, Gurses IA, Ozkaya U, Parmaksizolu AS, Çetner Kale A. Ischial and pubic osteotomies performed by medial approach during periacetabular osteotomies: an anatomical study. *Acta Orthopaedica Et Traumatologica Turcica* 2013;47(1):43–7. doi:10.3944/aott.2013.3026.
- [24] Petrie A, Tubbs RS, Matusz P, Shaffer K, Loukas M. Obturator hernia: anatomy, embryology, diagnosis, and treatment. *Clin Anat* 2011;24:562–9.