

Case Report

A case report of cutaneous mucormycosis of the hand after minor trauma in a patient with acute myeloid leukaemia

Tazio Maleitzke^{a,b,c,*}, Katharina Stahnke^a, Andrej Trampuz^a, Sven Märdian^a

^a Center for Musculoskeletal Surgery, Charité - Universitätsmedizin Berlin, Augustenburger Platz 1, 13353 Berlin, Germany

^b Julius Wolff Institute, Charité - Universitätsmedizin Berlin, Augustenburger Platz 1, 13353 Berlin, Germany

^c Berlin Institute of Health (BIH), 10178 Berlin, Germany

ARTICLE INFO

Keywords:

Cutaneous mucormycosis
Fungal infection
Mucorales
Immunosuppression
Leukaemia

ABSTRACT

Background: Mucormycosis is a rare but life-threatening infection, caused by fungi of the Mucorales order, which can be found in soil, rotting leaves or on animals. Through characteristic angioinvasive growth, infections with mucor spores can occur as a pulmonary, rhinocerebral or cutaneous form. Infections mainly affect immunosuppressed patients with a history of uncontrolled diabetes or haematological malignancies, among others. Treatment is multimodal and requires an immediate combination of intravenous amphotericin B therapy and serial surgical debridements. Only a limited number of cases of cutaneous mucormycosis of the hand have been documented and described previously.

Case presentation: We report a cutaneous mucormycosis in an elderly patient with a therapy-resistant acute myeloid leukaemia after a minor trauma on his right hand, sustained whilst gardening. The fungal infection was treated with serial radical debridements, vacuum-assisted negative-pressure wound closure technique and intravenous antifungals. Despite successful eradication of the fungal infection, a palliative open wound care concept was implemented during the terminal course of the patient's leukaemia.

Conclusions: Cutaneous mucormycosis is a rare but fulminant fungal infection mostly affecting immunosuppressed patients. Survival is possible when diagnosed and treated early, yet mortality rates remain high.

Background

Mucormycosis is an invasive and rapidly progressing fungal infection caused by *Mucorales* organisms of the *Zygomycota* family. The ubiquitous filamentous fungi (molds) are frequently present in soil, decaying plants and on animals. More than 200 species belong to the *Mucorales* order, including *Sporodiniella*, *Syzygites*, and *Rhizopus* of the *Rhizopodaceae* family [1]. Mucormycosis predominantly affects immunosuppressed patients suffering from haematological malignancies, advanced human immunodeficiency virus (HIV) infection or uncontrolled diabetes mellitus. Infections include pulmonary, rhinocerebral, cutaneous or disseminated manifestations. First-line treatment consists of intravenous antifungal therapy with liposomal amphotericin B and radical surgical debridement. High morbidity and mortality are related to the high virulence of the fungus, its resistance to innate host defence and its angioinvasive growth, which leads to tissue necrosis and haematogenous dissemination [2]. The median time from first symptoms to

* Corresponding author at: Charité - Universitätsmedizin Berlin Center for Musculoskeletal Surgery, Augustenburger Platz 1, 13353 Berlin, Germany

E-mail address: tazio.maleitzke@charite.de (T. Maleitzke).

<https://doi.org/10.1016/j.tcr.2019.100221>

Accepted 6 July 2019

Available online 15 July 2019

2352-6440/ © 2019 The Authors. Published by Elsevier Ltd. This is an open access article under the CC BY-NC-ND license (<http://creativecommons.org/licenses/by-nc-nd/4.0/>).

diagnosis is two weeks, and mortality rates range from 22% in the cutaneous to 79% in the disseminated form [3].

Case presentation

We report the case of a 78-year old patient who presented to our surgical emergency department with swelling, erythema and pain of the back of his right hand, accompanied by a progressing hematoma located between the third and fourth metacarpophalangeal joint (Fig. 1A). First signs of erythema and swelling manifested three days earlier, after a minor laceration, inflicted whilst gardening. Local incision and debridement were performed in another hospital and the patient was referred to our hospital because of progressive signs and symptoms of a local infection. The patient was previously diagnosed with a therapy-resistant acute myeloid leukaemia (AML) (46, XY, del(20)(q11.2)(18)/46, XY(3)) for which he received platelet and erythrocyte concentrates on a weekly basis. AML was diagnosed ten months earlier as a transformation from a known myelodysplastic syndrome.

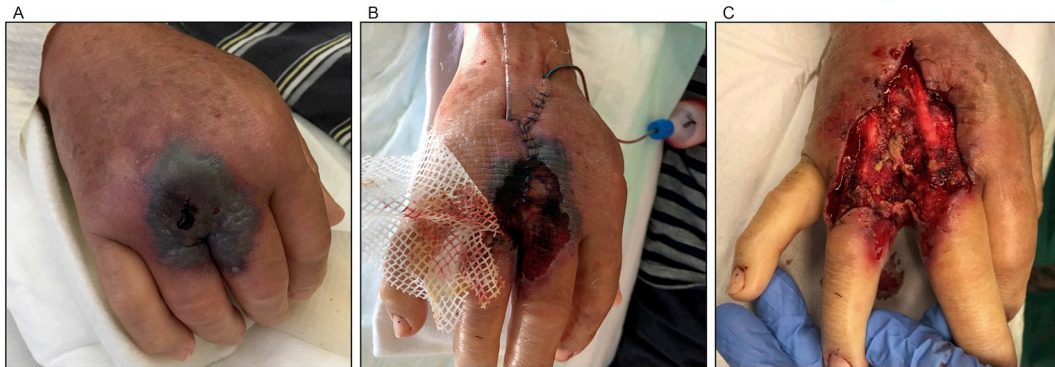


Fig. 1. PAD zero, initial clinical presentation in emergency department (A). PAD one, first surgery, postoperative finding (B). PAD four, first revision surgery, intraoperative finding prior to debridement (C).

Upon admission, the patient's C-reactive protein (CrP) level was increased at 41.6 mg/l [< 5 mg/l], his leukocyte count was 3.47/nl [normal range, 3.90–10.50/nl] and his thrombocyte count was 17/nl [normal range, 150–300/nl]. After wound inspection, sterile wound dressings were applied, the patient's forearm and hand were immobilized in a cast, and treatment with intravenous ampicillin and sulbactam was initiated. At this time no indication for surgery was given, as clinical findings were consistent with a localized superficial infection. Within the next 12 h however, clinical symptoms worsened, and the antibiotic strategy was changed to piperacillin-tazobactam combined with clindamycin. Under the assumption of a progressive phlegmon of the hand at post-admission day (PAD) one, the patient underwent surgery. A thorough debridement and wound irrigation, via a dorsal incision, were performed. At the same time multiple samples for microbiological and histological analyses were harvested. Primary wound closure with two drains was achieved (Fig. 1B).

On PAD three, local swelling and infectious parameters increased (CrP of 159.6 mg/l, leukocyte count of 4.78/nl), and revision surgery was performed on PAD four (Fig. 1C). One day later, microbiological results from the first surgery revealed an infection with *Rhizopus species* (spp.) and thus the diagnosis of a cutaneous mucormycosis was confirmed. Intravenous amphotericin B treatment was initiated immediately and further debridements were planned. In addition, growth of *Staphylococcus epidermidis* was observed in the same samples and clindamycin was stopped. Histopathologic analysis followed and showed proof of angioinvasive mucormycosis (Fig. 4). On PAD six, a second revision surgery was performed due to progressing local skin necrosis (Fig. 2A). A computed tomography scan of the thorax and abdomen on PAD seven, revealed suspicious lymph nodes of the mediastinum, but acquired biopsies showed no signs of a pulmonary fungal infection. The following day (PAD eight), the patient received a third revision operation (Fig. 2B) with the application of vacuum-assisted negative-pressure wound closure technique (Fig. 2C). Intraoperatively collected tissue samples showed remaining fungal hyphae and *Staphylococcus epidermidis* in three specimens and intravenous vancomycin was added. All tissue samples harvested from subsequent revision surgeries (PAD 10, 14, 17 and 21) did not show any further fungal or bacterial growth.

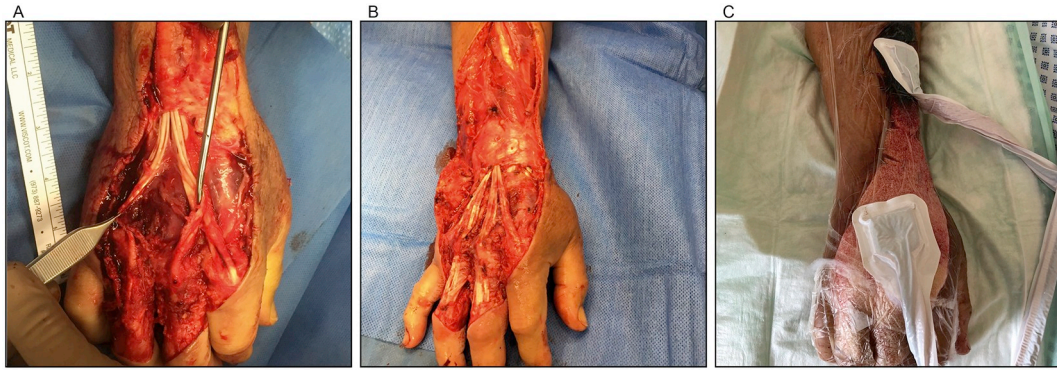


Fig. 2. PAD six, second revision surgery, intraoperative finding during debridement (A). PAD eight, third revision surgery, intraoperative finding prior to debridement and application of a vacuum-assisted negative-pressure wound closure technique (B). PAD eight, third revision surgery, postoperative finding after application of vacuum-assisted negative-pressure wound closure technique (C).

Granulation tissue formation was observed from PAD 10 onwards, following further elective revision surgery (Fig. 3A). On PAD 11 the patient's respiratory function decreased rapidly, and extensive bilateral pleural effusions were observed on chest x-rays. The patient was transferred to the intensive care unit and two thorax-drains were placed for therapeutic thoracentesis, upon which the patient's respiratory function improved. However, his general condition worsened notably over the following days, despite the fact that further revision surgeries revealed clean and vital wound conditions on PAD 14 (Fig. 3B), 17 and 21 (Fig. 3C).

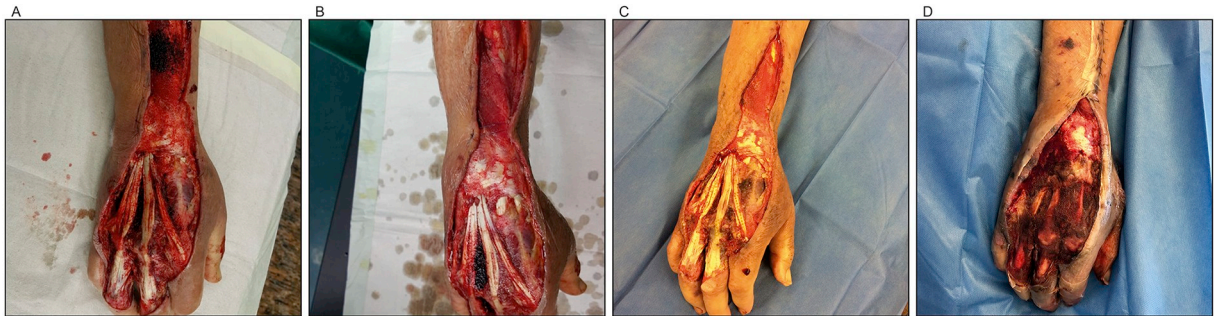


Fig. 3. PAD 10, fourth revision surgery, preoperative finding with beginning granulation tissue formation (A). PAD 14, fifth revision surgery, preoperative finding (B). PAD 21, seventh revision surgery, preoperative finding (C). PAD 31, five days after removal of extensor tendons on PAD 25 (D).

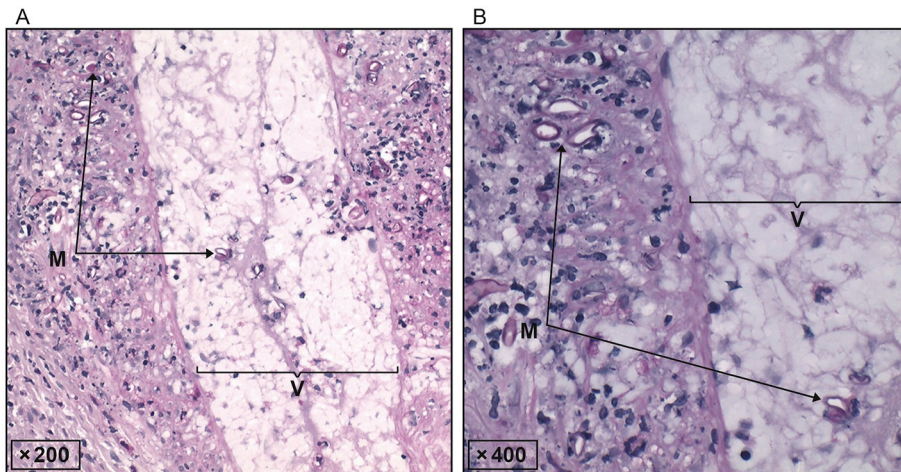


Fig. 4. Periodic acid-Schiff stained sections showing angioinvasive growth of *Rhizopus* spp. at a magnification of 200 (A) and 400 (B). M: mucormycosis, V: blood vessel.

At this stage, the patient and his relatives decided to decline further curative surgeries due to the underlying comorbidity and his general condition. In accordance with the patient's will, we removed the exposed extensor-tendons of the hand on PAD 25 as a palliative approach, allowing further soft-tissue granulation without further surgery. Fig. 3D shows a postoperative picture on PAD 31, six days after removal of the extensor tendons. At this point, the patient's general condition worsened further, and signs of pulmonary exhaustion and delirium were evident. On PAD 33 the patient died in the presence of his relatives due to his underlying condition.

Discussion and conclusions

Cutaneous mucormycosis of the hand is rarely reported and amputation of the hand and death are common complications of this fulminant fungal infection [4–6]. The fungal infection is caused by members of the *Mucorales* order, which consists of mostly saprotrophic organisms [1]. Cutaneous mucormycosis manifests predominantly in immunocompromised patients following minor trauma due to direct spore inoculation of exposed wounds. Risk factors include hematologic disorders, diabetes mellitus, glucocorticoid therapy, intravenous drug abuse, renal failure and neutropenia [5]. Yet, infections with *Rhizopus* spp. of the hand and foot have also been reported in immunocompetent patients [5,7]. The described case herein demonstrates a progressive cutaneous manifestation of *Rhizopus* mucormycosis after a minor laceration sustained whilst gardening, in a highly immunocompromised patient with a therapy-resistant AML.

The time between first local symptoms and diagnosis of mucormycosis has been reported to be around two weeks by Lantermier et al. [3]. In our case, *Rhizopus* mucormycosis was diagnosed nine days after the patient's first symptoms occurred. *Rhizopus* spp. is a mold, found predominantly in soil and decaying plants, which fits well with the patient's history of gardening, before first symptoms occurred [1].

Diagnosis of cutaneous mucormycosis can be difficult as initial symptoms are often non-specific and can mimic a variety of infectious skin diseases. This underlines the utmost importance of early harvesting of soft-tissue probes from the lesion site in cases of progressive signs of infection. Following the guidelines [8], intravenous administration of liposomal amphotericin B and radical surgical debridement were started immediately upon the diagnosis of suspected mucormycosis. Surgical care included the application of a vacuum-assisted negative-pressure wound closure technique to cover the soft-tissue defect and to enhance soft-tissue granulation. This therapy has successfully been used previously to obtain a clean wound with granulating tissue in cutaneous mucormycosis [9]. Fungal hyphae were found until PAD 8 in the intraoperatively collected tissue samples. However, all further biopsies revealed sterile specimen, indicating successful treatment.

Bearing the patient's underlying condition and the stress of repetitive surgeries in mind, his decision to decline any further surgical interventions was accepted, and a palliative solution was chosen together with the patient and his relatives. As further operations, including a potential skin graft transfer or partial amputation, were abandoned, resection of the extensor tendons of the hand and open wound care were agreed to. Tendons represent a bradytrophic, poorly vascularized tissue with little healing quality due to avascular superficial zones, which are mainly nourished by diffusion [10]. In order to implement a feasible open wound care concept, removal of tendons was inevitable and agreed to by the patient.

If the patient had continued treatment and the wound had shown progressing granulation, a muscle flap transfer or skin graft transfer would have been a possible surgical solution to cover the excessive skin and soft-tissue defect. This was reported previously as a successful treatment option in a case of cutaneous mucormycosis of the forearm with extensive soft-tissue defects due to radical surgical debridement [4]. If necrosis had progressed, a full or partial amputation of the hand would have been advised, as previously described by Lidor et al. in a case report of cutaneous *Rhizopus oryzae* mucormycosis after a burn injury [11].

The aggressive course of the fungal infection presented here displays that, in spite of early diagnosis, a clear treatment algorithm is absolutely crucial to reach clinical and paraclinical improvements and to potentially achieve survival or limb salvage in patients suffering from cutaneous mucormycosis. However, in immunosuppressed patients suffering from diseases like AML or HIV infection the general condition is often poor. Manifestation of mucormycosis usually appears at a late or terminal stage of the underlying disease and a fatal course may often not be possible to abrogate, regardless of early diagnosis and successful mucormycosis treatment [12,13]. Hence, a high level of suspicion for mucormycosis infections should be maintained in immunocompromised patients with cutaneous infections of any kind. Early sample harvesting for microbiological diagnosis, radical surgical debridement and intravenous antifungal therapy are crucial for eradication of mucormycosis and patient recovery.

Funding statement

None of the authors (TM, KS, AT, SM) received any specific funding for this work.

Consent for publication

The patient and his relatives gave written and verbal consent to submission of this case report for publication. Written consent can be presented on request.

Declaration of Competing Interest

None of the authors (TM, KS, AT, SM) state any conflicts of interest.

References

- [1] K. Hoffmann, J. Pawlowska, G. Walther, M. Wrzosek, G.S. de Hoog, G.L. Benny, P.M. Kirk, K. Voigt, The family structure of the Mucorales: a synoptic revision based on comprehensive multigene-genealogies, *Persoonia* 30 (2013) 57–76.
- [2] A. Katragkou, T.J. Walsh, E. Roilides, Why is mucormycosis more difficult to cure than more common mycoses? *Clin. Microbiol. Infect. Off. Publ. Eur. Soc. Clin. Microbiol. Infect. Dis.* 20 (Suppl. 6) (2014) 74–81.
- [3] F. Lanternier, E. Dannaoui, G. Morizot, C. Elie, D. Garcia-Hermoso, M. Huerre, D. Bitar, F. Dromer, O. Lortholary, French Mycosis Study G, A global analysis of mucormycosis in France: the RetroZygo study (2005-2007), *Clin. Infect. Dis. Off. Publ. Infect. Dis. Soc. Am.* 54 (Suppl. 1) (2012) S35–S43.
- [4] N.F. Jones, E.K. Shin, S. Eo, T.E. Starzl, Successful salvage of mucormycosis infection of the forearm and osteomyelitis of the ulna, *Hand* 3 (4) (2008) 332–336.
- [5] R. Verma, V. Nair, B. Vasudevan, P. Vijendran, V. Behera, S. Neema, Rare case of primary cutaneous mucormycosis of the hand caused by *Rhizopus microsporus* in an immunocompetent patient, *Int. J. Dermatol.* 53 (1) (2014) 66–69.
- [6] Kelpin J, Fahrenkopf M, Kelley J, Eichhorn M, Martin M. Mucormycosis osteomyelitis of the hand. *J. Hand Surg.* 2018.
- [7] B.J. Gardiner, I. Simpson, M.H. Khuu, S.E. Kidd, C.H. Lo, G.A. Jenkin, An unusual ulcer: a case of cutaneous mucormycosis caused by *Rhizopus oryzae*, *Med. Mycol. Case Rep.* 7 (2015) 8–11.
- [8] A. Skiada, F. Lanternier, A.H. Groll, L. Pagano, S. Zimmerli, R. Herbrecht, O. Lortholary, G.L. Petrikkos, European Conference on Infections in L. Diagnosis and treatment of mucormycosis in patients with hematological malignancies: guidelines from the 3rd European Conference on Infections in Leukemia (ECIL 3), *Haematologica* 98 (4) (2013) 492–504.
- [9] S. Sagar, S. Kumar, A. Gupta, M. Singhal, B. Mishra, Successful management of a case of primary cutaneous mucormycosis in an immunocompetent host, *Wounds Compend. Clin. Res. Pract.* 25 (5) (2013) 136–140.
- [10] H. Tempfer, A. Traweger, Tendon vasculature in health and disease, *Front. Physiol.* 6 (2015) 330.
- [11] C. Lidor, J.A. Nunley, Images in clinical medicine. Mucormycosis of the hand and forearm, *N. Engl. J. Med.* 337 (21) (1997) 1511.
- [12] J. Moreira, F. Ridolfi, R. Almeida-Paes, A. Varon, C.C. Lamas, Cutaneous mucormycosis in advanced HIV disease, *Braz. J. Infect. Dis. Off. Publ. Braz. Soc. Infect. Dis.* 20 (6) (2016) 637–640.
- [13] G. Petrikkos, A. Skiada, H. Sambatakou, A. Toskas, G. Vaiopoulos, M. Giannopoulou, N. Katsilambros, Mucormycosis: ten-year experience at a tertiary-care center in Greece, *Eur. J. Clin. Microbiol. Infect. Dis. Off. Publ. Eur. Soc. Clin. Microbiol.* 22 (12) (2003) 753–756.