

## Case report

## Bilateral uveitis associated with concurrent administration of rifabutin and nelfinavir

Wen-Hsin Cheng<sup>a</sup>, Cheng-Hsien Chang<sup>a, b</sup>, Po-Liang Lu<sup>b, c</sup>, Hsien-Chung Lin<sup>a, d, \*</sup><sup>a</sup> Department of Ophthalmology, Kaohsiung Medical University Hospital, Kaohsiung Medical University, Kaohsiung, Taiwan<sup>b</sup> School of Medicine, Kaohsiung Medical University, Kaohsiung, Taiwan<sup>c</sup> Department of Internal Medicine, Kaohsiung Medical University Hospital, Kaohsiung, Taiwan<sup>d</sup> Department of Ophthalmology, Yuan's General Hospital, Kaohsiung, Taiwan

## ARTICLE INFO

## Article history:

Received 27 March 2014

Received in revised form

27 June 2014

Accepted 18 August 2014

Available online 7 October 2014

## Keywords:

nelfinavir

rifabutin

uveitis

## ABSTRACT

Rifabutin-associated uveitis has been recognized as a dosage-dependent side effect. Previous studies have reported that clarithromycin or fluconazole may elevate concentrations of rifabutin through inhibition of metabolism through the cytochrome P-450 pathway. Nelfinavir is a protease inhibitor widely used in the treatment of human immunodeficiency virus (HIV) infection. The interactions between protease inhibitors and rifabutin have not been reported in clinical practice. Therefore, we present a case of bilateral uveitis associated with coadministration of rifabutin and nelfinavir. Uveitis did not subside until discontinuation of rifabutin. To our knowledge, this is the first report of uveitis with concurrent administration of rifabutin and nelfinavir. Our finding reminds us that rifabutin dosage should be reduced when it is administered with protease inhibitors.

Copyright © 2014, The Ophthalmologic Society of Taiwan. Published by Elsevier Taiwan LLC. All rights reserved.

## 1. Introduction

Rifabutin-associated uveitis has been reported in both immunosuppressed and immunocompetent individuals, and is recognized as a dosage-dependent side effect.<sup>1,2</sup> Previous reports have mentioned that concurrent administration of rifabutin and clarithromycin or fluconazole will increase concentrations of rifabutin through inhibition of the cytochrome P-450 (CYP450) system, and an accompanying increase in the incidence of rifabutin toxicities, including uveitis. Here, we report a case of uveitis associated with coadministration of rifabutin and nelfinavir. Neither clarithromycin nor fluconazole was given during this period.

## 2. Case report

A 40-year-old human immunodeficiency virus (HIV)-infected man who received lamivudine/zidovudine coformulation and nelfinavir (1250 mg twice daily) regularly, suffered from eye pain and

blurred vision in his left eye 93 days after receiving rifabutin (300 mg/day), methanzide (500 mg/day), pyrazinamide (1500 mg/day), and ethambutol (800 mg/day) for pulmonary tuberculosis. He visited the municipal hospital, and left-eye panuveitis was noted. According to the patient's statement, anterior chamber inflammation improved after administration of topical steroids (0.1% dexamethasone Q3H) and cycloplegics (1% atropine TID) without discontinuation of the antituberculosis drug. However, uveitis in the left eye deteriorated while tapering topical steroids. Right-eye panuveitis occurred after rifabutin was given for 111 days. The patient was transferred to our hospital for further management.

Fibrin and hypopyon in the anterior chamber, and vitreous haze were revealed in the ocular examination (Figs. 1 and 2). Rifabutin-associated uveitis was suspected on the basis of the course of disease and clinical presentation. Following discontinuation of rifabutin with administration of topical steroids and cycloplegics, bilateral uveitis resolved (Fig. 3). His visual acuity also recovered from hand motion to 20/20.

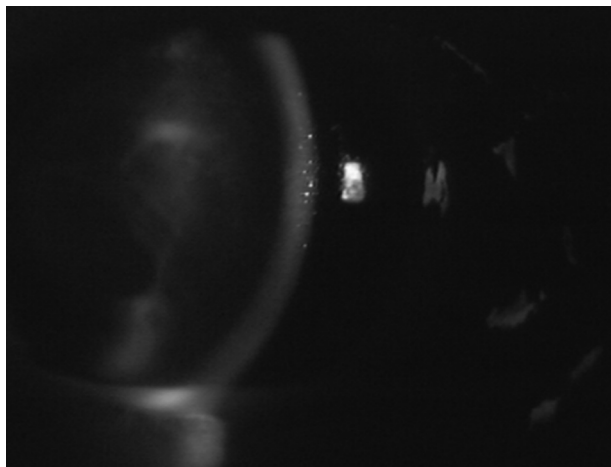
## 3. Discussion

In HIV-positive patients, many conditions may be associated with uveitis, including neoplasms, opportunistic infection, inflammation due to HIV infection itself, and drug toxicities.<sup>3</sup> Our case was negative for HLA-B27 and syphilis. Intraocular inflammation


Conflicts of interest: The authors declare no financial or nonfinancial conflicts of interest.

\* Corresponding author. Department of Ophthalmology, Kaohsiung Medical University Hospital, Kaohsiung Medical University, Number 100, Tzyou 1st Road, Sanmin District, Kaohsiung 807, Taiwan.

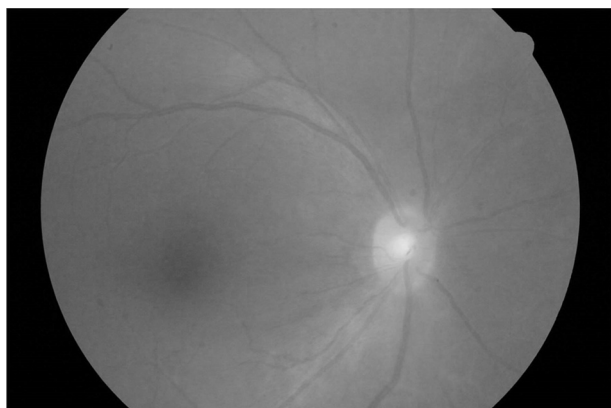
E-mail address: [m890070@gmail.com](mailto:m890070@gmail.com) (H.-C. Lin).



**Fig. 1.** Slit-lamp photograph showing severe cell reaction, fibrin, and a hypopyon in the anterior chamber.



**Fig. 2.** Fundus photograph showing vitreous haze in the right eye of the patient after receiving rifabutin for 111 days.



**Fig. 3.** Fundus photograph showing that the vitreous became clearer 4 days after discontinuation of rifabutin.

improved significantly after discontinuing rifabutin, without recurrence.

Previous studies reported that rifabutin-associated uveitis may develop after 2 weeks to 9 months of treatment.<sup>4</sup> The most frequent type is unilateral anterior uveitis with concomitant mild vitritis, but bilateral cases, intermediate uveitis, panuveitis, or even dense vitritis mimicking infectious endophthalmitis or panophthalmitis have also been reported.<sup>4–6</sup> However, it often resolved within 1–2 months after drug discontinuation and the use of intensive topical corticosteroids and cycloplegics.<sup>4,7,8</sup>

Rifabutin-associated uveitis has been identified as a dosage-dependent side effect, and adverse effects are uncommon at the recommended dose of 300 mg/day.<sup>9</sup> Our patient did not receive clarithromycin or fluconazole, which might raise the serum concentration of rifabutin through inhibition of the CYP450 system.<sup>10</sup>

The interactions between protease inhibitors (PIs) and rifabutin have been documented recently. PIs are metabolized by the CYP450 system. Coadministration of PIs and rifabutin will reduce the clearance of rifabutin<sup>11</sup> and increase the incidence of rifabutin toxicities, including uveitis.<sup>12</sup> Nelfinavir, a PI, is metabolized by multiple CYP enzymes, including CYP3A and CYP2C19. Coadministration of rifabutin with nelfinavir may increase the area under the concentration–time curve of rifabutin to 207%, compared with administration of rifabutin alone.<sup>13</sup> Therefore, dosage reduction of rifabutin to one-half the usual dose is recommended when administered with nelfinavir, whose preferred dose is 1250 mg BID.<sup>13</sup>

To our knowledge, this is the first report of uveitis with concurrent administration of rifabutin and nelfinavir when the rifabutin dosage was not reduced according to recommendations.<sup>13</sup> This finding indicates that rifabutin dosage should be reduced when it is administered with nelfinavir. In this type of uveitis condition, in addition to topical steroid use, rifabutin discontinuation is needed.

## References

1. Saran BR, Maquire AM, Nichols C, Frank I, Hertle RW, Brucker AJ, et al. Hypopyon uveitis in patients with acquired immunodeficiency syndrome treated for systemic *Mycobacterium avium* complex infection with rifabutin. *Arch Ophthalmol.* 1994;112:1159–1165.
2. Bhagat N, Read RW, Rao NA, Smith RE, Chong LP. Rifabutin-associated hypopyon uveitis in human immunodeficiency virus-negative immunocompetent individuals. *Ophthalmology.* 2001;108:750–752.
3. Cunningham Jr ET. Uveitis in HIV positive patients. *Br J Ophthalmol.* 2000;84:233–235.
4. Foster CS, Vitale AT. *Diagnosis and Treatment of Uveitis*. 2nd ed. New Delhi, India: Jaypee-Highlights; 2013.
5. Smith WM, Reddy MG, Hutcheson KA, Bishop RJ, Sen HN. Rifabutin-associated hypopyon uveitis and retinal vasculitis with a history of acute myeloid leukemia. *J Ophthalmic Inflamm Infect.* 2012;2:149–152.
6. Moorthy RS, London NJ, Garg SJ, Cunningham Jr ET. Drug-induced uveitis. *Curr Opin Ophthalmol.* 2013;24:589–597.
7. Rifai A, Peyman GA, Daun M, Wafapoor H. Rifabutin-associated uveitis during prophylaxis for *Mycobacterium avium* complex infection. *Arch Ophthalmol.* 1995;113:707.
8. Chaknis MJ, Brooks SE, Mitchell KT, Marcus DM. Inflammatory opacities of the vitreous in rifabutin-associated uveitis. *Am J Ophthalmol.* 1996;122:580–582.
9. Skinner MH, Blaschke TF. Clinical pharmacokinetics of rifabutin. *Clin Pharmacokinet.* 1995;28:115–125.
10. Kuper JL, D'Aprile M. Drug–drug interactions of clinical significance in the treatment of patients with *Mycobacterium avium* complex disease. *Clin Pharmacokinet.* 2000;39:203–214.
11. Kwara A, Flanagan TP, Carter EJ. Highly active antiretroviral therapy (HAART) in adults with tuberculosis: current status. *Int J Tuberc Lung Dis.* 2005;9:248–257.
12. Lin HC, Lu PL, Chang CH. Uveitis associated with concurrent administration of rifabutin and lopinavir/ritonavir (Kaletra). *Eye.* 2007;21:1540–1541.
13. Perry CM, Frampton JE, McCormack PL, Siddiqui MA, Cvetković RS. Nelfinavir: a review of its use in the management of HIV infection. *Drugs.* 2005;65:2209–2244.