



Contents lists available at ScienceDirect

JPRAS Open

journal homepage: [www.elsevier.com/locate/jpra](http://www.elsevier.com/locate/jpra)



## Case Report

# The “Ghost shaped” antero-lateral thigh flap for total tongue reconstruction: A case report

Fabrizio Schonauer, Vittoria Murone, Ludovica De Gregorio, Annachiara Cavaliere\*

Unit of Plastic Surgery, University “Federico II”, Via Sergio Pansini, 5 80131, Naples, Italy

## ARTICLE INFO

### Article history:

Received 15 April 2024

Accepted 14 July 2024

Available online 30 July 2024

### Keywords:

Anterolateral thigh perforator flap

Tongue cancer

Oral function

Reshape of tongue

## ABSTRACT

Squamous cell carcinoma is the most common cancer of the oral cavity, particularly of the tongue. Surgery is the treatment of choice, but it can have a dramatic impact on patients' quality of life. Although the primary goal of tongue reconstruction is the restoration of vital functions such as swallowing and speech, a good cosmetic result should also be achieved. Herein we present the case of a 54-year-old woman who underwent total glossectomy, describing and highlighting the advantages of our modified technique: the “Ghost-shaped” anterolateral thigh perforator flap.

© 2024 The Author(s). Published by Elsevier Ltd on behalf of British Association of Plastic, Reconstructive and Aesthetic Surgeons.

This is an open access article under the CC BY-NC-ND license (<http://creativecommons.org/licenses/by-nc-nd/4.0/>)

## Background

Squamous cell carcinoma (SCC) is the most diagnosed histological type among oral cavity malignancies, accounting for over 90 % of all tumors. Most frequently, the SCC involves the mobile tongue.<sup>1</sup>

Tongue defects are usually complex, as they may involve mucosa, muscle, and both sensory and motor innervation. Reconstruction of a functional tongue is mandatory to preserve deglutition, oral continence and speech capability.<sup>2</sup>

\* Corresponding author.

E-mail address: [annachiaracavaliere@yahoo.it](mailto:annachiaracavaliere@yahoo.it) (A. Cavaliere).

Surgical repair of glossectomy defects may entail different techniques, from simple direct closure to complex three-dimensional microvascular flap transfer. Whenever a microvascular flap reconstruction is planned, flap design is a key point for preserving tongue mobility and thickness, while lining gingival defects.<sup>3</sup>

In patients with defects of the mobile half of the tongue, the forearm free flap may provide a good reconstruction. Nevertheless, in patients presenting total tongue defects, this option will not provide an adequate reconstruction, leading to unsatisfactory results. In these patients, as a greater amount of tissue is needed, more thicker flaps should be used.<sup>2</sup>

Here we present our experience with a total tongue defect reconstruction using a modified antero-lateral thigh flap (ALT) design.

## Case presentation

A 54-year-old female patient was diagnosed with T3 squamous cell carcinoma of the tongue. Pre-operative evaluation included total body Computer Tomography and neck ultrasound.

Total glossectomy, via COMMANDO procedure, (COMBined MAndibulectomy and Neck Dissection Operation) with *en-bloc* dissection of the cervical nodes, was performed. Reconstruction with an ALT flap was programmed. Written informed consent for data and photo publication was obtained by the patient. This case report was prepared following the CARE Guidelines.<sup>4</sup>

### Flap design

Perforator vessels, arising from the descending branch of the lateral circumflex femoral artery, were identified using a handheld Doppler with an 8 MHz probe. The “Ghost-shaped” flap was outlined according to the perforator position. The body of the ghost was designed to reconstruct the dorsum of the *neo-tongue*, the two arms of the ghost figure were planned to recreate the ventral aspect of the *neo-tongue* and the mouth floor, respectively. The ghost tail was designed to reconstruct the anterior wall of the pharynx. Flap width and length were, respectively, 11 cm and 15 cm, according to the entity of tongue resection (Figure 1). Finally, the “Ghost-shaped” flap was inscribed in a vertical ellipse of approximately 22 × 11 cm to facilitate donor site closure (Figure 2).

### Surgical technique

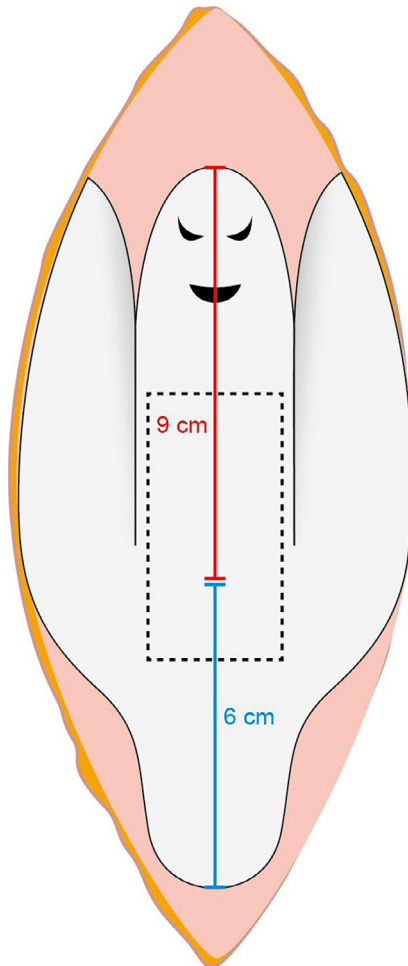
Flap dissection proceeded as for the classic ALT flap. A small vastus lateralis muscle portion was harvested with the flap to ensure a sufficient *neo-tongue* volume. The *neo-tongue* was assembled at the thigh site, with the vascular pedicle still attached to the source vessels. A gentle thinning of the flap was carried out to adjust its shape. The flap was then transferred to the oral cavity defect and sutured into place before performing the anastomosis. The left lateral circumflex femoral artery was anastomosed to the left lingual artery while the left lateral circumflex femoral vein was anastomosed to the left thyro-lingual-facial trunk (Figure 3). A sensitive branch from the lateral femoral cutaneous nerve was included in the flap and anastomosed to the glossopharyngeal nerve. The donor site defect was closed partially with direct closure and partially with a skin graft.

### Outcome evaluation

Surgical outcome was assessed after 12 months (Figure 4). Proprioceptive sensitivity was assessed through the Semmes-Weinstein monofilament test. Protopathic sensitivity was assessed with the “Hot-cold sensation” Test using tubes filled with hot (50 °C) or cold (4 °C) water.<sup>5</sup> Speech intelligibility, swallowing efficiency and Cosmetic results were assessed through three adapted and independent 4-point Likert scales.<sup>6</sup>

Speech intelligibility was assessed by a speech pathologist and could be rated as 1. tracheostomy required, 2. unintelligible speech, 3. acceptable intelligible speech, and 4. normal intelligible speech.

Swallowing efficiency was assessed by a physician with expertise in deglutition disorders and could be rated as 1. dysphagia, 2. moderate impairment, 3. mild impairment, and 4. normal.



**Figure 1.** Schematic representation of the "Ghost shaped" ALT flap.

Cosmetic result was assessed by a plastic surgeon working in a different institution from the operating surgeon.

## Results

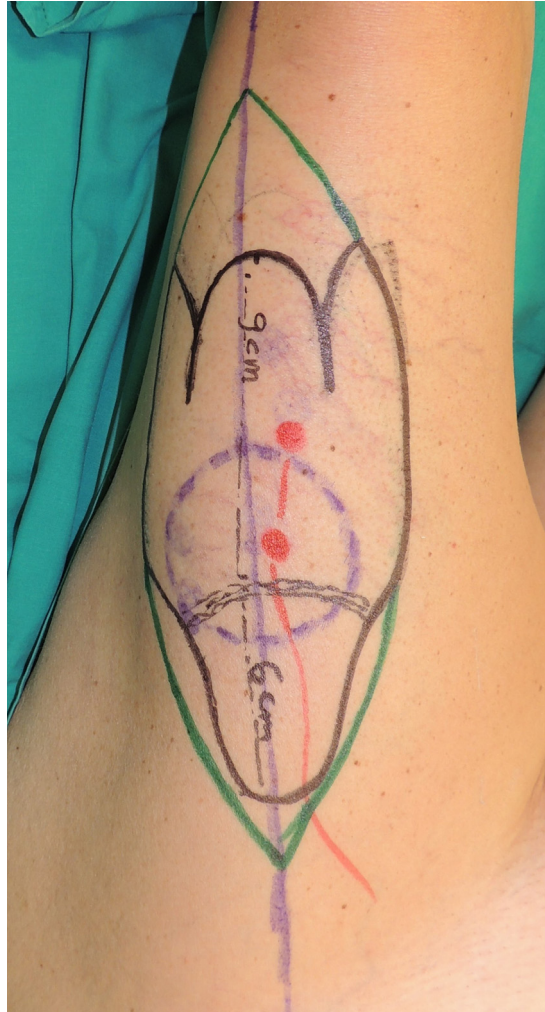
The postoperative course was uneventful and the donor site healed without complications. Satisfactory tongue shape and volume were achieved, enabling favorable dental and palatal contact.

After 12 months, patient's speech quality was rated as 3 (acceptable intelligible speech) and deglutition was rated as 4 (normal). Cosmetic result was rated as 4 (excellent).

Patient's epicritic, proprioceptive, and protopathic sensitivity were almost completely recovered after 12 months. The patient was perfectly able to return to a solid food diet.

## Discussion

Tongue reconstruction after total glossectomy represents a challenge in head and neck surgery. The ideal *neo-tongue* should reproduce the original tongue's protuberance and bulk with good mobility



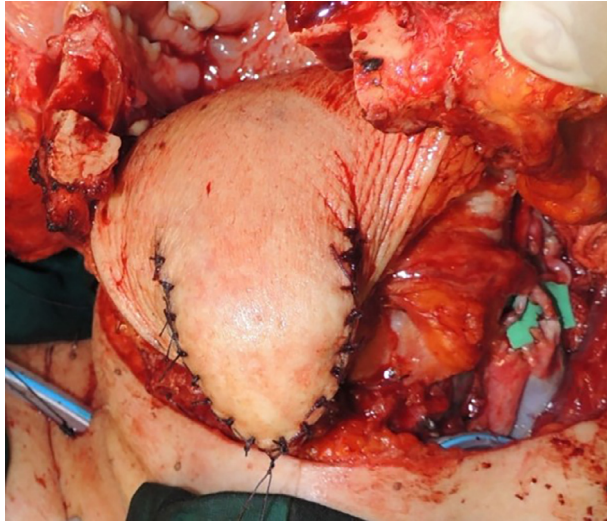
**Figure 2.** : preoperative surgical markings of the “Ghost shaped” ALT: flap width and length were, respectively, 11 cm and 15 cm. the “Ghost shaped” flap was inscribed in a vertical ellipse of approximately 22 × 11 cm to facilitate donor site closure.

and an aesthetically pleasing result. Bearing these concepts in mind, an optimal tongue reconstruction should be planned considering a three-dimensional configuration for flap design and molding.

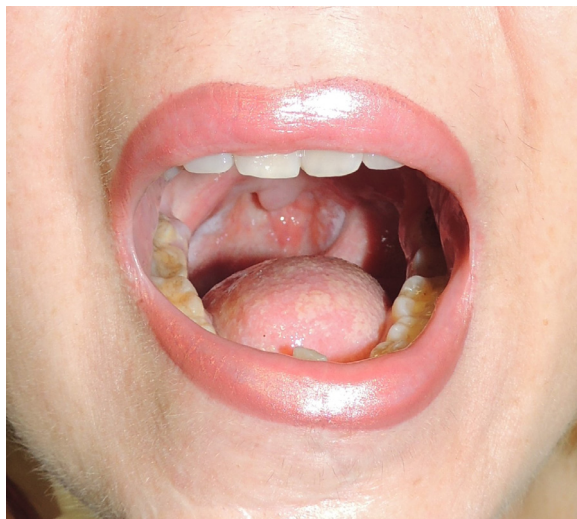In the last decade, as perforator flaps have become more popular, the ALT flap has been considered a workhorse flap for tongue reconstruction. This flap has high versatility, reliable vascularization, is easy to harvest, and has low donor-site morbidity.<sup>7</sup>

Nevertheless, for a successful reconstruction, the ALT design should be modified and adapted to be folded to recreate a tridimensional structure resembling a native tongue with appropriate volume, shape, and protrusion.

Longo et al. proposed a modified ALT flap design known as the “Mushroom-shaped flap” for subtotal tongue reconstruction. In this design, a trapezoidal paddle, resembling the stem of a mushroom, was used to reconstruct the mouth floor, while a dome-shaped paddle, representing the mushroom cap, was folded and used to reconstruct the mobile tongue.<sup>8</sup>



**Figure 3.** The reconstructed neo-tongue was inset in place and the vascular anastomoses were visible above the green background.



**Figure 4.** Patient's postoperative condition and aspect of the reconstructed neo-tongue.

Selber et al. presented the “Manta Ray” ALT flap to reconstruct the entire tongue, the mouth floor, and the anterior pharynx. Resembling a manta fish silhouette, the body of the manta was used for the neo-tongue, the two wings were used for the mouth floor, and the tail for the anterior oropharynx wall.<sup>9</sup> However, suturing the two wings together on the midline could result in a certain degree of restriction of the *neo-tongue*, thus affecting its movement.

Leymarie et al. described the “Cathedral Triptych” ALT flap design, where the central part of the flap recreated the dorsal side of the mobile tongue, and the two lateral panels the ventral side. The domes of the cathedral were sutured together to form the tongue’s tip, and two additional lateral skin sleeves recreated the mouth floor.<sup>10</sup> Nevertheless, this design is complex and wide, thus resulting in difficult donor site closure.

Our design incorporated elements from the “Manta Ray” and the “Cathedral Triptych” patterns. In our “Ghost shaped” flap the two arms of the ghost resembled the wings of the “Manta Ray” but were oriented upwards like the two lateral panels of the “Cathedral Triptych”. In this way, enough tissue was provided to ensure adequate mobility of the *neo-tongue* and for mouth floor reconstruction.

## Conclusions

The “Ghost-shaped” ALT flap has proven to be a good alternative for total tongue reconstruction. It was based on an intuitive design easy to mold and provided enough tissue to recreate a *neo-tongue* with adequate volume.

## Declaration of competing interest

The authors declare that they have no conflicts of interest to disclose.

## Acknowledgements

This paper has been English language edited by Juliet Ippolito, B.A., MPhil.

## Compliance with Ethical Standards

Ethical approval was not required.

## Informed consent

Written informed consent for photo publication was obtained by the patient.

## Funding Source

This research did not receive any specific grant from funding agencies in the public, commercial, or not-for-profit sectors.

## References

1. da Silva Souto AC, Vieira Heimlich F, Lima de Oliveira L, et al. Epidemiology of tongue squamous cell carcinoma: a retrospective cohort study. *Oral Dis.* 2023;29(2):402–410 Epub 2021 May 19. PMID: 33964106. doi:[10.1111/odi.13897](https://doi.org/10.1111/odi.13897).
2. Engel H, Huang JJ, Lin CY, et al. A strategic approach for tongue reconstruction to achieve predictable and improved functional and aesthetic outcomes. *Plast Reconstr Surg.* 2010;126(6):1967–1977 PMID: 21124135. doi:[10.1097/PRS.0b013e3181f44742](https://doi.org/10.1097/PRS.0b013e3181f44742).
3. Longo B, Ferri G, Fiorillo A, Rubino C, Santanelli F. Bilobed perforator free flaps for combined hemitongue and floor-of-the-mouth defects. *J Plast Reconstr Aesthet Surg.* 2013;66(11):1464–1469 Epub 2013 Jul 21. PMID: 23880013. doi:[10.1016/j.bjps.2013.06.058](https://doi.org/10.1016/j.bjps.2013.06.058).
4. Gagnier JJ, Kienle G, Altman D.G., et al. The CARE guidelines: consensus-based clinical case reporting guideline development. *Glob Adv Health Med.* 2013 ;2(5):38–43. doi: [10.7453/gahmj.2013.008](https://doi.org/10.7453/gahmj.2013.008). PMID: 24416692; PMCID: PMC3833570.
5. Boliek CA, Rieger JM, Li SY, Mohamed Z, Kickham J, Amundsen K. Establishing a reliable protocol to measure tongue sensation. *J Oral Rehabil.* 2007;34(6):433–441 PMID: 17518978. doi:[10.1111/j.1365-2842.2007.01735.x](https://doi.org/10.1111/j.1365-2842.2007.01735.x).
6. Hsiao HT, Leu YS, Lin CC. Primary closure versus radial forearm flap reconstruction after hemiglossectomy: functional assessment of swallowing and speech. *Ann Plast Surg.* 2002;49(6):612–616 PMID: 12461444. doi:[10.1097/00000637-200212000-00010](https://doi.org/10.1097/00000637-200212000-00010).
7. Chana JS, Wei FC. A review of the advantages of the anterolateral thigh flap in head and neck reconstruction. *Br J Plast Surg.* 2004;57(7):603–609 PMID: 15380693. doi:[10.1016/j.bjps.2004.05.032](https://doi.org/10.1016/j.bjps.2004.05.032).
8. Longo B, Pagnoni M, Ferri G, Morello R, Santanelli F. The mushroom-shaped anterolateral thigh perforator flap for subtotal tongue reconstruction. *Plast Reconstr Surg.* 2013;132(3):656–665 PMID: 23985639. doi:[10.1097/PRS.0b013e31829acf84](https://doi.org/10.1097/PRS.0b013e31829acf84).
9. Selber JC, Robinson J. The manta ray flap: a technique for total glossectomy reconstruction. *Plast Reconstr Surg.* 2014;134(2):341e–344e PMID: 25068368. doi:[10.1097/PRS.0000000000000315](https://doi.org/10.1097/PRS.0000000000000315).
10. Leymarie N, Karsenti G, Sarfati B, Rimareix F, Kolb F. Modification of flap design for total mobile tongue reconstruction using a sensitive antero-lateral thigh flap. *J Plast Reconstr Aesthet Surg.* 2012;65(7) e169–74 Epub 2011 Dec 3. PMID: 22137977. doi:[10.1016/j.bjps.2011.11.012](https://doi.org/10.1016/j.bjps.2011.11.012).