



Contents lists available at ScienceDirect

International Journal of Surgery Case Reports

journal homepage: www.casereports.com

Eagle's syndrome—A non-perceived differential diagnosis of temporomandibular disorder



P. Thoenissen*, G. Bittermann, R. Schmelzeisen, T. Oshima, T. Fretwurst

Department of Oral and Craniomaxillofacial Surgery, University Medical Center Freiburg, Hugstetter Straße 55, D-79106 Freiburg, Germany

ARTICLE INFO

Article history:

Received 14 July 2015

Received in revised form 19 August 2015

Accepted 21 August 2015

Available online 28 August 2015

Keywords:

Eagle's Syndrome

TMD

Head and neck pain

Diagnostic imaging

Surgery

ABSTRACT

INTRODUCTION: This article unveils a case of the classic styloid syndrome and states that panoramic imaging and ultrasound can be an alternative to computed tomography. In addition, the endoscope-assisted extraoral approach using CT-based navigation is useful. Eagle's Syndrome is an aggregate of symptoms described by Eagle in 1937. He described different forms: the classic styloid syndrome consisting of elongation of the styloid process which causes pain. Second, the stylo-carotid-artery syndrome which is responsible for transient ischemic attack or stroke.

PRESENTATION OF CASE: Using the example of a 66 years old male patient suffering from long term pain, we explain our diagnostic and surgical approach. After dissecting the styloid process of the right side using an extraoral approach, the pain ceased and the patient could be discharged without any recurrence of the pain up to this point.

DISCUSSION: Eagle's syndrome, with its similar symptoms, is rather difficult to differentiate from temporomandibular joint disorders (TMD), but can be easily excluded from possible differential diagnoses of TMD using panoramic radiographs and ultrasound.

CONCLUSION: Making use of low cost and easily accessible diagnostic workup techniques can reveal this particular cause for chronic pain restricting quality of life. Thereby differentiation from the TMD symptomatic complex is possible.

© 2015 The Authors. Published by Elsevier Ltd. on behalf of Surgical Associates Ltd. This is an open access article under the CC BY-NC-ND license (<http://creativecommons.org/licenses/by-nc-nd/4.0/>).

1. Introduction

Eagle's syndrome is an expression of a combination of symptoms which was first described by Watt Weems Eagle in 1937 [6]. Later, he defined two different forms: classic styloid syndrome, showing uncharacteristic pain and foreign body sensation, and secondly stylo-carotid-artery syndrome, which in some cases can be responsible for TIA/stroke [3,5,8,6]. This article concerns styloid syndrome as a cause of head and neck pain, resulting from the presence of an elongated styloid process above 25 mm as Eagle believed [3]. In an advanced study, Moffat et al. measured 80 cadaver heads and found a mean range from the skull base to the tip of the styloid of 3.27 cm. Two main theories should be contemplated when assessing the origin of elongation of the styloid process. Eagle presumed that a secondary cause of elongation was traumatic scarring and hyperplasia related to previous tonsillectomy [4]. Today, bone development and homeostasis are thought to contribute to the elongation of the styloid process, including the consideration of the

presence of two ossification centers in the styloid process, embryonic mesenchymal conversion to osteoid matrix, osteoarthritic changes, and diseases of calcium-phosphate maintenance as Fusco et al. point out [6]. Morrison et al. state that the ossification of the styloid process may be hereditary in some families and is most likely due to an autosomal dominant gene [11].

The styloid process protrudes from the bottom of the petrous bone and thereby crosses parapharyngeal anatomical structures such as the internal carotid artery, maxillary artery, internal jugular vein, glossopharyngeal nerve, vagus nerve, and branches of both the trigeminal and facial nerves to travel medial to the styloid process [6,15]. Particularly the proximity of the styloid process to the jugular foramen and carotid canal orifice is influential to the ultimate pathophysiology of Eagle's syndrome [6].

The origin of styloid process is related to three different muscles and two ligaments. The stylopharyngeus muscle raises the pharynx, the stylohyoid the hyoid, and the styloglossus the tongue. The stylohyoid ligament stabilizes the hyoid bone, and the stylomandibular the mandible by assessing the posterior part [15]. Embryologically the styloid process, stylohyoid ligament, and lesser cornu of the hyoid bone derive from endochondral ossification of Reichert's cartilage. This is the cartilaginous component of the second branchial arch and is divided into five parts [6]. Four of them, the tympan-

* Corresponding author.

E-mail address: Philipp.nikolaus.thoenissen@uniklinik-freiburg.de (P. Thoenissen).

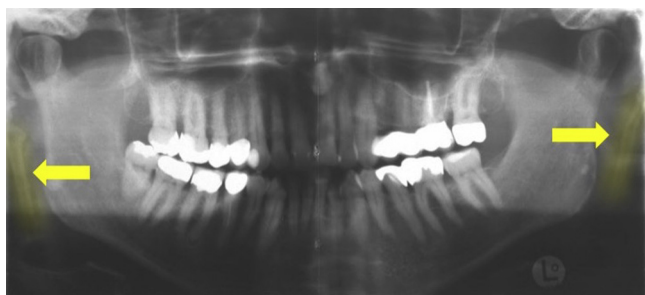


Fig. 1. Panoramic imaging of the patient: the arrows point to the bilateral calcified stylohyoid ligaments lateral to the ramus.

nohyal, the stylohyal, hypohyal, and basyhyal contribute to the styloid process and the hyoid bone [6].

The styloid process, when elongated, irritates nerves as well as blood vessels, resulting in pain in the affected area [6]. An elongated styloid process can be found in approximately 4 percent of the human population and causes symptoms in only a small subgroup [15,1]. A higher occurrence is assumed to be present in populations of African genetic heritage [10]. Women in their 4–6th decade of life are most likely to be affected and express symptoms [6]. Bone development abnormalities could be considered as a reasonable cause of elongation of the styloid process and the ossification of the stylohyoid ligament [10,6]. Diagnostic techniques include panoramic radiographs, CT, and the use of further radiographic imaging methods, such as skull posterior-anterior conventional X-ray (PA) [9]. Treatment is most often nonsurgical for selected patients, but must be carried out surgically for patients without relief. An intraoral or extraoral surgical approach is performed in these instances, often depending on the surgeon's practical experience and preferences regarding the operation type [12]. Adverse effects of surgery could cause harm to major vessels such as the carotid artery or vagal nerve. This could lead to complications in form of excessive or catastrophic bleeding during surgery and post-operative or disorders of orthostatic regulation.

This work has been reported in line with the CARE criteria. [7]

2. Presentation of case

A 66-year old male patient has been experiencing head, neck, and shoulder pain on both sides of the body for over a decade. In this time period, he was examined by several different medical specialists and experienced no relief or signs of improvement. In his case, rotation of the head was limited to 45° to the left and 35° to the right, which normally is possible in the range of 60–80°. Extension of the head up to 55° was possible while experiencing heavy pain. A calcified styloid process next to the ramus on both sides of the head was observed in a routine panoramic radiograph (Fig. 1). Surgery of the cervical spine in order to treat a disc prolapse C5/6, as well as osteopathy and strength training brought no relief. The patient described an intensification of pain after exercise activities, such as normal gym workouts and cycling. No trauma or surgical treatment and no neurological or infectious focus were found in the patient's history. The patient was being administered analgesics with daily doses of tilidine 50 mg 1-0-0 and amitriptilin 25 mg 0-0-1. The patient suffered from a symptomatic complex and ceased to participate in social activities. At the time of presentation to our department he was psychologically decompensated and saw a surgical procedure as a last chance for him to lead a normal life again. The described results of CT-imaging, as well as the type of head and neck pain present, are both characteristically indicative of Eagle's syndrome. Neither internally nor externally could masses in terms

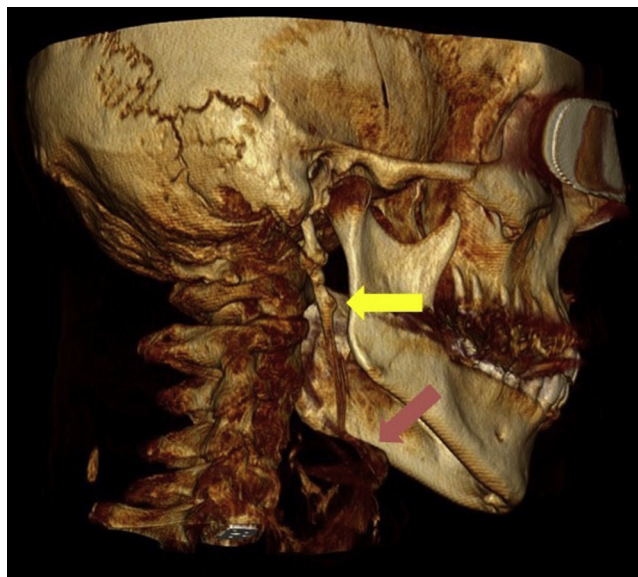


Fig. 2. CT 3D reconstruction of the elongated styloid process on the right side: the yellow arrow points out the styloid process on the right. The red arrow is directed at the hyoid bone.

of the calcified process be palpated, which frequently is possible in the oropharyngeal area [12]. The new anatomic proportions after the intervention could be responsible for the vertigo the patient experienced a few weeks after surgery.

The patient was examined using ultrasound and echoes due to the ossification of the elongated styloid processes were detected in the analysis. High resolution thin-layer CT-imaging of the head revealed an 8.8 cm long styloid process and calcified stylohyoid ligament on the left side of the head and a 6.8 cm long styloid process on the right. (Fig. 2) In order to prevent any damage to the surrounding structures, magnetic resonance imaging (MRI) and magnetic resonance angiography (MRA) were utilized to analyze and document the soft tissue, including the carotid arteries, in the area of the styloid processes. In general, treatment should be adjusted to the severity of patients symptoms [8]. Thereby, a conservative and surgical approach to treatment of an elongated styloid process is possible. Conservative management is comprised of physiotherapy, local infiltration with anesthetics in the tonsillar fossa, and treatment with anti-inflammatory drugs, anticonvulsants or antidepressants, and often fails as Prasad et al. found in their clinical trial [8,14].

The treatment of choice for this patient was a surgery to reduce the length of the stylohyoid ligament and remove the styloid process [8]. Hereby, an extraoral or intraoral approach is possible. Piezoelectric instruments were in this case preferred, as their use minimized risk of harming other structures in the immediate area [8]. This risk of harming anatomical structures in the parapharyngeal area such as the carotid artery rises when using internal assessment procedures, due to the difficulty in full visualization of the area [14].

The patient underwent operative treatment using a sub-mandibular approach. Endoscopy-assisted surgery and CT-based navigation was used to precisely identify the surrounding anatomical structures and carry out the operation. A 4 cm piece of the process was removed at the skull base. (Fig. 3) The patient reported an easing of his pain only two days after being taken off of analgesia. Rotation to left and right and extension of the head to the aforementioned normal values was also achieved. The patient's symptoms regressed and the he was discharged free of complaints.

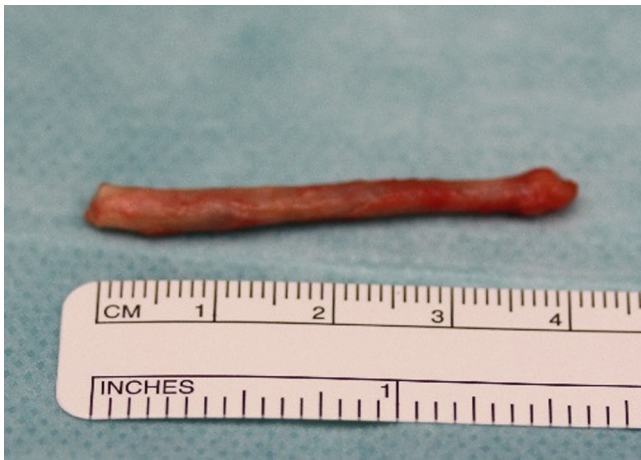

Fig. 3. Biopsied 4 cm piece of styloid process.

Two months after being discharged from our hospital, the patient again presented himself to our department with occurrence of vertigo, which improved without treatment after two days. To date, the patient feels relief, continues living a normal life, and no longer takes tilidine medication; instead he uses a low daily dose of gabapentine, which has been administered by a medical psychotherapist as prophylaxis for neuropathic pain in the head and neck area. No elevated occurrence of vertigo was noticed, and he stated two years after surgery that his quality of life has improved.

3. Discussion

Chronic pain of the head and neck is common, and the origin of this pain can vary greatly [6]. In the present case, Eagle's syndrome was diagnosed upon panoramic imaging and an analysis of reported symptoms after a routine check by a dentist. Ultrasound and CT-scanning confirmed the diagnosis and MRA was used to determine the location of blood vessels in the surrounding area.

Currently, CT can be defined as the standard method for the diagnosis of Eagle's syndrome [13,12]. Diagnostic imaging concerning the confirmation of Eagle's Syndrome can be carried out using panoramic radiographs and ultrasound. In this manner, radiation dosage can be reduced and cost-intensive diagnostic techniques can be largely avoided. In addition, using CT-navigation combined with endoscopy reduces the invasiveness and risk of a surgical operation on the styloid process. The use of an extraoral approach can further reduce the damage caused to the surrounding tissues and nerves that could occur during the operation.

When a patient is presenting long-term pain of the head and neck region, dentists and physicians should consider Eagle's syndrome as a possible cause. The aforementioned diagnostic and therapeutic methods allow physicians to correct the life-limiting conditions being experienced by a patient who is suffering from chronic pain due to an elongated styloid process. Even psychological effects, as in this case, can be seen, further degrading patients' quality of life.

Elongated styloid process is a differential diagnosis of temporomandibular joint disorder (TMD). This causes pain in the TMJ region or preauricular region, mandibular movements, joint noises and sounds, referred pain, headaches, tinnitus, earaches, vertigo or dizziness, hypoacusis, and hyperacusis [2]. In conclusion, Eagle's syndrome, with its similar symptoms, is rather difficult to differentiate from TMD. It is more likely to speak of Eagle's syndrome as a contributor to the TMD symptomatic complex.

4. Conclusion

Eagle's syndrome has a vast variety of symptoms, including pain of the head and neck region. Thereby differentiation from the TMD symptomatic complex is hardly possible. By using easily accessible panoramic imaging and ultrasound, Eagle's syndrome can be excluded from possible differential diagnoses of TMD. An external surgical approach can be the last chance to help affected people live a normal life again.

Conflicts of interest

There is no conflict of interest in this research.

Sources of funding

There is no funding source for our research.

Ethical approval

No ethical approval was needed.

Consent

Patient gave his informed consent.

Author contribution

Idea: Schmelzeisen R.

Data collection: Thoenissen P.

Writing: Thoenissen P, Bittermann G, Fretwurst T.

Images: Toshiyuki O.

Guarantor

Thoenissen P.

References

- [1] C. Becker, J. Pfeiffer, Eagle's syndrome, *Am. J. Med.* 126 (8) (2013) e3–e4, <http://dx.doi.org/10.1016/j.amjmed.2013.02.022>.
- [2] K.M. de Andrade, C.A. Rodrigues, P.C. Watanabe, M.O. Mazzetto, Styloid process elongation and calcification in subjects with tmd: clinical and radiographic aspects, *Braz. Dent. J.* 23 (4) (2012) 443–450.
- [3] W.W. Eagle, Elongated styloid process; further observations and a new syndrome, *Arch. Otolaryngol.* 47 (5) (1948) 630–640.
- [4] W.W. Eagle, Symptomatic elongated styloid process; report of two cases of styloid process–carotid artery syndrome with operation, *Arch. Otolaryngol.* 49 (5) (1949) 490–503.
- [5] W.W. Eagle, Elongated styloid process; symptoms and treatment, *AMA Arch. Otolaryngol.* 67 (2) (1958) 172–176.
- [6] D.J. Fusco, S. Asteraki, R.F. Spetzler, Eagle's syndrome: embryology, anatomy, and clinical management, *Acta Neurochir. (Wien)* 154 (7) (2012) 1119–1126, <http://dx.doi.org/10.1007/s00701-012-1385-2>.
- [7] Joel J. Gagnier, David Riley, Douglas G. Altman, David Moher, Harold Sox, Gunter S. Kienle, The CARE guidelines: consensus-based clinical case reporting guideline development, *Dtsch. Arztebl. Int.* 110 (37) (2013) 603–608, <http://dx.doi.org/10.3238/arztebl.2013.0603>.
- [8] E. Hoffmann, C. Räder, H. Fuhrmann, P. Maurer, Styloid–carotid artery syndrome treated surgically with Piezosurgery: a case report and literature review, *J. Craniomaxillofac. Surg.* 41 (2) (2013) 162–166, <http://dx.doi.org/10.1016/j.jcms.2012.07.004>.
- [9] M. Miloro, Fracture of the styloid process: a case report and review of the literature, *J. Oral Maxillofac. Surg.* 52 (10) (1994) 1073–1077.
- [10] D.A. Moffat, R.T. Ramsden, H.J. Shaw, The styloid process syndrome: aetiological factors and surgical management, *J. Laryngol. Otol.* 91 (4) (1977) 279–294.
- [11] P.J. Morrison, R.J. Morrison, C.S. McKinstry, Familial ossification of the stylohyoid ligament in a three generation family—a new clinical entity displaying autosomal dominant inheritance, *Br. J. Radiol.* (2012) 458–459, England.
- [12] T. Müderris, S. Bercin, E. Sevil, S. Beton, M. Kırs, Surgical management of elongated styloid process: intraoral or transcervical? *Eur. Arch. Otorhinolaryngol.* (2013), <http://dx.doi.org/10.1007/s00405-013-2664-0>.

- [13] D.R. Nayak, K. Pujary, M. Aggarwal, S.E. Punnoose, V.A. Chaly, Role of three-dimensional computed tomography reconstruction in the management of elongated styloid process: a preliminary study, *J. Laryngol. Otol.* 121 (4) (2007) 349–353, <http://dx.doi.org/10.1017/S0022215106003276>.
- [14] K.C. Prasad, M.P. Kamath, K.J. Reddy, K. Raju, S. Agarwal, Elongated styloid process (Eagle's syndrome): a clinical study, *J. Oral Maxillofac.Surg.* 60 (2) (2002) 171–175.
- [15] J.S. Rechtweg, M.K. Wax, Eagle's syndrome: a review, *Am. J. Otolaryngol.* 19 (5) (1998) 316–321.

Open Access

This article is published Open Access at sciedirect.com. It is distributed under the [IJSCR Supplemental terms and conditions](#), which permits unrestricted non commercial use, distribution, and reproduction in any medium, provided the original authors and source are credited.