

Spontaneous Nephrocutaneous Fistula With Tuberculous Autonephrectomy: A Case Report of a Delayed Diagnosis

Murat Akand,^{1,*} Ozcan Kilic,¹ Mustafa Kucur,¹ Mehmet Kaynar,¹ and Serdar Goktas¹

¹Department of Urology, School of Medicine, Selcuk University, Konya, Turkey

*Corresponding author: Murat Akand, Department of Urology, School of Medicine, Selcuk University, 42075 Selcuklu, Konya, Turkey. Tel: +90-5327438333, Fax: +90-3322412184, E-mail: drmuratakand@yahoo.com

Received 2014 October 08; Revised 2015 March 25; Accepted 2015 May 17.

Abstract

Introduction: Spontaneous nephrocutaneous fistula is a rare manifestation of renal disease that can occur due to various etiologies, such as renal calculus, chronic pyelonephritis, stricture of the ureteropelvic junction, and renal tuberculosis (TB). An autonephrectomy with a nephrocutaneous fistula due to renal tuberculosis can be diagnosed quite late if it is not suspected.

Case Presentation: We report a case of a spontaneous nephrocutaneous fistula with tuberculous autonephrectomy. A 40-year-old white male with recurrent flank pain and intermittent purulent drainage from his right flank region for the previous 14 years was admitted to our outpatient clinic. Fistulography and computerized tomography demonstrated a 51 × 60 mm area with a soft-tissue appearance that implied autonephrectomy of the right kidney, and a fistula tract with a 9 mm diameter between the skin and the retroperitoneal space. The patient was successfully treated with nephroureterectomy and excision of the fistulous tract, followed by antituberculous treatment. The pathological examination of the surgical specimen revealed chronic atrophic pyelonephritis, calcifications, and necrotizing granulomatous inflammation suggestive of TB.

Conclusions: Urogenital TB is difficult to diagnose due to the lack of specific symptoms and signs. In the case of a nonfunctioning kidney without an obvious cause and a chronic spontaneous nephrocutaneous fistula, the possibility of associated renal TB should be kept in mind, especially in immunocompromised patients or in places where TB is a common health problem.

Keywords: Autonephrectomy, Nephrocutaneous Fistula, Tuberculosis, Chronic Infection

1. Introduction

Spontaneous nephrocutaneous fistula is a rare manifestation of renal disease that can occur due to various etiologies. Renal calculus and chronic pyelonephritis are the most common causes (1). Genitourinary tuberculosis (TB) is seen in 15% - 20% of patients with pulmonary TB in developing countries. Spontaneous nephrocutaneous fistulas can be secondary to strictures at the ureteropelvic junction, or to necrosis and scar formation due to renal TB. Fibrosis, necrosis, and scar formation in the renal parenchyma creates a weak area, from which the leak begins (2). Renal TB can cause various complications, including autonephrectomy in 11.5% of affected patients (3).

Herein, we report a rare case of spontaneous nephrocutaneous fistula with tuberculous autonephrectomy.

2. Case Presentation

In September 2014, a 40-year-old white male who worked as a cook presented to the outpatient clinic with recurrent right flank pain and intermittent purulent drainage from his right flank region over the previous 14

years. There was no past history of any medical or surgical illness, including TB or trauma. No evidence of pulmonary or extrapulmonary TB was identified in his family history. The physical examination revealed a fistulous orifice in the skin of the right flank region. The patient had already used different kinds of antibiotics during this disease process, but the discharge from the fistula had never stopped. Laboratory evaluations identified a normal urine analysis, a sterile urine culture, and normal serum hemoglobin, urea, and creatine levels. A fistulography was performed, revealing drainage of contrast agent to the kidney and the retroperitoneal space (Figure 1). Computerized tomography (CT) demonstrated a 51 × 60 mm area with a soft-tissue appearance that indicated autonephrectomy of the right kidney, and a fistula tract with a 9 mm diameter between the skin and the retroperitoneal space (Figure 2). The right kidney was non-functioning on a Tc99m-dimercaptosuccinic acid (DMSA) renal scan. There was compensatory hypertrophy of the contralateral kidney. The patient was assessed by the department of chest diseases, and his tuberculin test was negative for TB. There was no evidence of TB on chest X-ray or CT.

Nephroureterectomy and excision of the fistulous

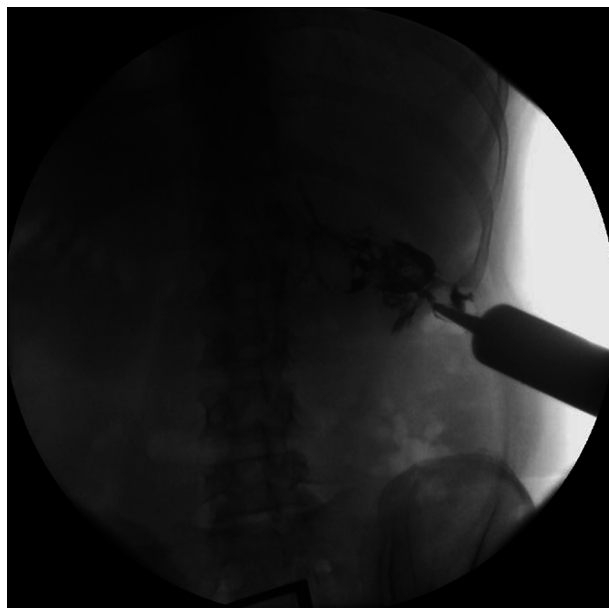


Figure 1. Fistulography Showing Drainage of Contrast Agent to the Kidney and Retroperitoneal Space

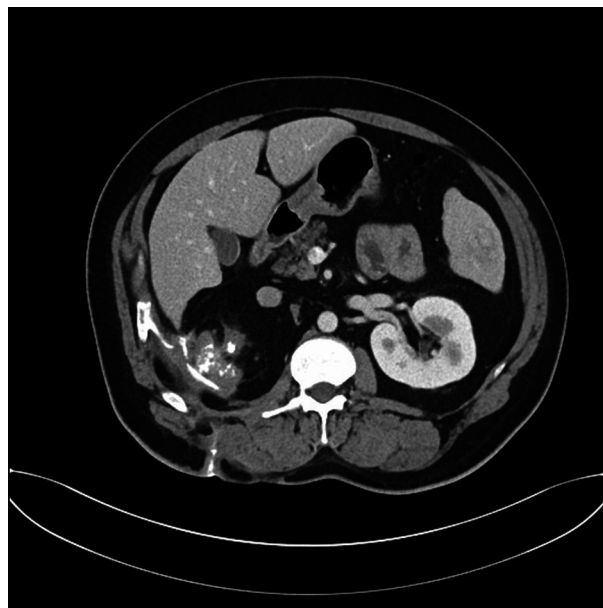


Figure 2. CT Scan Demonstrating an Area of Soft-Tissue Appearance That Implies Right Autonephrectomy, as Well as the Fistula Tract Between the Skin and Retroperitoneal Space

tract were performed through a right flank incision. Dense adhesions of the kidney to the psoas muscle and posterior peritoneum were carefully dissected. The pathological examination of the surgical specimen revealed chronic atrophic pyelonephritis, calcifications, and necrotizing granulomatous inflammation, suggestive of TB. The postoperative recovery period was uneventful and the patient was discharged on the seventh day. A Ziehl-Neelsen stain of the nephroureterectomy specimen showed acid-fast bacilli, confirming the diagnosis of renal TB. The patient was successfully treated for six months after the nephroureterectomy with a four-drug antituberculous therapy (isoniazid [300 mg/day], rifampicin [600 mg/day], pyrazinamide [2000 mg/day, 2 months only], and ethambutol [1500 mg/day, 2 months only]). At his last follow-up visit in March 2015, he had no complaints, and his abdominopelvic CT scan showed no pathological findings except for the solitary left kidney.

3. Discussion

Genitourinary TB is the second most common form of extrapulmonary TB, after peripheral lymphadenopathy. TB may involve the kidney as part of a generalized disseminated infection, or as localized genitourinary disease. However, less than 50% of patients with renal TB have radiological evidence of pulmonary TB, and active pulmonary disease is present in approximately 5% of such patients (4).

The development of disease depends on the cellular immune response of the host, which determines the outcome of the infection. The healing process results in fibrous tissue, and the deposition of calcium salts can result in a non-functioning kidney, known as tuberculous autonephrectomy. Renal calcifications may occur commonly in TB and require surgical intervention. In the treatment of this complication, the aim is to ensure the protection of the renal tissue as much as possible (5).

Tuberculous bacilli reach the kidney via a hematogenous route and settle in periglomerular capillaries, leading to abscess formation. Caseous necrotizing granulomas extend to the renal papilla and collecting systems. All of these inflammatory changes result in fibrosis, calcifications, ureteral and calyceal strictures that cause loss of renal function, and autonephrectomy (6). In this situation, nephroureterectomy is unavoidable; however, this is a debatable point if the kidney is non-functioning and symptomless. Some authors have proposed nephrectomy in order to prevent reactivation, while others have recommended life-long follow up. With the development of anti-tuberculous drugs, nephrectomy has become less important, but it can still be required in cases of uncontrolled hypertension or uncontrolled pain associated with the kidney. Additionally, at the end-stage of the disease, fistulas can form to adjacent organs, requiring surgical excision of the fistulous tract and nephroureterectomy (7). According

to the European Association of Urology Guidelines, the indications for nephrectomy include a non-functioning kidney with or without calcifications, extensive disease involving the whole kidney with hypertension and ureteropelvic junction obstruction, and coexisting renal carcinoma (5).

A spontaneous renal fistula to adjacent organs is not an uncommon condition, but a spontaneous nephrocuteaneous fistula is still rare. The majority of such fistulas present as spontaneous drainage through the lumbar region, and their etiologies include chronic renal calculi, probably the most common cause. There are some cases of spontaneous nephrocuteaneous fistula due to chronic renal TB (8, 9).

Urogenital TB is difficult to diagnose due to the lack of specific symptoms and signs. Irritative lower urinary tract symptoms, hematuria, and pyuria are the most common complaints. Abnormal radiological findings, including pyelocaliceal dilatation, ureteral stricture, hydroureter, parenchymal destruction, autonephrectomy, and calcifications, can be seen in 61.5% of patients. A definite diagnosis cannot be made with these findings, but urogenital TB should be considered in the differential diagnosis (3).

Great effort has been put into comprehensive vaccination policies throughout the world in order to eradicate TB, and although mankind has not managed eradication, the incidence has been markedly reduced. However, much scientific evidence is currently accumulating with regard to the increased incidence of multi-drug resistant, extensively drug-resistant, and totally drug-resistant TB, and the diagnosis and treatment of TB is becoming a major issue (10). Physicians should consider TB in the differential diagnosis for any chronic infection, and should do their best to treat accordingly.

In the present case, the patient had leakage from the lumbar region for more than 10 years. Although he had received various antibiotics and medical treatments over a long period, no benefit was seen. This interesting case report of a delayed diagnosis shows us that in cases of a non-functioning kidney with a spontaneous nephrocuteaneous

fistula, we must keep in mind the possibility of associated renal TB, especially in immunocompromised patients or in geographic areas where TB is a common health problem.

Footnote

Authors' Contribution: Murat Akand, Ozcan Kilic, and Serdar Goktas diagnosed the patient; Murat Akand, Mustafa Kucur, and Mehmet Kaynar treated the patient; Murat Akand and Ozcan Kilic prepared the manuscript.

References

1. Khallouk A, Tazi MF, Elfassi MJ, Farih MH. Chronic spontaneous nephrocuteaneous fistula associated with renal replacement lipomatosis. *Rev Urol.* 2010;**12**(4):e190-2. [PubMed: 21234262].
2. Maheshwari PN, Shah HN. Nephrocuteaneous fistula through percutaneous nephrolithotomy scar: rare presentation of genitourinary tuberculosis. *Urology.* 2005;**66**(3):655-6. doi: 10.1016/j.urology.2005.04.052. [PubMed: 16140098].
3. Yazdani M, Shahidi S, Shirani M. Urinary polymerase chain reaction for diagnosis of urogenital tuberculosis. *Urol J.* 2008;**5**(1):46-9. [PubMed: 18454427].
4. Lin YL, Fan YC, Cheng CY, Sue YM, Hsu YH, Hou CC, et al. The case | Sterile pyuria and an abnormal abdominal film. "Autonephrectomy" of right kidney. *Kidney Int.* 2008;**73**(1):131-3. doi: 10.1038/sj.ki.5002593. [PubMed: 18084265].
5. Cek M, Lenk S, Naber KG, Bishop MC, Johansen TE, Botto H, et al. EAU guidelines for the management of genitourinary tuberculosis. *Eur Urol.* 2005;**48**(3):353-62. doi: 10.1016/j.eururo.2005.03.008. [PubMed: 15982799].
6. Matos MJ, Bacelar MT, Pinto P, Ramos I. Genitourinary tuberculosis. *Eur J Radiol.* 2005;**55**(2):181-7. doi: 10.1016/j.ejrad.2005.04.016. [PubMed: 15950419].
7. Clifford AV, Noon AP, Raw D, Hall J. Renal calcified mass misdiagnosed as a renal calculus in an adult with tuberculosis "autonephrectomy": a case report. *Cases J.* 2009;**2**:7613. doi: 10.4076/1757-1626-2-7613. [PubMed: 19918475].
8. Qureshi MA. Spontaneous nephrocuteaneous fistula in tuberculous pyelonephritis. *J Coll Physicians Surg Pak.* 2007;**17**(6):367-8. [PubMed: 17623591].
9. Ansari MS, Singh I, Dogra PN. Spontaneous nephrocuteaneous fistula- 2 unusual case reports with review of literature. *Int Urol Nephrol.* 2004;**36**(2):239-43.
10. Shokouhi S, Darazam I. Drug-Resistant Tuberculosis and Group 5 Anti-Tuberculosis Drugs. *Arch Pediatr Infect Dis.* 2015;**3**(1 TB).