

## Case Report

# A rare case of tumor-to-tumor metastasis: breast cancer metastatic to a benign renal mass

Emilia Diego\* and Kandace P McGuire

Department of Surgery, Magee Womens Hospital of UPMC, Pittsburgh, PA, USA

\*Correspondence address. Department of Surgery, Division of Surgical Oncology, Magee-Womens Hospital of UPMC, 300 Halket Street, Suite 2601, Pittsburgh, PA 15213, USA. Tel: +1-412-641-5356; Fax: +1-412-641-1446; E-mail: diegoe@upmc.edu

Received 2 January 2013; accepted 3 February 2013

Tumor-to-tumor metastasis is a clinical entity that has been documented in medical literature as early as the 1900s. It is rare and published primarily as case reports, although its incidence seems to be on the rise as a result of improving medical care in developed countries. We report an unusual case of metastatic breast tumor to a benign renal tumor, in a patient with a remote history of breast cancer. This case reinforces in our minds the enigmatic nature of breast cancer and its wide spectrum of clinical behavior.

## INTRODUCTION

Tumor-to-tumor metastasis, although uncommon, is not as rare as once thought. Since Berent's first documentation of a case in 1902 [1], over 150 cases have been reported in literature [2].

The most commonly reported recipient tumor is a renal cell carcinoma [3] and there are several theories to support this phenomenon. Pulmonary carcinoma is noted to be the most frequent donor tumor [4] but other tumors are also known to metastasize, including breast, gastrointestinal, prostate and thyroid cancers [1].

We report an unusual case of tumor-to-tumor metastasis that involves a benign recipient tumor.

## CASE REPORT

A 67-year-old Caucasian female presented for evaluation of a right chest wall mass 19 years after a modified radical mastectomy for a Stage IIB hormone-receptor positive invasive ductal carcinoma. She received adjuvant chemotherapy and endocrine therapy and had been symptom free until presentation.

A PET-CT was performed, which demonstrated a round enhancing  $1.8 \times 1.5$  cm right subpectoral lymph node with FDG uptake and a maximum SUV of 4.0 suspicious for metastatic disease (Figs 1 and 2). Additionally, an incidental

$4.1 \times 3.4$  cm mass within the midpole of the left kidney was heterogeneously enhancing with increased FDG uptake and a maximum SUV of 8.6 suspicious for a renal cell carcinoma or less likely a transitional cell carcinoma (Figs 3 and 4).

An ultrasound guided core biopsy of the subpectoral lymph node verified metastatic carcinoma of breast origin, confirmed by positive immunostaining for mammaglobulin, e-cadherin and estrogen receptors (Fig. 5).

With the relatively small burden of metastatic breast disease, surgical management for the renal mass was deemed appropriate and she underwent a left total nephrectomy without complications.

The kidney measured  $10.5 \times 7.5 \times 5.5$  cm and was distorted by a  $6.0 \times 5.5 \times 4.0$  cm tan-brown mass with a pseudocapsule at the inferior pole (Fig. 6). Within the tan-brown mass was a centrally located  $2.0 \times 1.5$  cm white mass (Fig. 7).

The final pathology demonstrated a 2 cm metastatic mammary carcinoma within a 6 cm angiomyolipoma, confirmed by staining with melan A. All the margins were clear and the renal parenchyma was uninvolved. The metastatic focus was composed of cytologically atypical glands with intraluminal blue mucin, morphologically similar to the subpectoral lymph node biopsy. The metastatic cells also stained positive for the estrogen receptor, mammaglobulin and GCDPF-15, confirming the tumor to be of breast origin (Fig. 8).

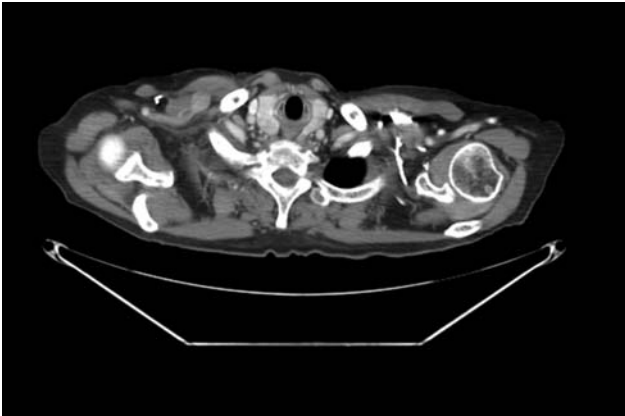


Figure 1: CT scan with the right subpectoral lymph node.

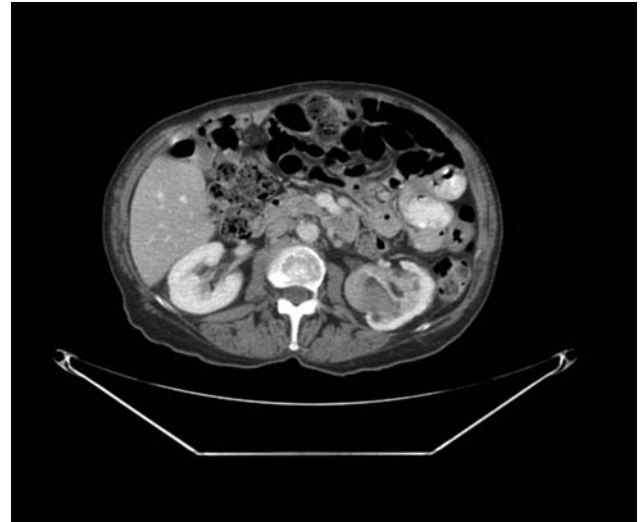


Figure 3: CT scan with the left renal mass.

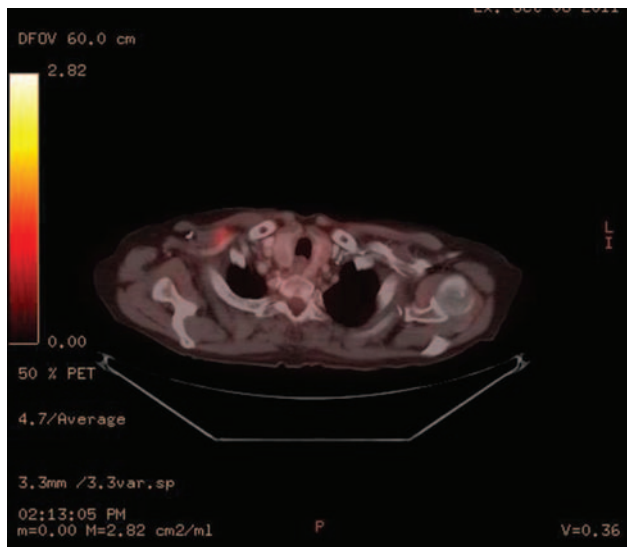


Figure 2: PET-CT scan with the enhancing right subpectoral lymph node.

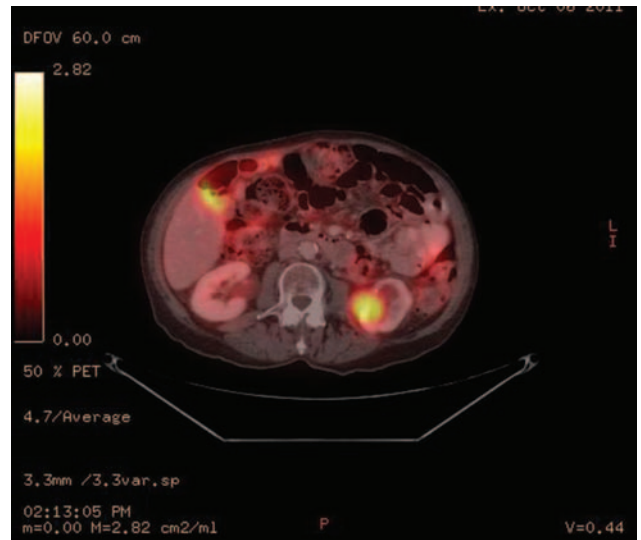


Figure 4: PET-CT scan with the enhancing left renal mass.

The patient did well post-operatively and was discharged home in a timely fashion after her nephrectomy. At her 7 month follow-up, she continues to take anti-estrogen hormonal therapy and has no demonstrable progression of disease. She has been offered surgical excision of the subpectoral lymph node, but declines at this time.

## DISCUSSION

With the improvement in cancer care and increased life expectancy in the US, tumor-to-tumor metastasis may become a more frequently encountered clinical scenario.

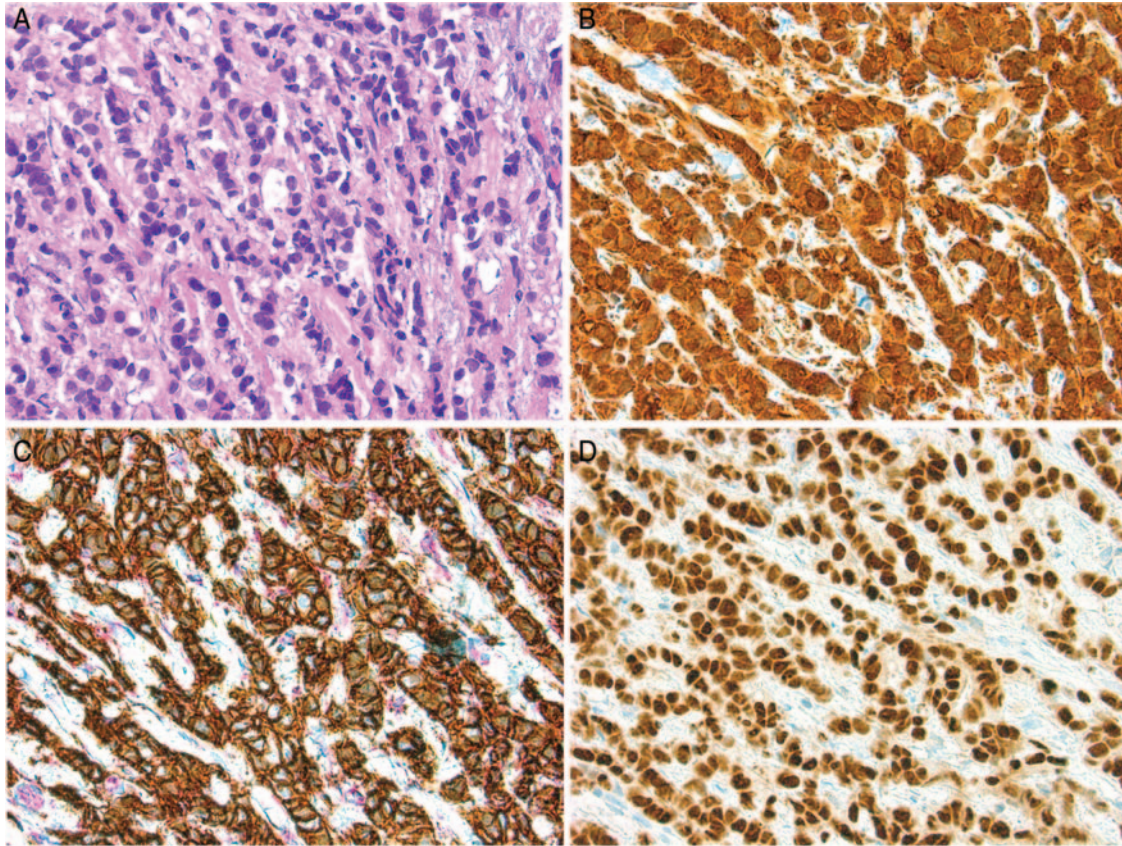
Campbell *et al.* [5] first defined tumor-to-tumor metastasis in 1968 with the following criteria: (i) documentation of more than one primary tumor; (ii) the recipient tumor is a true neoplasm; (iii) the second neoplasm is a true metastasis with established growth or invasion in the host and not a result of contiguous growth or embolization of tumor cells; and (iv) tumors that have metastasized to the lymphatic

system, where lymphoreticular malignant disease already exists, are excluded.

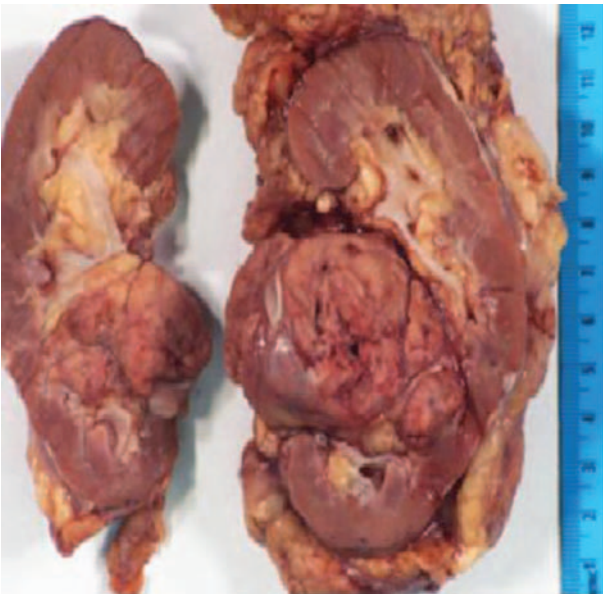
Renal cell carcinomas are overwhelmingly the most common recipient tumor involved in tumor-to-tumor metastasis. Two theories supporting this phenomenon include: (i) the rich vascularity of the kidney and renal cell carcinomas and (ii) the high lipid and glycogen content of renal cell carcinomas, which make them a favorable, nutrient-rich environment for metastasis [6].

Although tumor-to-tumor metastasis has been reported with benign recipient tumors, the occurrence is less common. Recipient tumors that have been reported include endocrine adenomas, angiomyolipomas [7], meningiomas [8, 9] and uterine leiomyomas [10]. In such cases, lung and breast cancers proved to be the most common donor tumor [9].

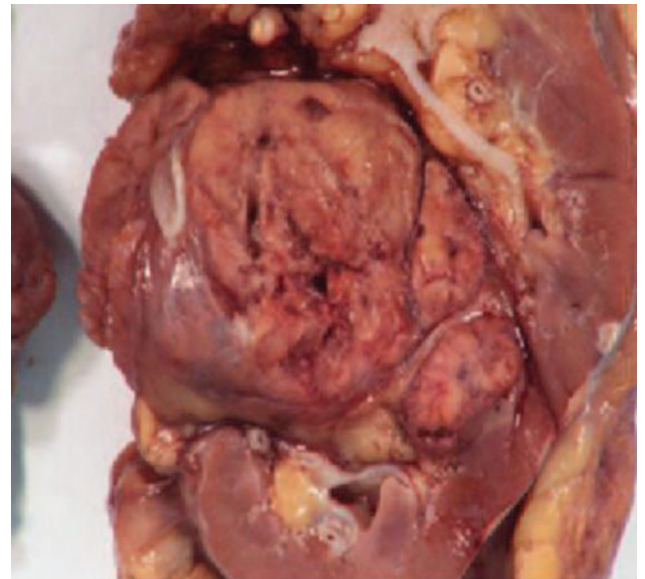




**Figure 5:** Microscopic findings of the subpectoral lymph node: H&E stain (A, B); E-cadherin and p120 dual stain to confirm the ductal nature of the cancer (C); ER staining (D).



**Figure 6:** Photograph of the gross specimen, left kidney.

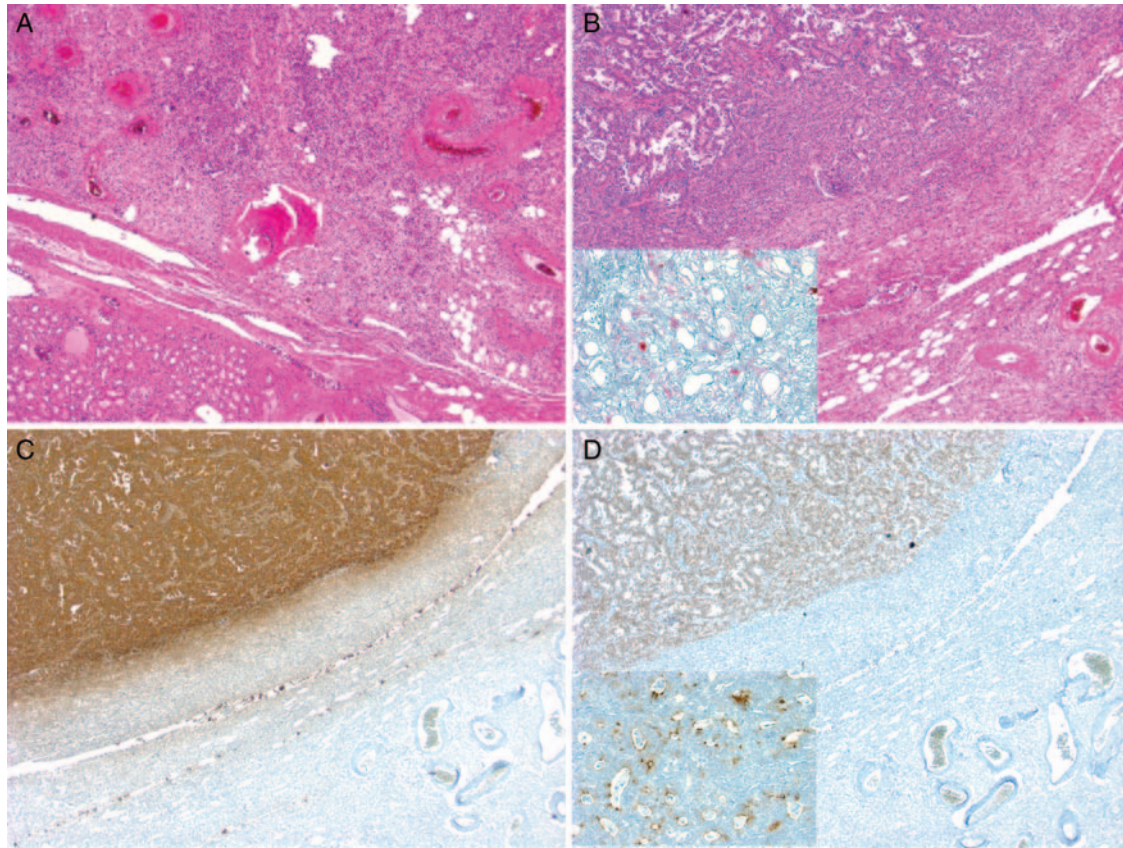


**Figure 7:** Photograph of the gross specimen, left kidney focusing on tumor.

Our current case, however, involves metastasis of a breast carcinoma to a benign renal angiomyolipoma, a scenario that was not diagnosed or expected pre-operatively, but one that

significantly affects her prognosis. Only one other such case has been reported in a patient with tuberous sclerosis complex and multiple renal angiomyolipomas with a distant history of breast cancer [7].





**Figure 8:** Microscopic findings of left nephrectomy: H&E stain (A, B), with insert in B demonstrating melanin A stain to confirm the presence of the AML; mammaglobin stain (C); Estrogen receptor stain (D), with insert demonstrating GCDFP15 stain.

The occurrence of tumor-to-tumor metastasis remains a rare phenomenon that may become a more common clinical entity with improvements in health care in developed countries and the increasing life expectancy, proving the point that a distant history of cancer should always raise suspicion of a recurrence. This case also reminds us of the enigmatic nature of breast cancer and its behavior: although metastatic, it can be indolent and slow-growing to allow detection before local symptoms arise.

### Acknowledgements

The authors thank Xin Li and Michael Mishra of the University of Pittsburgh Medical Center for supplying images from pathology and radiology.

### REFERENCES

- Ricketts R, Tamboli P, Czerniak B, Guo C. Tumor-to-tumor metastasis: report of 2 cases of metastatic carcinoma to angiomyolipoma of the kidney. *Arch Pathol Lab Med* 2008;**132**:1016–20.
- Petraki C, Vaslamatzis M, Argyrakos T, Petraki K, Strataki M, Alexopoulos C, et al. Tumor to tumor metastasis: report of two cases and review of the literature. *Int J Surg Pathol* 2003;**11**:127–35.
- Sella A, Ro J. Renal cell cancer: best recipient of tumor-to-tumor metastasis. *Urology* 1987;**30**:35–8.
- Aggrawal N, Amin R, Chung D, Parwani A. Tumor-to-tumor metastasis: Case report of a pulmonary adenocarcinoma metastatic to a clear cell renal cell carcinoma. *Pathol Res Pract* 2012;**208**:50–2.
- Campbell LV, Gilbert E, Chamberlain CR, Watne AL. Metastases of cancer to cancer. *Cancer* 1968;**22**:635–43.
- Val-Bernal JF, Villoria F, Perez-Exposito MA. Concurrent angiomyolipomas and renal cell carcinoma harboring metastatic foci of mammary carcinoma in the same kidney: an incidental autopsy finding in a patient with a follow-up of thirty years. *Ann Diagn Pathol* 2001;**5**:293–99.
- Williams TR, Oakes MF. Metastatic breast carcinoma to renal angiomyolipomas in tuberous sclerosis. *Urology* 2008;**71**: 352.e5–352.e7.
- Chambers PW, Davis RL, Blanding JD, Buck FS. Metastases to primary intracranial meningiomas and neurilemmomas. *Arch Pathol Lab Med* 1980;**104**:350–54.
- Moody P, Murtagh K, Piduru S, Brem S, Murtagh R, Rojiani A. Tumor-to-tumor metastasis: pathology and neuroimaging considerations. *Int J Clin Exp Pathol* 2012;**5**:367–73.
- Abaid LN, Rhee JM, Rausei-Mills V, Lim J, Police AM, Goldstein BH. Metastatic lobular breast carcinoma infiltrating a uterine leiomyoma. *J Minim Invasive Gynecol* 2011;**18**:674–77.