

## Successful removal of entrapped Burr with sheathless guiding during stent rotablation

Zoltán Ruzsa<sup>1,2</sup>, Árpád Lux<sup>1</sup>, István Ferenc Édes<sup>1</sup>, Levente Molnár<sup>1</sup>, Béla Merkely<sup>1</sup>

<sup>1</sup>Heart and Vascular Center, Semmelweis University; Budapest-Hungary

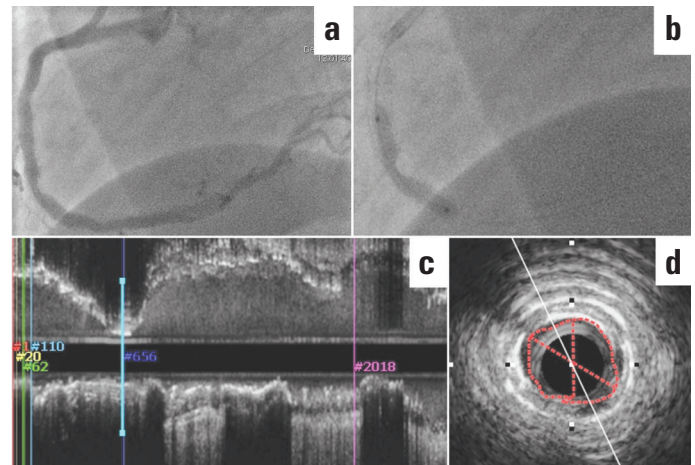
<sup>2</sup>Department of Invasive Cardiology, Bács-Kiskun County Hospital, Teaching Hospital of the Szent-Györgyi Albert Medical University; Kecskemét-Hungary

### Introduction

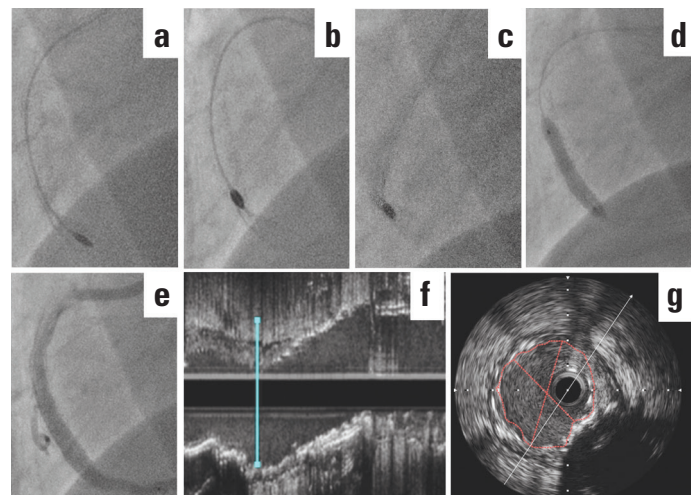
Although rotational atherectomy (RA) has been successfully performed in selected cases of stent underexpansion, a higher risk of burr lodgement demands extreme caution and surgical back-up on site (1–4). We report a case of transradial (TR) RA of a previously implanted, underexpanded stent in acute coronary syndrome (ACS) and successful nonsurgical management of burr lodgement.

### Case Report

A 75-year-old male patient with a history of hypertension and hypercholesterolemia was referred to our centre with ACS. During previous interventions, a cutting balloon (CB) dilatation, noncompliant (NC) and drug-eluting balloon dilatations, and an NC balloon dilatation with drug-eluting stent implantation (DES, Xcience 4x18 mm, Abbot Vascular, USA) of the mid-right coronary artery (RCA) had been performed. Upon admission, TR coronary angiography revealed a significant lesion in the mid-RCA with stent underexpansion and nonsignificant lesions in the left coronary system (Fig. 1a). Ad hoc RCA PCI was performed. The coronary ostium was engaged with a 6 French Judkins right guiding catheter (JR 6F, BSC, USA), and a 0.014" hydrophilic support guidewire (GW) (Whisper ES, Abbot Vascular, USA) was used to cross the lesion with the aid of a balanced middle weight (BMW) GW as a buddy wire. High-pressure (up to 30 atmospheres) inflations with an NC Trek (Abbot Vascular, USA) balloon and a Flextome CB (BSC, USA) failed to modify the target lesion (Fig. 1b). To evaluate further, intravascular ultrasound (IVUS) was performed, which identified an underexpanded stent covering a fibro-calcified RCA stenosis (Fig. 1c, d). As a bailout solution, IVUS-guided TR RA was performed. An 8.5 Fr sheathless AL1 guide (SG) (Asahi Intec Co., Aichi, Japan) was introduced into the RCA orifice, and the lesion was crossed with an extra support Rota wire (BSC, USA). After high-speed RA with an initial 1.5 mm Burr, the lesion was still resistant to NC balloon dilatation (Fig. 2a). Rotablation was upsized to a 2 mm Burr. After a few attempts of a seemingly successful RA, the burr was entrapped into the stent struts (Fig. 2b, c). After positioning the guide as close as possible



**Figure 1.** Unsuccessful dilatation of the underexpanded stent and initial IVUS scan. Stent underexpansion and significant loss of lumen were seen in RCA (panel a, white arrow). Angioplasty was attempted with a 6 F JR5 guiding catheter, a NCB and a CB. (Panel b, white arrow). Postdilatation IVUS verified MLA of 1.53 mm<sup>2</sup> (panel c and d, delineated area). CB - cutting balloon; IVUS - intravascular ultrasound; MLA - minimum lumen cross-sectional area; NCB - noncompliant balloon; RCA - right coronary artery



**Figure 2.** Rotablation and Burr lodgement. Rotablation was performed with an 8 Fr sheathless guiding catheter and 1.5 mm (panel a) and 2 mm burrs (panel b). The entrapped 2 mm burr was disengaged with deep intubation and increased gas pressure (panel c). After final CB and NCB dilations (panel d), DES was deployed (panel e). Control IVUS verified successful ablation of old metallic and calcified rings (Panel f, g). CB - cutting balloon; DES - drug-eluting stent; IVUS - intravascular ultrasound; NC - noncompliant balloon; RCA - right coronary artery

to the entrapped device (deep intubation), turbine pressure was increased, and under gentle pullback, the burr was finally disengaged. The procedure was finished with a final CB and NC balloon dilatation (3.5x10 mm Flextome Cutting balloon, BSC, USA), and DES (Promus Premier 4.0x20 mm, BSC, USA) was implanted (Fig. 2d, e). The final IVUS scan revealed successful ablation of both the former metallic and calcified rings (Fig. 2f, g). Angiography showed no residual stenosis and confirmed a TIMI III flow. The patient remained asymptomatic during his 2-year follow-up.

## Discussion

Stent underexpansion is a strong predictor of in-stent restenosis and stent thrombosis. Therefore, in calcified lesions, stent implantation can only be performed after adequate dilatation with NC balloons. In lesions resistant to NC balloon dilation, CB angioplasty or RA can facilitate successful stent deployment. During the detection of a suboptimal stent expansion, the stent can be dilated at a very high pressure with a double layer OPN NC balloon (SIS Medical AG; Winterthur, Switzerland) or the stent struts can be ablated with RA or excimer laser (1–6). For TR interventions, the catheter size is mostly limited to a 6 Fr guide and restricts the rota Burr size to a maximum of 1.75 mm. However, SGs allow the use of bigger Burrs up to 2 mm (7). In this specific case, the substantial calcification of the lesion and the previously underexpanded stent lead to burr entrapment, which is the main potential complication of stent RA. IVUS-guided Burr selection, slow advancement and higher Burr speed, and parking of the Burr proximal to the stent can help avoid the burr jump and subsequent entrapment. The entrapped Burr can be dislodged with the parallel ballooning technique or deep intubation technique with a guide or guideliner (8, 9). In our case, the burr was dislodged by increasing the speed and using the deep intubation technique with SG. The careful pull-back is mandatory to avoid breaking the delivery system and to prevent distal embolization.

## Conclusion

Sheathless guiding catheters via radial access can facilitate rotational atherectomy of stents in large lumen coronary arteries. The entrapped burr can be removed with a deep intubation technique.

## References

1. Barbato E, Carrié D, Dardas P, Fajadet J, Gaul G, Haude M, et al. European expert consensus on rotational atherectomy. *EuroIntervention* 2015; 11: 30-6.
2. Sperling RT, Ho K, James D, Laham R, Gibson M, Carrozza J. Treatment of stent-jailed side branch stenoses with rotational atherectomy. *J Invasive Cardiol* 2006; 18: 354-8.
3. Vales L, Coppola J, Kwan T. Successful expansion of an underexpanded stent by rotational atherectomy. *Int J Angiol* 2013; 22: 63-8.
4. Édes IF, Ruzsa Z, Szabó G, Lux Á, Gellér L, Molnár L, et al. Rotational atherectomy of undilatable coronary stents: stent ablation, a clinical perspective and recommendation. *EuroIntervention* 2016; 12: e632-5.
5. Wilson A, Ardehali R, Brinton TJ, Yeung AC, Lee DP. Cutting balloon inflation for drug-eluting stent underexpansion due to unrecognized coronary arterial calcification. *Cardiovasc Revasc Med* 2006; 7: 185-8.
6. Sunew J, Chandwaney RH, Stein DW, Meyers S, Davidson CJ. Excimer laser facilitated percutaneous coronary intervention of a nondilatable coronary stent. *Catheter Cardiovasc Intervent* 2001; 53: 513-7.
7. Kassimis G, Patel N, Kharbanda RK, Channon KM, Banning AP. High-speed rotational atherectomy using the radial artery approach and a sheathless guide: a single-centre comparison with the 'conventional' femoral approach. *EuroIntervention* 2014; 10: 694-9.
8. Sulimov DS, Abdel-Wahab M, Toelg R, Kassner G, Geist V, Richardt G. Stuck rotablator: the nightmare of rotational atherectomy. *EuroIntervention* 2013; 9: 251-8.
9. Tanaka Y, Saito S. Successful retrieval of a firmly stuck rotablator burr by using a modified STAR technique. *Catheter Cardiovasc Interv* 2016; 87: 749-56.

**Address for Correspondence:** Zoltán Ruzsa MD, PhD.

Semmelweis University Heart and Vascular Center

1122 Budapest, Városmajor Street 68-Hungary

Phone: +36-1-4586840 Fax: +36-1-458-6842

E-mail: zruzsa25@gmail.com

©Copyright 2017 by Turkish Society of Cardiology - Available online at [www.anatoljcardiol.com](http://www.anatoljcardiol.com)

DOI: 10.14744/AnatolJCardiol.2017.7519

