

## Case Report

# Herpes Simplex Ulcerative Esophagitis in Healthy Children

Abdulrahman A. Al-Hussaini, Mosa A. Fagih<sup>1</sup>

Department of Pediatrics,  
Division of Pediatric  
Gastroenterology, Children's  
Hospital, <sup>1</sup>Department of  
Pathology, King Fahad Medical  
City, Riyadh, Saudi Arabia

**Address for correspondence:**  
Dr. Abdulrahman Al-Hussaini,  
Division of Pediatric  
Gastroenterology, Hepatology  
and Nutrition, Children's  
Hospital, King Fahad Medical  
City, Riyadh Postal code 11525,  
Kingdom of Saudi Arabia.  
E-mail: aa\_alhussaini@yahoo.  
com

## ABSTRACT

Herpes simplex virus is a common cause of ulcerative esophagitis in the immunocompromised or debilitated host. Despite a high prevalence of primary and recurrent Herpes simplex virus infection in the general population, Herpes simplex virus esophagitis (HSVE) appears to be rare in the immunocompetent host. We report three cases of endoscopically-diagnosed HSVE in apparently immunocompetent children; the presentation was characterized by acute onset of fever, odynophagia, and dysphagia. In two cases, the diagnosis was confirmed histologically by identification of herpes viral inclusions and culture of the virus in the presence of inflammation. The third case was considered to have probable HSVE based on the presence of typical cold sore on his lip, typical endoscopic finding, histopathological evidence of inflammation in esophageal biopsies and positive serologic evidence of acute Herpes simplex virus infection. Two cases received an intravenous course of acyclovir and one had self-limited recovery. All three cases had normal immunological workup and excellent health on long-term follow-up.

**Key Words:** Children, esophagitis, herpes simplex virus

Received 02.10.2010, Accepted 19.11.2010

**How to cite this article:** Al-Hussaini AA, Fagih MA. Herpes simplex ulcerative esophagitis in healthy children. Saudi J Gastroenterol 2011;17:353-6.

Herpes simplex virus (HSV) is a common cause of ulcerative esophagitis in the immunocompromised or debilitated host.<sup>[1]</sup> Despite a high prevalence of primary and recurrent HSV infection in the general population, HSV esophagitis (HSVE) appears to be rare in the immunocompetent host.<sup>[2]</sup> The entity may be underdiagnosed, however, because it is not considered in the differential diagnosis of odynophagia in children (presenting as an acute self-limited illness), if they do not have an underlying immunocompromised state. We report three cases of endoscopically-diagnosed HSVE in apparently immunocompetent children; two of these children had no evidence of herpetic lesions on the lips or oropharynx but proceeded to endoscopic and histopathological diagnosis because the clinical characteristics suggested that HSVE was present.

## CASE REPORTS

### Patient 1

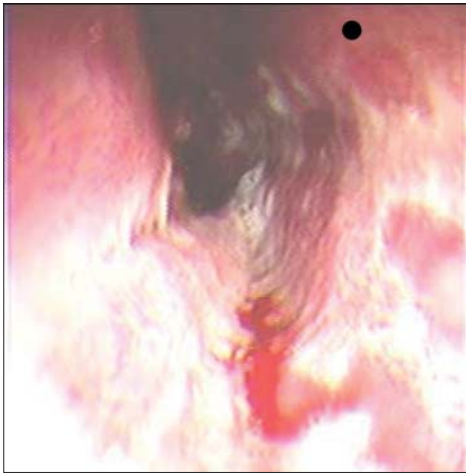
A healthy 13-year-old male presented with sudden onset

of odynophagia, retrosternal pain and fever for three days. There was no history of vomiting, recent weight loss, previous gastrointestinal complaints, medications or ingestion of corrosives. He had no risk factors for acquisition of human immunodeficiency virus (HIV) or history of contact with anyone with HSV infection. Physical examination was unremarkable except for a temperature of 38.5°C. In particular, he had no skin, lip or oropharyngeal lesions. Endoscopy revealed multiple discrete ulcers with erythema in the upper esophagus and extensive confluent ulceration with necrotic exudates in the lower half of the esophagus [Figure 1]. The patient improved over 72 h on oral omeprazole 20 mg twice a day. Histological examination of the esophageal mucosal biopsies showed acute inflammation and intranuclear inclusions consistent with viral infection [Figure 2]. Immunoperoxidase staining and viral culture confirmed HSV-1 infection [Figure 3]. Fungal stains were negative. Testing for HSV Immunoglobulin G and immunoglobulin M type IgG and IgM were positive. Immunological workup, including total immunoglobulins, immunoglobulin-G subclasses and T-lymphocyte subsets, were normal. The patient remained well for four months following the onset of his illness, without recurrence of esophageal symptoms or developing evidence of an immune deficiency.

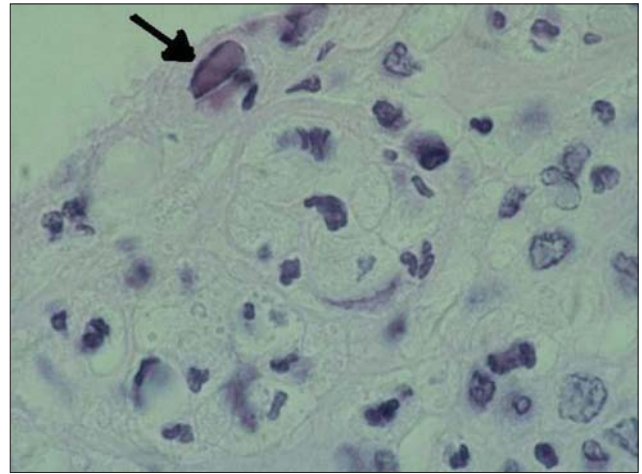
### Patient 2

A three-year-old girl presented with acute onset of

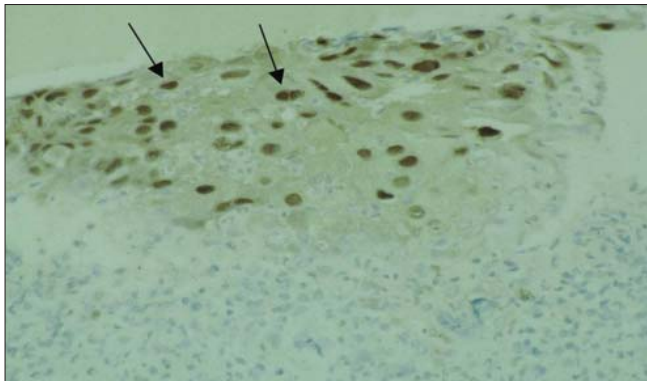
Access this article online	
	<b>Quick Response Code:</b>
	<b>Website:</b> www.saudijgastro.com
	<b>PubMed ID:</b> 21912064
<b>DOI:</b> 10.4103/1319-3767.84496	



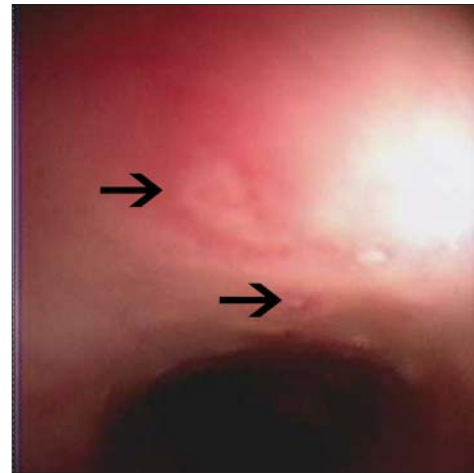
**Figure 1:** Endoscopic view of necrotic, confluent esophageal ulcers



**Figure 2:** Viral intranuclear inclusion (arrow) from esophageal ulcer biopsy (hematoxylin-eosin stain  $\times 200$  high power field HPF)



**Figure 3:** Positive immunostaining for HSV-1 (arrows), (Immunoperoxidase staining  $\times 200$  high power field HPF)



**Figure 4:** Endoscopic view of discrete esophageal ulcers (arrows)

odynophagia, retrosternal pain, fever, and refusal of food and fluids for six days. She had been diagnosed with nutcracker esophagus at age 18 months when she presented with dysphagia, irritability, and characteristic high-amplitude peristaltic contractions on esophageal manometry study. She had complete resolution of symptoms for the past year on calcium channel blocker. There was no history suggestive of gastroesophageal reflux (GER), foreign body ingestion, medication or ingestion of a corrosive substance. She had been in close contact with her father who had a “cold sore”. Physical examination revealed a well-nourished, ill-looking girl with a temperature of  $38^{\circ}\text{C}$ , and moderate dehydration. There were no skin, lip or oropharyngeal lesions. Upper endoscopy revealed multiple, discrete, small-diameter and well-circumscribed ulcers from the mid to lower esophagus [Figure 4]. Biopsies showed intranuclear viral inclusions and immunoperoxidase staining and viral culture were positive for HSV Type 1. The patient was able to tolerate a soft diet 48 h after starting intravenous acyclovir. Immunological workup, including total immunoglobulins, immunoglobulin-G subclasses and T-lymphocyte subsets, were normal. On

follow-up, the child maintained good health with no recurrence of esophageal symptoms.

### Patient 3

A 12-year-old previously healthy youth presented with four days of sudden severe odynophagia, marked retrosternal pain and fever. This was preceded by a prodromal illness of headache, sore throat, generalized malaise and painful lip ulcer of one-week duration. There was no history of previous gastrointestinal complaints, recent weight loss, trauma, surgical procedures or endoscopy. The patient had no risk factors for HIV infection. Physical examination revealed a well-nourished boy, with a temperature of  $39^{\circ}\text{C}$  and a crusted, possibly herpetiform lesion on his lower lip. The rest of his examination was normal. Because of the severity of his symptoms, he was treated with intravenous morphine and intravenous acyclovir. Twenty-four hours later, upper endoscopy was performed to confirm the diagnosis. He had inflamed friable, ulcerated mucosa in

the mid to lower esophagus with multiple small ulcers arranged linearly. He also had a few gastric body erosions. Biopsies showed an acute inflammatory infiltrate with exudates of neutrophils consistent with an adjacent ulcer, but no evidence of intranuclear inclusion bodies. Immunoperoxidase staining and viral culture were negative. Serological evaluation revealed positive HSV IgM and negative HSV IgG. Twenty-four hours later, the patient was able to tolerate soft diet. Immunological testing included normal serum immunoglobulins and negative serology for HIV. The patient completed ten days of acyclovir and two weeks of oral ranitidine 4 mg/kg/day. His immunologic testing was normal and subsequent health was excellent.

## DISCUSSION

Primary HSV infections are common in childhood. By adolescence, 90% of all individuals possess antibody to Type 1 HSV.<sup>[3]</sup> The peak incidence of clinical disease is at two years of life, with gingivostomatitis the most common expression.<sup>[3]</sup> We have identified 17 cases of HSVE in immunocompetent children reported in the English language medical literature.<sup>[4-12]</sup>

Patients with severe herpes gingivostomatitis or pharyngitis may have unrecognized esophagitis. In the young child refusal of oral intake may be due to both odynophagia as well as oral discomfort. Additionally, since HSVE is a self limiting condition in the immunocompetent host, some patients may be diagnosed with reflux-associated symptoms if their clinical improvement coincides with the institution of acid-suppression therapy.

HSVE in immunocompetent children usually represents primary, isolated infection, but may follow reactivation<sup>[4]</sup> and has been associated with gastric involvement in a few cases.<sup>[13,14]</sup> Males are more commonly affected than females with a ratio of 3.4:1.<sup>[15]</sup> Our patients' presentations were similar to those described in the literature with the acute onset of the triad of odynophagia, retrosternal pain and fever which may be preceded by a flu-like prodrome for three to ten days. As reported previously it is more common not to have concurrent oral lesions, although in the presence of oral lesions the patients may not have had endoscopy to examine whether esophagitis was present.<sup>[7]</sup> It has been hypothesized that trauma to the esophageal tissue may predispose to HSVE in an immunocompetent host. Such trauma may result from GER, esophageal instrumentation, nasogastric drainage, ingestion of caustics or retained foreign body.<sup>[16-18]</sup> Our patients had no history suggestive of GER or other predisposing factors.

In patients without sentinel lesions endoscopy and biopsy are helpful to establish the diagnosis. All our patients

had characteristic endoscopic findings of friable mucosa, numerous, superficial ulcers, some discrete and others arranged in a linear pattern, typically involving mid to distal esophagus. Patient 1 had more extensive involvement of the entire esophagus with confluent ulcers covered with necrotic exudates, which was difficult endoscopically to differentiate from a candida infection.<sup>[19]</sup> Although endoscopic appearance of HSVE can be characteristic, the differential diagnoses of esophageal ulcers include other infections (cytomegalovirus, herpes zoster virus, HIV, candida and bacteria), trauma including thermal injury, ingestion of corrosives, oral medication in pill form, and inflammatory conditions such as Crohn's disease or Bechet's disease.<sup>[15]</sup>

Histopathologically the diagnosis of HSVE can be suggested by a combination of acute inflammation, ulceration and epithelial cell changes suggestive of viral infection, including ballooning degeneration and necrosis.<sup>[7]</sup> However, absolute histological diagnosis of HSVE requires identification of herpes viral inclusions or culture of the virus in the presence of inflammation. Biopsies from the edge of ulcers provide the best diagnostic yield.<sup>[18]</sup>

HSVs in previous series were almost always Type 1,<sup>[15]</sup> consistent with our findings in Patient 1 and 2. We have not been able to isolate HSV from the esophageal tissue in Patient 3, probably because of the preceding antiviral therapy, but the clinical history, presence of typical cold sore on his lip, typical endoscopic findings, acute inflammation in esophageal biopsies, and seropositivity of HSV IgM made a probable diagnosis of HSVE.

HSVE is usually self-limited with a favorable outcome in the majority of immunocompetent patients. Hematemesis and esophageal perforation have been reported.<sup>[10,20]</sup>

Prompt recovery from infection and normal health on follow-up would suggest that our patients had intact humoral and cellular immunity. A detailed immunological workup may not be indicated unless HSVE persists or recurs. Careful history-taking is important to look for an underlying immunologic disease or risk factors for HIV infection.

The mainstay of therapy is maintenance of hydration, nutrition and adequate analgesia including acid suppression therapy. In patients 2 and 3, symptomatic relief occurred within 48 h after instituting intravenous acyclovir. The duration of symptoms in patients receiving symptomatic treatment only, ranged between 2-20 days after presentation.<sup>[2]</sup> The use of intravenous acyclovir to treat HSVE in an immunocompetent host is still controversial,<sup>[2,8,15,21]</sup> due to lack of controlled studies, which may not be feasible because of the rarity of the disease. We feel that early initiation of acyclovir may shorten the clinical course of the disease,

particularly in patients with severe odynophagia.

HSVE remains an unusual infection in healthy children but probably occurs more often than is currently recognized, and should be considered in any child presenting with odynophagia even in the absence of skin or oropharyngeal lesions.

## REFERENCES

1. Buss DH, Scharyj M. Herpes virus infection of the esophagus and other visceral organs in adults. *Am J Med* 1979;66:457-62.
2. Ramanathan J, Rammouni M, Baran J, Khatib R. Herpes simplex virus esophagitis in the immunocompetent host: An overview. *Am J Gastroenterol* 2000;95:2171-76.
3. Krugman S, Kats SL. Herpes virus infection, In: Krugman, Katz SL, editors. *Infectious diseases of children*, St. Louis: The CV Mosby Company; 1981. p. 130.
4. Bastian JF, Kaufman LA. Herpes simplex esophagitis in a healthy 10-year-old boy. *J Pediatr* 1982;100:426-7.
5. Desigan G, Schneider RP. Herpes simplex esophagitis in healthy adults. *South Med J* 1985;78:1135-7.
6. Stillman AE. Herpes esophagitis in normal children. *J Pediatr* 1986;109:563-4.
7. Ashenberg C, Rothstein FC, Dahms BB. Herpes esophagitis in the immunocompetent child. *J Pediatr* 1986;108:584-7.
8. Moore DJ, Davidson GP, Binns GF. Herpes simplex esophagitis in young children. *Med J Aust* 1986;144:716-7.
9. Lambert H, Eastham EJ. Herpes esophagitis in a healthy 8 year old. *Arch Dis Child* 1987;62:301-2.
10. Chusid MJ, Oechler HW, Werlin SI. Herpetic esophagitis in an immunocompetent boy. *Wisc Med J* 1992;91:71-2.
11. Rodrigues F, Brandao N, Duque V, Ribeiro C, Antonio AM. Herpes simplex virus esophagitis in immunocompetent children. *J Pediatr Gastroenterol Nutr* 2004;39:560-3.
12. Rahhal RM, Ramkumar DP, Pashankar DS. Simultaneous herpetic and candidal esophagitis in an immunocompetent teenager. *J Pediatr Gastroenterol Nutr* 2005;40:371-3.
13. Depew WT, Prentice RS, Beck IT, Blakeman JM, DaCosta LR. Herpes simplex ulcerative esophagitis in a healthy subject. *Am J Gastroenterol* 1977;68:381-5.
14. Al-Samman M, Zuckerman M, Verghese A, Boman D. Gastric ulcers associated with herpes simplex esophagitis in a nonimmunocompromised patient. *J Clin Gastroenterol* 1994;18:160.
15. Galbraith JC, Shafran SD. Herpes simplex esophagitis in the immunocompetent patient: Report of four cases and review. *Clin Infect Dis* 1992;14:894-901.
16. Dipalma JA, Brady CE. Herpes simplex esophagitis in a nonimmunosuppressed host with gastroesophageal reflux. *Gastrointest Endosc* 1984;30:24-5.
17. Pazin GJ. Herpes simplex esophagitis after trigeminal nerve surgery. *Gastroenterology* 1978;74:741-3.
18. Nash G, Ross JS. Herpetic esophagitis: A common cause of esophageal ulceration. *Hum Pathol* 1974;5:339-45.
19. Goff JS. Infectious causes of esophagitis. *Ann Rev Med* 1988;39:163-9.
20. Crostedt JL, Bouchama A, Hainau B, Halim M, Khouqeer F, al Darsouny T. Spontaneous esophageal perforation in herpes simplex esophagitis. *Am J Gastroenterol* 1992;87:124-7.
21. Kurahara K, Aoyagi K, Nakamura S, Kuwano Y, Yamamoto C, Iida M. Treatment of herpes simplex esophagitis in an immunocompetent patient with intravenous acyclovir. A case report and review of literature. *Am J Gastroenterol* 1998;9:2239-40.

**Source of Support:** Nil, **Conflict of Interest:** None declared.