



Case report

A Pseudoaneurysm of the Inferior Lateral Geniculate Artery Following Total Knee Arthroplasty

Raymond Puijk, MD ^{a,*}, Rachid Rassir, MD ^a, Lars W. Kaufmann, MD ^b, Peter A. Nolte, MD, PhD ^a

^a Department of Orthopaedic Surgery, Spaarne Gasthuis, Hoofddorp, the Netherlands

^b Department of Radiology, Spaarne Gasthuis, Hoofddorp, the Netherlands

ARTICLE INFO

Article history:

Received 12 February 2022

Received in revised form

15 March 2022

Accepted 16 March 2022

Keywords:

Pseudoaneurysm

Total knee arthroplasty

Inferior lateral geniculate artery

Dabigatran

Anticoagulation

ABSTRACT

Vascular complications after total knee arthroplasty are rare. We present a case of an inferior lateral geniculate artery pseudoaneurysm which became symptomatic 10 days after total knee arthroplasty in a patient with a cardiac comorbidity and using dabigatran. The pseudoaneurysm was most likely caused by iatrogenic injury during surgery. Fourteen days after the index surgery, the patient was seen with a painful but normal post-total knee arthroplasty effused knee, with a maximum flexion angle of 80 degrees. No signs of infection, hemarthrosis, or neurovascular deficit were present. Radiographic imaging included ultrasonography and computed tomography angiography. The pseudoaneurysm was successfully treated with coil embolization. The etiology, presentation, diagnosis, and treatment of a geniculate artery pseudoaneurysm are discussed in this case report.

© 2022 The Authors. Published by Elsevier Inc. on behalf of The American Association of Hip and Knee Surgeons. This is an open access article under the CC BY-NC-ND license (<http://creativecommons.org/licenses/by-nc-nd/4.0/>).

Introduction

Total knee arthroplasty (TKA) is considered the gold standard for severe symptoms of degenerative joint disease of the knee. Even though it is a relatively safe procedure, several complications can occur. One of the lesser-known and extremely rare complications is the development of a pseudoaneurysm, which is estimated to symptomatically occur at around 0.01%–0.09% of all TKAs, being more prevalent in revision procedures [1–4]. This is assumed to be a grave underestimation due to underrecognition in less symptomatic cases.

The most likely mechanism of trauma that causes the formation of a pseudoaneurysm is iatrogenic trauma, due to penetrating or blunt injury to an artery. Such vascular trauma often involves the popliteal artery, anterior tibial artery, or one of the geniculate arteries [5]. Risk factors for pseudoaneurysms are not known due to the low incidence, but vascular comorbidities (eg, diabetes, peripheral vascular disease) and female gender have often been linked to vascular complications after TKA in general [6–8].

We describe the case of a pseudoaneurysm development of the inferior lateral geniculate (ILG) artery 2 weeks after primary TKA in a patient with cardiac comorbidity and using dabigatran.

Case history

The patient's informed consent was obtained for the publication of this case report. In 2015, a 67-year-old male underwent a TKA for severe symptoms of osteoarthritis of his right knee. His medical conditions include osteoarthritis of the left knee for which he received a TKA and recurrent transient ischemic attacks due to a hypermobile interatrial septum. Medication for the recurrent transient ischemic attacks consisted of dabigatran (110 mg twice daily). After consulting the neurologist and cardiologist, it was recommended to bridge with low-molecular-weight heparin (LMWH) 48 hours prior to surgery (5700 IU twice daily) and resume the dabigatran once the wound was free of discharge. The last preoperative dose of LMWH was administered 15 to 20 hours prior to surgery. An uncemented, cruciate-sacrificing, rotating platform knee system (Low Contact Stress; DePuy, Warsaw, IN) was placed through a medial arthrotomy during TKA without the use of a tourniquet. The operation proceeded without any apparent perioperative complications. Estimated blood loss during surgery was 200 cc. The patient was discharged from the hospital 2 days

* Corresponding author. Department of Orthopaedic Surgery, Spaarne Gasthuis, Spaarnepoort 1, 2134 TM, Hoofddorp, the Netherlands.

E-mail address: rpuijk@spaarneasthuis.nl

after the surgery and advised to resume the dabigatran for 3 days postoperatively. Ten days after the surgery, the patient experienced increasing pain and swelling over the course of 4 days, which started after feeling a “snap” while cycling on his home trainer. Physical examination in the outpatient clinic revealed no signs of infection, no hemarthrosis, no calf tenderness, no neurovascular deficit, normal post-TKA knee effusion, and a maximum flexion angle of 80 degrees. After reassurance, the patient was discharged with adequate analgesia and instructions to contact the hospital in case of increasing pain or signs of infection. Six days after the outpatient visit (24 days after surgery), the patient again presented with a persisting increase in pain and effusion in his operated knee. Physical examination revealed no signs of infection, no calf tenderness, an extension lag of 10°, and hemarthrosis. The presence of a pulsatile mass was not reported. Blood tests showed normal white blood cell count, C-reactive protein (CRP) of 39 mL/L, hematocrit of 0.41 l/l, and erythrocyte sedimentation rate of 2 mm/h. Due to increasing pain, discomfort, and effusion, an ultrasound was performed.

The duplex Doppler ultrasonography (DDU) showed a pulsating mass of 3.1 cm in diameter lateral in the knee joint with a characteristic “yin-yang” sign on color Doppler (Fig. 1). These findings warranted computed tomography angiography and consultation with a vascular surgeon. Computed tomography angiography showed the contrast-filled mass to be located near the anterolateral aspect of the polyethylene insert and confirmed it to be a pseudoaneurysm originating from the ILG artery (Fig. 2). Eventual treatment consisted of endovascular coil embolization (1 × 3-mm, 2 × 4-mm, and 2 × 5-mm micro coils), performed by the consultant interventional radiologist (L.W.K.). The patient was advised to wear an extension brace while walking for 2 months. The hemarthrosis was resolved 1 month after coiling.

Two reoperations that were not related to the pseudoaneurysm followed. After coiling, the knee showed an initial functional improvement but deteriorated to a significant extension restriction

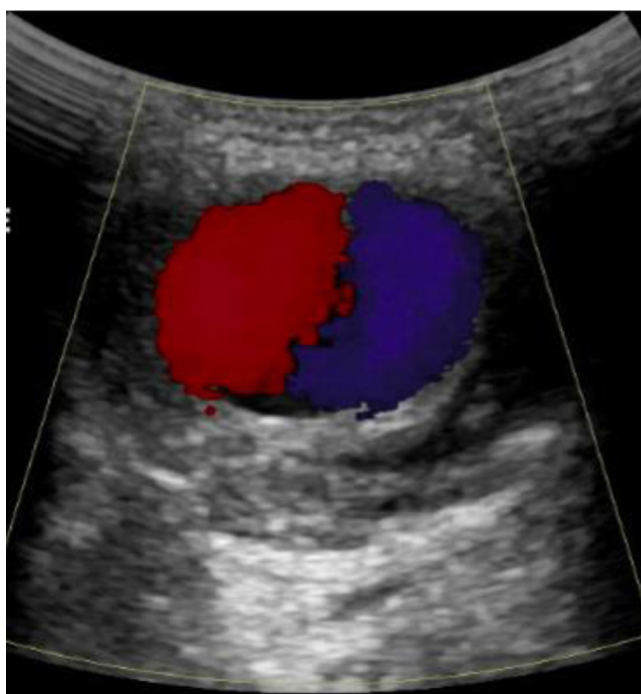


Figure 1. Color Doppler sonogram showing a typical “yin-yang” sign of the to-and-fro turbulent arterial flow in the pseudoaneurysm of the inferior lateral geniculate artery of the right knee.

of 20 degrees 15 months after the index surgery. A manipulation under anesthesia and an arthroscopic lysis of adhesions was performed to retrieve full range of motion. One month later (16 months after the index surgery), the patient was seen with a persisting wound drainage (opaque green/yellow fluid), effusion of the knee, and blood tests showing a CRP of 168 mg/L and erythrocyte sedimentation rate of 23 mm/h. The knee was aspirated for cytology (white blood cell count >25 per field of view), and the aspirated fluid was cultured. Due to a high suspicion of a periprosthetic joint infection, an arthroscopic debridement of the joint was performed. An arthrotomy with change of insert was avoided to prevent jeopardizing the coil in situ. No clear signs of an active infection were seen during the arthroscopy, but based on the persistent drainage and the blood test, the patient was locally and systematically treated with antibiotics until CRP would normalize or tissue cultures were found negative. Over the course of several days, cultures were found positive for *Staphylococcus capitis* and *Staphylococcus warneri*; however, due to the patient’s progressive improvement under antibiotics, no further surgery was considered necessary. During the 3 months after the arthroscopic debridement, infection parameters decreased significantly after which the antibiotics could be stopped. At the current follow-up (5 years after the index surgery), the patient is still dissatisfied with his knee replacement due to remaining pain and a limited flexion angle of 90 degrees. Preoperative and postoperative radiographs can be seen in Figures 3 and 4.

Discussion

Iatrogenic vascular injuries after TKA are extremely rare, with an overall estimated incidence of 0.03%–0.2% [5,7,8]. In the current case, the ILG artery was compromised during TKA, which caused the formation of a pseudoaneurysm. Pseudoaneurysms after TKA are typically formed after blunt or penetrating trauma during surgery, causing a local hematoma that is contained by surrounding tissue [9–11]. The ILG artery is derived from the popliteal artery at the level of the joint line, winding around the lateral meniscus to the front of the knee and supplies the inferolateral structures of the knee [9,12]. The ILG artery is at risk during TKA when releasing structures of the proximal tibia (eg, lateral meniscus) or during retraction [9,12,13].

Although the TKA discussed in this case report was performed without any perioperative particularities or complications, it is noteworthy that this case was different from other TKAs in terms of perioperative bridging. In this case, the risk of a new thromboembolic event was considered larger than the bleeding risk of the procedure. For this reason, perioperative bridging with LMWH was deemed necessary. Unlike at the time in which this TKA was performed, current guidelines suggest to interrupt dabigatran during procedures with a high bleeding risk, without bridging them with LMWH [14–16]. Therefore, it is theoretically possible that the LMWH in this case could have prevented a spontaneous thrombosis of the pseudoaneurysm [17]. However, the use of anticoagulants around the time of TKA is definitely not uncommon, and an association between dabigatran and/or LMWH and the formation of a pseudoaneurysm has never been reported in the literature. It is therefore difficult to say whether the anticoagulants in this case had any role in the development of pseudoaneurysm.

The typical presentation of a pseudoaneurysm around the knee may include pain, swelling, (recurrent) hemarthrosis, presence of a pulsating mass, and signs of a common peroneal nerve palsy [5,13]. In contrast to the typical presentation, no pulsating mass was found in this current case despite the finding of a pulsating mass with the DDU. Other potential causes of similar symptoms are an acute deep venous thrombosis (DVT), entrapment of the synovial tissue, or

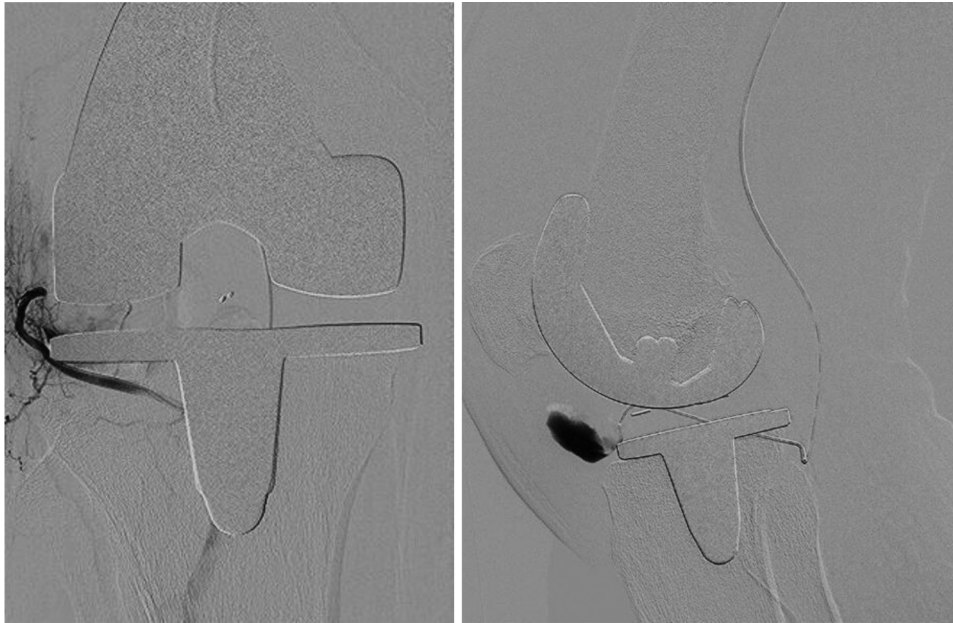

Figure 2. Computed tomography angiography on an anteroposterior (left) and a lateral (right) view showing a pseudoaneurysm of the inferior lateral geniculate artery of the right knee.

Hoffa's fat pad impingement between knee system components [5,18,19]. When a pseudoaneurysm reaches a certain size, it can compress a traversing vein and theoretically cause DVT-like symptoms [13]. This may be one of the reasons why a pseudoaneurysm is often found on an ultrasound originally ordered for the suspicion of a DVT.

When focusing on the chronology of this case, the complication was most likely caused during surgery but luxated ("snapped") while cycling on the home-trainer at 10 days postoperatively. The time from surgery to the onset of symptoms was shorter than it was reported in other cases with geniculate artery pseudoaneurysms (range 0.5–6 weeks) [5,9,11,19,20]. Previous studies that described

cases of popliteal pseudoaneurysms reported that prompt recognition, diagnosis, and treatment is of utmost importance to prevent the development of soft-tissue ischemia and compartment syndrome [1,2,21]. To our knowledge, no studies have reported these complications after a pseudoaneurysm of a geniculate artery. However, geniculate artery pseudoaneurysms can by all means impede postoperative rehabilitation and, if large enough, cause the same serious complications as popliteal pseudoaneurysms. In our case, 2 weeks passed before radiographic imaging was requested because a normal postoperative knee effusion was initially considered as the cause of the symptoms. In the study of Daniels et al., an imaging workflow algorithm was created to shorten this

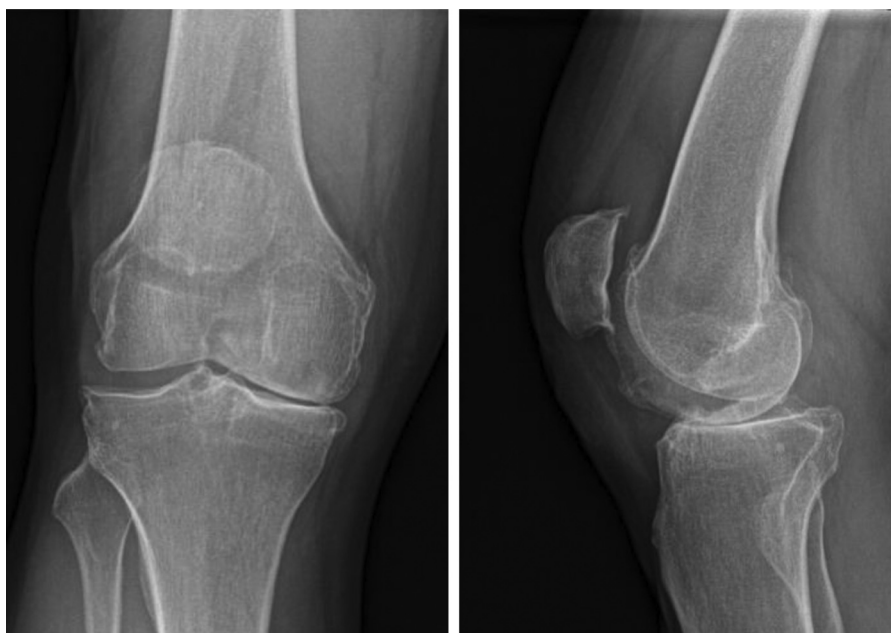


Figure 3. Anteroposterior (left) and lateral (right) radiograph performed 3 months before the operation.

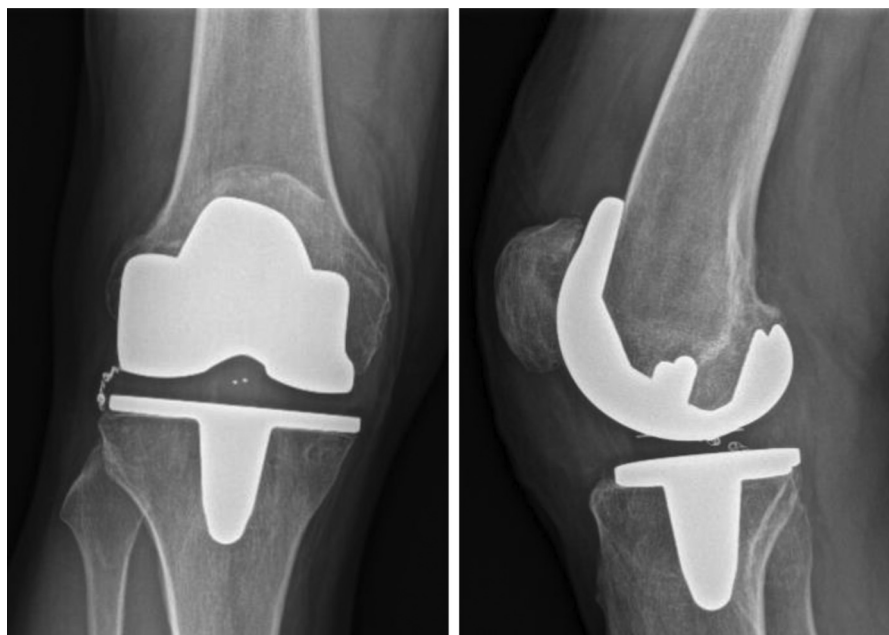


Figure 4. Anteroposterior (left) and lateral (right) radiograph performed 5 years after the operation.

delay [5]. They aimed to exclude post-TKA pseudoaneurysms in postoperative painful effused knees, by performing a DDU in cases that also had hemarthrosis or a drop in hematocrit [5]. Unfortunately, cost-effectiveness of this workflow algorithm was not reported in this study. A DDU is a very sufficient initial diagnostic tool when used by an experienced person to demonstrate the appearance of a communicating aneurysmal neck between the injured artery and the pseudo aneurysmal sac [22]. Sensitivity and specificity of 94% and 97%, respectively, were reported for detecting peripheral pseudoaneurysms after performing 64 DDUs in patients with symptomatic and asymptomatic postcatheterization pseudoaneurysms [23]. The “yin-yang sign” and “to-and-fro” flow pattern on DDU are typical for pseudoaneurysms; however, a “yin-yang sign” may also occur in sacular aneurysms [5,22]. However, a definite diagnosis is mostly obtained by angiography.

Management of a pseudoaneurysm depends on the artery, size, and location. In pseudoaneurysms smaller than 1.8 cm in diameter, spontaneous thrombosis can occur [5,17,24]. Other small pseudoaneurysms may resolve after compression dressings and the cessation of anticoagulation [11]. Surgical interventions include endovascular stenting, coil embolization, or an open vascular repair [5,11,13,19]. Open vascular repairs are commonly performed in case of pseudoaneurysms from popliteal arteries, in which remaining complaints are not unusual, including a functional impairment, sensory or motoric function deficit, and/or pain and swelling [1,2,5,19]. Geniculate artery pseudoaneurysms are mostly treated endovascularly by stenting or coil embolization and have most often good results without remaining complaints [5,11,13,19].

Summary

Vascular injuries after TKA are extremely rare. The occurrence of a geniculate artery pseudoaneurysm and the typical delayed presentation can cause a diagnostic challenge. This case report describes a case of a pseudoaneurysm of the ILG artery following TKA in a patient with a cardiac comorbidity, using dabigatran and being bridged with LMWH. This case report focuses on the etiology,

presentation, diagnosis, and treatment of such a pseudoaneurysm and highlights the need for vigilance with respect to the diagnosis.

Conflicts of interest

The authors declare that there are no conflicts of interest.

Informed patient consent

The author(s) confirm that informed consent has been obtained from the involved patient(s) or if appropriate from the parent, guardian, power of attorney of the involved patient(s); and, they have given approval for this information to be published in this case report (series).

Funding

This research did not receive any specific grant from funding agencies in the public, commercial, or not-for-profit sectors.

Acknowledgments

The authors thank Marjolein Schager, RN, for help with English proofing.

References

- [1] Ammori M, Evans A, McLain A. Popliteal artery pseudoaneurysm after total knee arthroplasty. *J Arthroplasty* 2016;31(9):2004.
- [2] Bernhoff K, Rudström H, Gedeberg R, Björck M. Popliteal artery injury during knee replacement: a population-based nationwide study. *Bone Joint J* 2013;95-b(12):1645.
- [3] Calligaro K, Dougherty M, Ryan S, Booth R. Acute arterial complications associated with total hip and knee arthroplasty. *J Vasc Surg* 2003;38(6):1170.
- [4] Ko L, DeHart M, Yoo J, Huff T. Popliteal artery injury associated with total knee arthroplasty: trends, costs and risk factors. *J Arthroplasty* 2014;29(6):1181.
- [5] Daniels S, Sneag D, Berkowitz J, Trost D, Endo Y. Pseudoaneurysm after total knee arthroplasty: imaging findings in 7 patients. *Skeletal Radiol* 2019;48(5):699.
- [6] Parvizi J, Pulido L, Slenker N, Macgibeny M, Purtill J, Rothman R. Vascular injuries after total joint arthroplasty. *J Arthroplasty* 2008;23(8):1115.

- [7] Padegimas E, Levicoff E, McGinley A, Sharkey P, Good R. Vascular complications after total knee arthroplasty—a single institutional experience. *J Arthroplasty* 2016;31(7):1583.
- [8] Langkamer V. Local vascular complications after knee replacement: a review with illustrative case reports. *Knee* 2001;8(4):259.
- [9] Pai V. Traumatic aneurysm of the inferior lateral geniculate artery after total knee replacement. *J Arthroplasty* 1999;14(5):633.
- [10] Salaria H, Atkinson R. Anatomic study of the middle geniculate artery. *J Orthop Surg* 2008;16(1):47.
- [11] Law KY, Cheung KW, Chiu KH, Antonio GE. Pseudoaneurysm of the geniculate artery following total knee arthroplasty: a report of two cases. *Orthop Surg* 2007;15(3):386.
- [12] DeBell H, Pinter Z, Pinto M, et al. Vascular supply at risk during lateral release of the patella during total knee arthroplasty: a cadaveric study. *J Clin Orthop Trauma* 2019;10(1):107.
- [13] Julien T, Gravereaux E, Martin S. Superior medial geniculate artery pseudoaneurysm after primary total knee arthroplasty. *J Arthroplasty* 2012;27(2):323.e13.
- [14] Douketis J, Spyropoulos A, Duncan J. Perioperative management of patients with atrial fibrillation receiving a direct oral anticoagulant. *JAMA Intern Med* 2019;179(11):1469.
- [15] Spyropoulos A, Al-Badri A, Sherwood M, Douketis J. Perioperative management of patients receiving a vitamin K antagonist or a direct oral anticoagulant requiring an elective procedure or surgery. *J Thromb Haemost* 2016;14(5):875.
- [16] Douketis J, Spyropoulos A, Anderson J. The Perioperative Anticoagulant Use for Surgery Evaluation (PAUSE) study for patients on a direct oral anticoagulant who need an elective surgery or procedure: design and rationale. *Thromb Haemost* 2017;117(12):2415.
- [17] D'Souza J, Bedi V, Indrajit I, Pant R. Non surgical management of pseudoaneurysms. *Med J Armed Forces India* 2007;63(2):115.
- [18] Kindsfater K, Scott R. Recurrent hemarthrosis after total knee arthroplasty. *J Arthroplasty* 1995;10:S52.
- [19] Rukavina A, Kerkhoffs G, Schneider P, Kuster M. Recurrent hemarthrosis after total knee arthroplasty. *Knee Surg Sports Traumatol Arthrosc* 2010;18(7):898.
- [20] Sharma H, Singh GK, Cavanagh SP, Kay D. Pseudoaneurysm of the inferior medial geniculate artery following primary total knee arthroplasty: delayed presentation with recurrent haemorrhagic episodes. *Knee Surg Sports Traumatol Arthrosc* 2006;14(2):153.
- [21] Sandoval E, Ortega FJ, García-Rayó MR, Resines C. Popliteal pseudoaneurysm after total knee arthroplasty secondary to intraoperative arterial injury with a surgical pin: review of the literature. *J Arthroplasty* 2008;23(8):1239.e7.
- [22] Mahmoud M, Al-Saadi M, Abuderman A, et al. “To-and-fro” waveform in the diagnosis of arterial pseudoaneurysms. *World J Radiol* 2015;7(5):89.
- [23] Coughlin B, Paushter D. Peripheral pseudoaneurysms: evaluation with duplex US. *Radiology* 1988;168(2):339.
- [24] Gaheer RS, Chirputkar K, Sarungi M. Spontaneous resolution of superior medial geniculate artery pseudoaneurysm following total knee arthroplasty. *Knee* 2014;21(2):586.