

Received: 2020.07.15

Accepted: 2020.10.02

Available online: 2020.10.14

Published: 2020.10.21

A Case of Vaginal Malignant Melanoma Completely Resected by Radical Surgery

Authors' Contribution:
Study Design A
Data Collection B
Statistical Analysis C
Data Interpretation D
Manuscript Preparation E
Literature Search F
Funds Collection G

B 1 **Ryuichi Tokumitsu**
BE 1 **Tomoko Hirakawa**
B 1,2 **Mitsutake Yano**
E 1,3 **Evgeniya Kirakosyan**
E 1 **Shimpei Sato**
E 1,4 **Kaei Nasu**
A 1 **Hisashi Narahara**

1 Department of Obstetrics and Gynecology, Oita University Faculty of Medicine, Yufu, Oita, Japan
2 Department of Obstetrics and Gynecology, Nakatsu Municipal Hospital, Nakatsu, Oita, Japan
3 International School "Medicine of the Future", Federal State Autonomous Educational Institution of Higher Education I.M. Sechenov First Moscow State Medical University of the Ministry of Health of the Russian Federation (Sechenov University), Moscow, Russian Federation
4 Division of Obstetrics and Gynecology, Support System for Community Medicine, Oita University Faculty of Medicine, Yufu, Oita, Japan

Corresponding Author: Tomoko Hirakawa, e-mail: tomokoh@oita-u.ac.jp

Conflict of interest: None declared

Patient: Female, 56-year-old
Final Diagnosis: Malignant melanoma
Symptoms: Tumor
Medication: —
Clinical Procedure: —
Specialty: Oncology

Objective: Rare disease

Background: Primary vaginal malignant melanoma is a rare and aggressive tumor with a high risk of local recurrence and distant metastasis. Although there are several available treatment options, none are considered as standard. Surgical resection is the first treatment choice because of its superior survival benefits.

Case Report: The patient was a 56-year-old woman with a vaginal mass. At the first visit to our institution, a 20×20 mm black and flat lesion on the lower third of the posterior vaginal wall and a polypoid mass near the vaginal fornix were detected by gynecologic examination. Study of the tumor on the posterior vaginal wall suggested that it did not extend to the uterine cervix. The preoperative diagnosis was vaginal malignant melanoma FIGO stage I (cT1, cN0, cM0). The patient underwent a total vaginectomy, pelvic and inguinal lymphadenectomy, modified radical hysterectomy, and bilateral salpingo-oophorectomy. The tumor cells were arranged in sheets and nests and exhibited nuclear pleomorphism, eosinophilic cytoplasm, brisk mitotic activity, and melanin production. The overlying mucosa was ulcerated. The tumor thickness was 2.5 mm and no residual lesion was found at the surgical margin. No adjuvant therapies were performed. The patient is alive without recurrence 15 months after the initial treatment.

Conclusions: This is a case of vaginal malignant melanoma for which complete response was achieved by radical tumor resection, without severe adverse effects and with no observed recurrence 15 months after the surgery.

MeSH Keywords: Gynecologic Surgical Procedures • Melanoma • Vaginal Neoplasms

Full-text PDF: <https://www.amjcaserep.com/abstract/index/idArt/927462>



1041



2



9



Background

Malignant melanoma frequently occurs in the skin and mucous membranes, but rarely in the vagina. It accounts for about 5% of all vaginal cancers [1–3] and the median overall survival in patients with vaginal melanomas is 16 months (95% confidence interval, 14 to 18 months) [3]. Radiotherapy and chemotherapy are used as adjuvant therapies in combination with various surgical treatments, such as total vaginectomy, total hysterectomy, or inguinal and pelvic lymphadenectomy [4]. No consensus on a standard surgical technique or adjuvant therapy has been reached. We report a case of vaginal malignant melanoma for which complete response was achieved by radical resection and no recurrence has been observed. The detailed clinicopathological information of this case is reported herein, with a relevant literature review.

Case Report

A 56-year-old woman (gravida 2, para 1) presented to the clinic with a vaginal mass. A black and flat lesion on the lower third of the posterior vaginal wall and a polypoid mass near the vaginal fornix were detected by gynecologic examination. The polypoid mass biopsy results indicated malignant melanoma. Because the main site of the tumor was in the vagina and it had not extended to the uterine cervix, the patient was diagnosed with vaginal melanoma and referred to our hospital for evaluation and treatment. Her medical history included type 2 diabetes and hypertension. Her surgical history showed she had an appendectomy in her teens and an artificial abortion in her twenties. There was no family history of malignant melanoma or other cancers. At the patient's first visit to our institution, a 20×20 mm black and flat lesion was detected on the posterior vaginal wall (Figure 1A), and study of this tumor suggested that it did not extend to the uterine cervix. Vaginal ultrasonography showed no mass lesions in the uterus, adnexa,

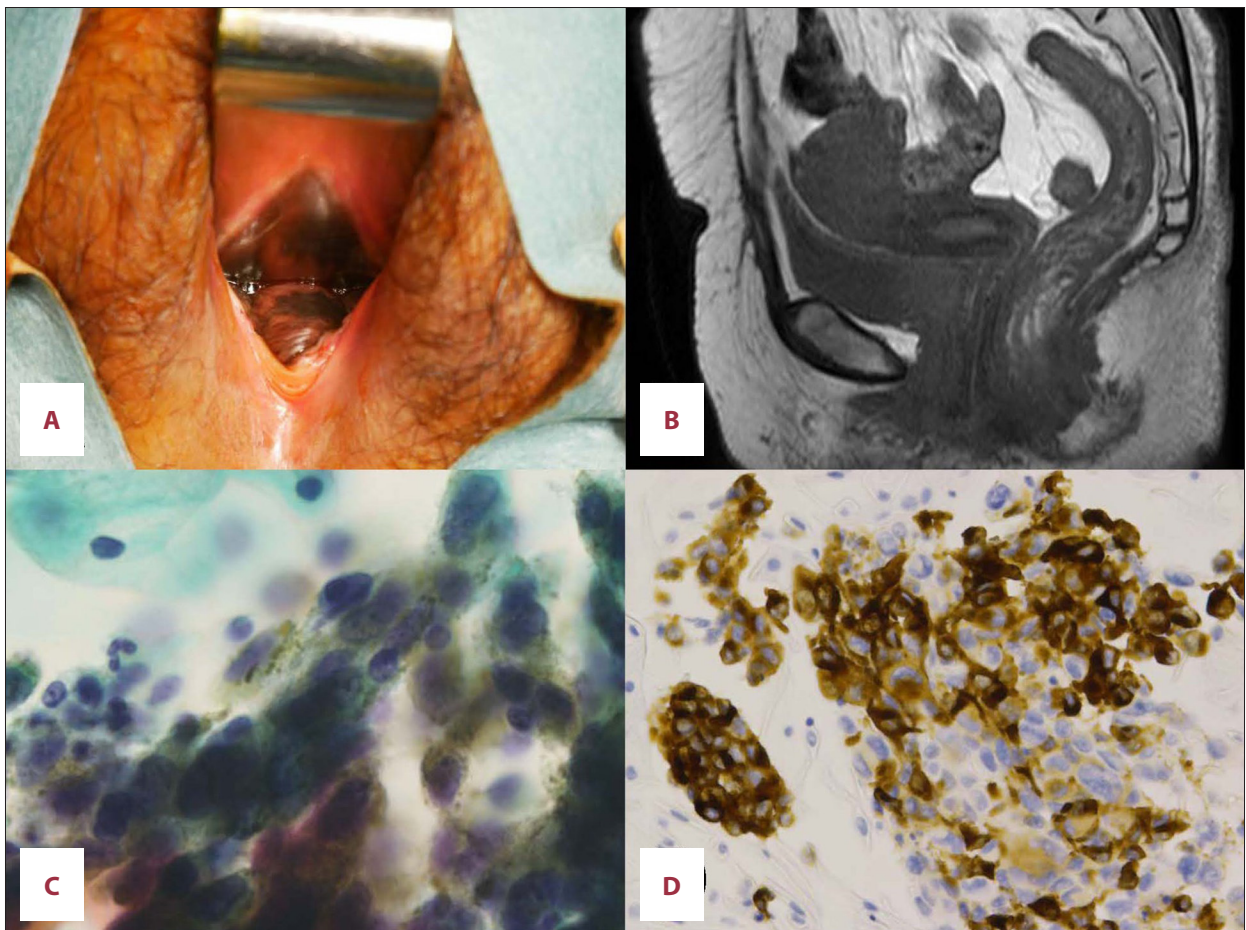


Figure 1. Preoperative examinations: (A) Internal examination showed a 20×20 mm black and flat lesion on the posterior vaginal wall. (B) T2-weighted magnetic resonance imaging revealed no vaginal or uterus cervix mass. (C) Pap ×100. Vaginal cytology showed atypical cells with nuclear pleomorphisms and melanin production. (D) Immunohistochemical staining of vaginal cytology cell blocks showed the tumor cells were positive for melanin-A.

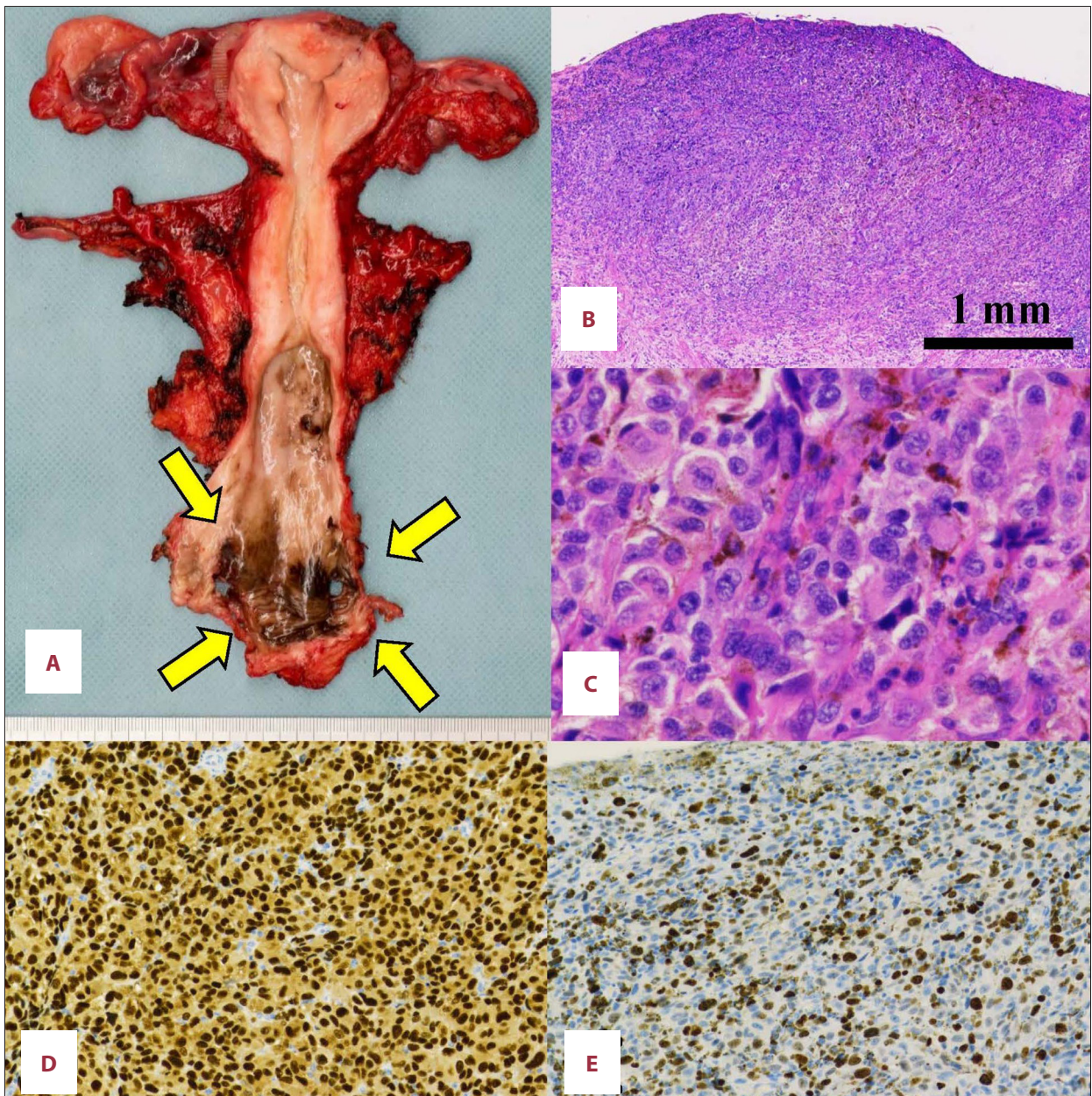


Figure 2. Postoperative examinations: (A) Macroscopically, a tumor of size 45×25 mm with a black surface was detected in the posterior vaginal wall (yellow arrows). (B) Hematoxylin and eosin ×4; and (C) Hematoxylin and eosin ×40. Microscopically, the tumor cells were arranged in sheets and nests and exhibited nuclear pleomorphism, an eosinophilic cytoplasm, brisk mitotic activity, and melanin production. Immunohistochemically, the tumor was positive for (D) SOX10 and (E) the Ki-67 labeling index was 70%.

or pelvic cavity. No vaginal or uterine cervix mass was detected by magnetic resonance imaging (Figure 1B). No metastasis was detected by enhanced computed tomography (CT) and FDG-positron emission tomography/computed tomography. The vaginal cytology and biopsy results indicated malignant melanoma (Figure 1C). Immunohistochemical staining of vaginal cytology cell blocks showed that the tumor cells were positive for S-100, HMG-45, and melan-A (Figure 1D). The preoperative diagnosis

was vaginal malignant melanoma FIGO stage I (cT1, cN0, cM0). The patient underwent a total vaginectomy, pelvic and inguinal lymphadenectomy, modified radical hysterectomy, and bilateral salpingo-oophorectomy. Macroscopically, the vagina showed a tumor sized 45×25 mm, primarily located in the posterior wall and presenting a black surface (Figure 2A). Microscopically, the tumor cells were arranged in sheets and nests and exhibited nuclear pleomorphism, eosinophilic cytoplasm, brisk mitotic

activity, and melanin production (Figure 2B, 2C). The mitotic count was 15 (mitoses/mm²). The overlying mucosa was ulcerated. The tumor thickness (Breslow thickness) was 2.5 mm and no residual lesion was found at the surgical margin. The margin was 46 mm. No metastasis to the uterus, adnexae, or resected lymph nodes was detected. Lymphovascular and perineural invasion was absent. Immunohistochemically, the tumor cells were positive for SOX10, and the Ki-67 labeling index was 70% (Figure 2D, 2E). Molecular testing was negative for BRAF V600E and V600K. No high-risk human papilloma virus infection was detected. Finally, the patient was diagnosed with vaginal malignant melanoma FIGO stage I (pT1, pN0, cM0). The results of the PD-L1 immunohistochemistry analysis were negative. No adjuvant therapies were performed. We currently perform monthly tumor marker tests, pelvic examinations by trans-rectal ultrasonography, and vulvar cytology on the patient. We perform CT examinations of the patient every 3 months. The patient is alive without recurrence 15 months after the initial treatment.

Discussion

Primary vaginal melanoma, a mucosal melanoma of the female genital tract, is a rare, aggressive tumor with a high risk of local recurrence and distant metastasis. Vaginal melanomas account for 0.3% of all melanomas in women [3]. There are several treatment options, but none of them are considered as the standard approach. Surgical resection is the first choice if the melanoma is resectable or in an early stage. The spectrum of surgical treatment ranges from conservative surgery such as wide local excision with sentinel lymph node dissection or elective lymph node dissection to total vaginectomy or radical extirpation with en bloc removal of the involved pelvic organs [5,6]. In the absence of distant metastases, lymph node involvement is the most important prognostic factor [3]. Because of the lack of prospective data, lymphadenectomy has been controversial. However, retrospective studies of vaginal malignant melanoma have been conducted [3,7]. In a study including 46 patients, 42 patients underwent surgery. Among them, 13 patients underwent lymphadenectomy and 1 patient underwent sentinel lymph node assessment [7]. In another study, which included 463 patients with vaginal malignant melanoma,

230 patients underwent surgery, of which, 128 were assessed by lymphadenectomy; 39 of these patients (30.5%) had nodal metastasis. The number of sentinel lymph node resections performed was unknown [3].

Although there are approved first-line and adjuvant therapies for melanomas [8,9], the efficacy of adjuvant therapy for vaginal melanomas is unclear [3].

The long-term prognosis of the patient in the present case is unclear, and it is still too early to determine whether the treatment used was the best possible choice. Although the surgery on this patient required a high level of skill, the procedure can be performed with a negative margin. Long-term follow-up of the patient is required. It is noteworthy that there have been no serious postoperative sequelae. Above all, it is noteworthy that we were able to achieve complete resection in this case. Although the results of the PD-L1 immunohistochemistry analysis were negative, we have a plan to administer immune checkpoint inhibitors in the event of recurrence.

Conclusions

The radical tumor resection was performed without the occurrence of severe adverse effects. We hope that an accumulation of the evidence regarding treatment methods for vaginal malignant melanoma, such as immune checkpoint inhibition, will allow the establishment of a better treatment strategy.

Acknowledgements

We would like to thank Dr. Tomomi Katoh and Prof. Masanori Yasuda, Department of Pathology, Saitama Medical University International Medical Center, for their technical support. We would like to thank Dr. Kazushi Ishikawa, Department of Dermatology, Faculty of Medicine, Oita University, for the advice on the therapy. We also thank Editage (www.editage.jp) for English language editing.

Conflict of interest

None.

References:

1. Creasman WT, Phillips JL, Menck HR: The National Cancer Data Base report on cancer of the vagina. *Cancer*, 1998; 83: 1033–40
2. Nagarajan P, Curry J, Ning L et al: Tumor thickness and mitotic rate robustly predict melanoma-specific survival in patients with primary vulvar melanoma: A retrospective review of 100 cases. *Clin Cancer Res*, 2017; 23: 2093–104
3. Wohlmuth C, Wohlmuth-Wieser I, May T et al: Malignant melanoma of the vulva and vagina: A US population-based study of 1863 patients. *Am J Clin Dermatol*, 2020; 21: 285–95
4. Xia L, Han D, Yang W et al: Primary malignant melanoma of the vagina: A retrospective clinicopathologic study of 44 cases. *Int J Gynecol Cancer*, 2014; 24: 149–55
5. Frumovitz M, Etchepareborda M, Sun CC et al: Primary malignant melanoma of the vagina. *Obstet Gynecol*, 2010; 116: 1358–65
6. Ragnarsson-Olding B, Johansson H, Rutqvist LE, Ringborg U: Malignant melanoma of the vulva and vagina. Trends in incidence, age distribution, and long-term survival among 245 consecutive cases in Sweden 1960–1984. *Cancer*, 1993; 171: 1893–97
7. Vaysse C, Pautier P, Filleron T et al: A large retrospective multicenter study of vaginal melanomas: Implications for new management. *Melanoma Res*, 2013; 23: 138–46
8. Weber J, Mandala M, Del Vecchio M et al: Adjuvant nivolumab versus ipilimumab in resected stage III or IV melanoma. *N Engl J Med*, 2017; 377: 1824–35
9. Lebbé C, Meyer N, Mortier L et al: Evaluation of two dosing regimens for nivolumab in combination with ipilimumab in patients with advanced melanoma: Results from the phase IIIb/IV CheckMate 511 Trial. *J Clin Oncol*, 2019; 11: 867–75