

The Effects of Administrated Sildenafil Citrate on Uterine Luminal Epithelium Height Associated with Ovarian Angiogenesis: An Experimental Animal Study

Abstract

Background: Ovarian angiogenesis (OA) remains in lifetime and normal ovarian function depends to this continual remodeling of a complex vascular system. Endometrial thickness (ET) is one of the strongest predictors of successful implantation and pregnancy. Appropriate OA effects on ET by facilitating of ovarian hormone delivery. **Materials and Methods:** Thirty adult female mice and twenty adult male mice were purchased. The female mice were divided into three groups: (1) control group without any intervention ($n = 10$), (2) gonadotropin group: receiving human menopausal gonadotropin (HMG) and human chorionic gonadotropin ($n = 10$), and (3) gonadotropin and sildenafil citrate (SC) group: receiving HMG and SC administration ($n = 10$). After mating, animals were deeply anesthetized, and the ovary and uterus was rapidly removed for histology and immunohistochemistry process. **Results:** Four days after ovarian induction, all three layers of the uterus with specified thickness can be clearly seen. The heights of endometrial epithelial cells in gonadotropin group were not significantly different than those in control group. In gonadotropin and SC group, heights of the cells were significantly ($P < 0.05$) shorter than control and gonadotropin groups. ETs in all groups were not significantly deferent from each other ($P > 0.05$ each). Our results of immunohistochemistry survey for ovarian CD31 demonstrated that administrated SC increased OA but not significantly ($P > 0.05$ each). **Conclusion:** It may finally conclude that administration of SC does not cause notable alterations in OA and ET; although for realistic decision about the SC effects on aforementioned parameters, more molecular investigations and longer drug consumption period are necessary.

Keywords: Endometrial thickness, ovarian angiogenesis, sildenafil citrate

Introduction

Based on the reproductive medicine sciences, infertility is defined as the inability to conceive after 12 months of unprotected sexual intercourse.^[1,2] Implantation failure is one of the well-known causes of female infertility, and endometrial thickness (ET) is one of the strongest predictors of successful implantation.^[3] A series of scientific reports have presented that embryo implantation and pregnancy rates are significantly higher in women with an ET more than 9 mm. Thin endometrium, generally measuring <7 mm, is assumed to be less able to support of implantation.^[4] ET is dependent on several factors including woman age, menstrual cycle phase, ovarian hormone (estrogen and progesterone) concentration, ovarian angiogenesis (OA), and density of hormone receptor in endometrial tissue.^[5,6]

The capacity for angiogenesis, creating of new blood vessels from preexisting ones,

is the crucial feature of endothelial cells, but the issue is open to discussion.^[7] This process occurs in both physiological and pathological conditions. Physiological angiogenesis is a key step in wound healing, tissue remodeling, luteinization of the ovarian follicle, placental development, and pregnancy establishment. In other word, physiological angiogenesis plays an important role in pregnancy and childbearing.^[8,9] In contrast, pathological angiogenesis is a known landmark of some serious disease such as cancer and associated metastasis, diabetic neuropathy, endometriosis, psoriasis, and rheumatoid arthritis.^[10,11]

Production of female germ cell and synthesis of sexual hormones and growth factors are two major functions of mammalian ovary. Unlike many other parts of the body, OA remains to before menopause, and this continual remodeling of a complex vascular

This is an open access article distributed under the terms of the Creative Commons Attribution-NonCommercial-ShareAlike 3.0 License, which allows others to remix, tweak, and build upon the work non-commercially, as long as the author is credited and the new creations are licensed under the identical terms.

For reprints contact: reprints@medknow.com

How to cite this article: Golkar MH, Saeedi Borujeni MJ, Rashidi B. The Effects of Administrated Sildenafil Citrate on Uterine Luminal Epithelium Height Associated with Ovarian Angiogenesis: An Experimental Animal Study. *Adv Biomed Res* 2017;6:164.

Received: May, 2017. **Accepted:** May, 2017.

Mohammad Hosein Golkar,
Mohammad Javad Saeedi Borujeni¹,
Bahman Rashidi¹

From the Student Research Center, School of Medicine, ¹Department of Molecular Biology and Anatomical Sciences, School of Medicine, Isfahan University of Medical Sciences, Isfahan, Iran

Address for correspondence:

Dr. Bahman Rashidi,
Department of Anatomical Sciences, School of Medicine, Isfahan University of Medical Sciences, Hezar Jerib Avenue, Isfahan, Iran.
E-mail: b_rashidi@med.mui.ac.ir

Access this article online

Website: www.advbiores.net

DOI: 10.4103/abr.abr_79_17

Quick Response Code:



system is necessary for normal ovarian function.^[12,13] This is important for increasing delivery of the gonadotropins, luteinizing hormone, follicular stimulating hormone, growth factors, oxygen, lipids, and steroid precursors required for folliculogenesis.^[14] One of the proposed factors that stimulated OA is hypoxia. In this condition, ovarian endothelial cells respond to hypoxia with increased vascular epithelial growth factor (VEGF) expression as a key signal molecule involved in angiogenesis. VEGF binds to the vascular epithelial growth factor receptor (VEGFR) that located on adjacent endothelial cells. Interaction between VEGF and VEDFR plays an important role in angiogenesis process and induced endothelial cell division, forms vessels by clustering on adjacent capillaries, and increasing hydraulic conductivity of isolated microvessels. Furthermore, VEGF stimulates the release of matrix metalloproteinase-9 for degradation of extracellular matrix and creating efficient space for new blood vessel formation.^[15-17] Finally, the newly formed endothelial cells adhere together and create tubes and loops that work as functional vascular units. Platelet endothelial cell adhesion molecule or CD31 is a new marker for the detection of angiovasculogenic activity express in endothelial cells with high levels of activity.^[18]

Sildenafil citrate (SC) or Viagra is a selective phosphodiesterase type-5 (PDE-5) inhibitor that induces vasodilation by inhibition of the cyclic guanosine monophosphate hydrolysis and increases the accessibility of the nitric oxide (NO).^[19,20] For the first time, SC developed as an antihypertensive drug, and it was noted during early trials of the drug that PDE-5 inhibition led to an increased response in subjects with erectile dysfunction.^[21] In recent years, many studies were performed for investigating the effects of SC on female fertility, for example, some studies indicated the positive role of vaginal SC administration on improved endometrial development.^[4,19,22] A clinical survey that performed by Mangal and Mehirishi presented the improving role of SC on ET, blood flow, and pregnancy rates in infertile women undergoing intrauterine insemination.^[4] Celik *et al.* in their study examined the effects of SC on ischemic and reperfusion injury in the rat ovary. The biochemical and histopathological results of their experimental study demonstrated that aforementioned injury is ameliorated by sildenafil consumption.^[23]

Due to these fact that sufficient OA effect on ET by facilitating of hormone delivery and current controversies concerning the probable effects of SC on angiogenesis of female genital system, this study aimed to analyze effects of administrated SC on OA and associated ET changes.

Materials and Methods

Study design and experimental groups

All procedures involving animals were in accordance with the Guide for the Care and Use of Laboratory Animals

of Isfahan University of Medical Sciences, Isfahan, Iran. Thirty adult Naval Medical Research Institute (NMRI) female mice (25–30 g body weight, 3 months old) and twenty adult NMRI male mice were purchased from Isfahan University of Medical Sciences Experimental Animal House (Isfahan, Iran). Animals were housed in individual cages at 22°C ± 2°C with free access to pellet food and water and on a 12 h light/dark cycle. They were fed a regular rat chow. In the present study, the female mice were divided into three groups: (1) Control group without any intervention. (2) Gonadotropin group: 7.5 IU human menopausal gonadotropin (HMG) (Ferring, Germany) was administered intraperitoneally (IP). After 2 days, 7.5 IU human chorionic gonadotropin (HCG) (Ferring, Germany) was injected IP. (3) Gonadotropin and SC group: after injection of HMG, SC administrated in 24, 48, 72 h interval (IP). Then, every two female mice with one male mouse put in one cage for mating. Four days after HMG injection, animals were deeply anesthetized with chloral hydrate (350 mg/kg),^[24] and the whole right ovary and uterus was rapidly removed for histology and immunohistochemistry process.

Histological staining

The uterus of the mice was gathered. For fixation, the samples were buffered in 10% formalin. Next, each uterus was dehydrated in graded ethanol solutions and embedded in paraffin. Horizontal serial sections with 4 µm thickness were cut. To be studied microscopically sections must typically be stained or dyed because most tissues are colorless. In the present study, histological sections stained with periodic acid-Schiff for optical microscope analyzing. Furthermore, for morphometric study, we surveyed 25 fields for each group.

Immunohistochemistry staining

To analyze OA, expression of CD31 antigen was evaluated by immunohistochemistry staining technique. For this purpose, we surveyed 25 fields for each group. Fixation of ovarian samples was done by 10% buffered formalin (Sigma, USA) for 24 h, and other steps of tissue processing were done with ascending grade of alcohol and clearness in xylene (Sigma, USA). Finally, they were embedded in paraffin, and horizontal serial sections with 4 µm thickness were cut using microtome. For immunohistochemistry staining, the slices were removed and placed on slides previously covered with poly-L-lysine in all groups. The main basis of this method is interaction of CD31 antigen with anti-CD31 antibody (AbCam, UK); then, the secondary antibody binds to the primary antibody as its antigen for the second level. Antibody-labeled and antibody complex can be exposed using the enzyme substrate. In the final step, due to the reaction of peroxidase enzyme with diaminobenzidine (DAB), DAB is utilized as a peroxidase substrate, and a dark brown product is formed.

Statistical analysis

With using of Motic Image Plus 2.0 (Motic Group Co., Ltd, Hong Cong, China), CD31-positive cell count was performed after creating the connection between computer and microscope with $\times 40$ magnifications. Statistical analysis was performed using the SPSS statistical package, version 15.0 (SPSS Inc., Chicago, IL, USA) and the Kruskal–Wallis test. $P < 0.05$ was accepted as statistically significant.

Results

Optical microscopic observation and the height of endometrial epithelial

Four days after ovarian induction, all three layers of the uterus including perimetrium, myometrium, and endometrium with specified thickness can be clearly seen. ET which contains stroma, uterine glands, and luminal epithelium is found several times in some part with just a row of epithelium and small amount of stroma. In control group, the height of endometrial epithelial cells was $20.52 \pm 2.43 \mu\text{m}$. In gonadotropin group, the heights of the cells were $20.85 \pm 2.55 \mu\text{m}$, which were not significantly different than those in control group. In gonadotropin + SC group, heights of the cells were $17.60 \pm 2.49 \mu\text{m}$, which were significantly shorter than control and gonadotropin groups ($P < 0.05$) [Figure 1a and b].

Morphometric study associated with endometrial thickness

ET defined the distance between myometrium to top of epithelial cells. Based on our morphometric survey and statistical analyzing, the mean \pm standard deviation of ET was $358.05 \pm 13.35 \mu\text{m}$ in control group, $389.84 \pm 12.46 \mu\text{m}$ in gonadotropin group, and $316.81 \pm 12.10 \mu\text{m}$ in gonadotropin + SC group. Finally, the ET in all groups was not significantly deferent from each other [$P > 0.05$ each, Figure 2a and b].

Immunohistochemistry for detection of ovarian CD31-positive cells

According to our findings, the mean of CD31-positive cells was 22 ± 3.42 in control group, 24 ± 1.48 in gonadotropin group, and 25 ± 2.09 in gonadotropin + SC group. The present data showed that angiogenesis parameter can be affected by exogenous factors such as gonadotropins and SC but not significantly ($P > 0.05$). The utilization of gonadotropins in the ovulation-stimulating process increased OA in this group in comparison with control group. In the other group, the use of gonadotropins + SC leading to increased OA when compared with gonadotropins and control group [Figure 3a and b].

Discussion

Some researchers presented the positive role of SC on ovarian function. For example, Taskin *et al.* demonstrated

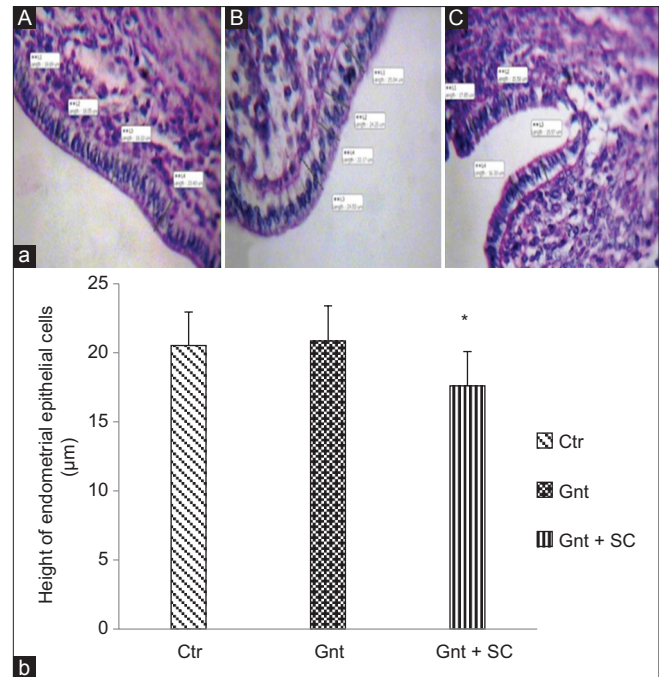


Figure 1: (a) histologic view of luminal epithelium of endometrium ($\times 660$). (A): Control group (Ctr). (B): Gonadotropin group (Gnt). (C): Gonadotropin and SC group (Gnt + SC). (b) Data are presented as means \pm standard error the heights of endometrial epithelial cells; in Gnt group, the heights of the cells were not significantly different than those in control group. In Gnt + SC group, heights of the cells were significantly ($P < 0.05$) shorter than Ctr and Gnt groups

that pretreatment with SC is useful for protecting the ovaries from cisplatin-induced damage, and this drug can be a choice for fertility preservation after chemotherapy.^[25] In another experimental animal study, Celik *et al.* examined the effects of SC on activities of antioxidant enzyme, lipid peroxidation, and histopathological characteristic of ovarian tissue after ischemia-reperfusion injury. Their results showed that aforementioned injury in the ovary was ameliorated by SC treatment.^[23] Our study demonstrated that administrated SC increased OA but not significantly. However, the precise molecular studies are needed to definitively comment.

As previously mentioned, ovarian blood vessel formation through angiogenesis is not limited to embryological period but occurs throughout mammalian life. During the blood vessel formation at adulthood, angioblasts that originated from the mesodermal layer are no longer involved. Instead, endothelial progenitor cells (EPCs) that derived from the bone marrow and circulate through the blood contribute to new blood vessel formation. The bone marrow-derived cells are thought to be enrolled by some factors involved in angiogenesis, such as VEGF and stromal-derived factor-1 (SDF-1). The interaction between VEGF and SDF-1 leads circulating EPCs to the ischemia area where they differentiate into endothelial cells and form some portion of new blood vessels. In addition, OA contributes to the remodeling of the early blood vessels that formed in before birth life.^[26,27] OA occurs largely in the cortical

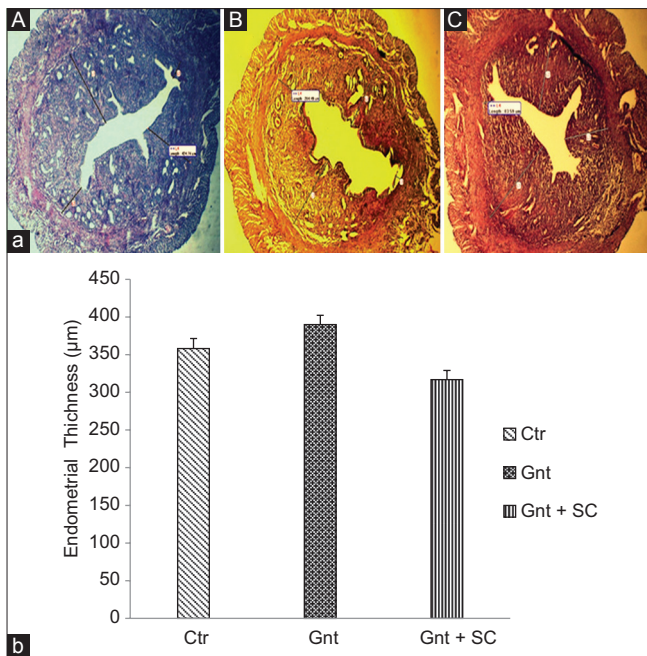


Figure 2: Results of optical microscopy and morphometric study. (a) PAS staining of mice uterus ($\times 10$), 96 h after ovarian induction of ovary. A: Endometrial thickness in control group (Ctr). B: Endometrial thickness in gonadotropin group (Gnt) C: Endometrial thickness in gonadotropin and SC group. (b) Data are presented as means \pm standard error. The endometrial thicknesses in all groups were not significantly different from each other ($P > 0.05$ each)

region because folliculogenesis and luteinization occur in this area.^[28] In our study, we investigate the presence of CD31-positive cells in the cortical region of the ovary and around the follicles.

Pregnancy complications represent a main challenge to the National Health Service. Ovarian hyperstimulation is usually used in reproductive medicine.^[29,30] Ovulation that induced by HMG offers the ability to surveys' several factors that may contribute to reproductive capacity. One of the most important points, which must be considered in selecting an appropriate animal model, is the age of animals, to reflect the same condition in human.^[31] OA is a vital event that performed in successful pregnancy. In the present study, HMG was administered IP at 0 days, HCG was injected at 2 days, and tissue sampling was done in 4 days. Based on our previous surveys that performed on pregnant mice, 96 h or 4 days after HMG injection is the best time of tissue sampling because this time is almost accordance with the time of implantation of mouse embryos but the issue is open to discussion.^[19,32]

In the present study, we used immunohistochemistry technique for detection of CD31-positive cell. Aforementioned technique is not only an accurate method for recording CD31-positive cells but also a suitable method to observe angiogenesis alteration of tissue, in other word, in immunohistochemistry; CD31 is used primarily to determine the presence of endothelial cells in histological sections.^[33] To avoid mistaken identification

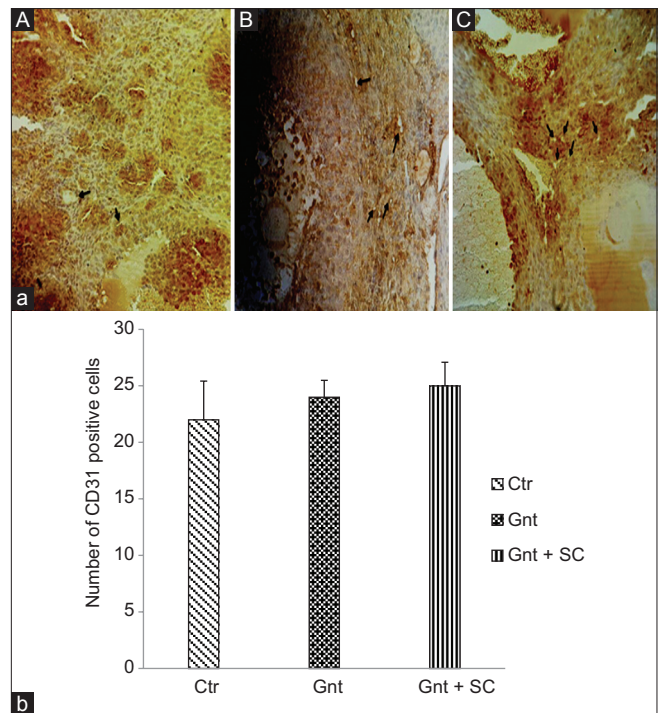


Figure 3: Results of immunohistochemistry study. (a) Immunohistochemistry staining of mice ovary for detection of CD31-positive cells ($\times 40$), 96 h after ovarian induction. A: Control group (Ctr). B: Gonadotropin group (Gnt) C: Gonadotropin and SC group. (b) Data are presented as means \pm standard error. The number of CD31-positive cells in all groups was not significantly different from each other ($P > 0.05$ each)

of CD31-positive cells, we paid special attention to some key features of these cells including; dark brown color of cells (because of reaction with DAB) and having the appearance of simple squamous cells in the inner surface of the lumen of microvasculature.

Endometrial characteristics, such as endometrial cellular pattern, endometrial blood flow, endometrial angiogenesis, and ET, have been described as key prognostic factors for successful pregnancy.^[6,34] In humans, ET can be measured by transvaginal ultrasonography.^[35] Some surveys indicated that thin endometrium is related with lower IVF (*in vitro* fertilization) success rates^[36,37] while some another studies could not approve this.^[38] In spite of all these, ET assessment has become part of routine monitoring during female infertility treatment. Some studies showed that Assisted Reproductive Technology drugs increased ET and the likelihood of pregnancy.^[39,40] Recently, the focus was on the role of NO as a relaxing factor of vascular smooth muscles and its moderating effects on blood flow of the uterus.^[41] As previously mentioned, SC is one of the interesting drugs that may be helpful for the treatment of female infertility, but the issue is open to discussion. Based on our morphometric study, the ET in all groups was not significantly different from each other and SC could not be created a significant change in histologic features of endometrium. These data are in consistent with the results of Rashidi *et al.* study (2015) that investigated

the effects of SC on Ki-67-positive stromal cells of mice endometrium.^[41] Their results indicated that SC does not cause a significant change in numbers of Ki-67-positive cells. Our results are in contrast with the results of the study done by Dehghani Firouzabadi *et al.* They examined the effects of oral use of SC on endometrial preparation and outcome of frozen-thawed embryo transfer cycles. Their results indicated that SC increased ET and is a good way to improve the endometrial receptivity.^[22]

Conclusion

Taking together, it may finally conclude that administration of SC does not cause remarkable changes in OA and associated ET; albeit for realistic decision about the effect of SC, more molecular investigations, and longer drug consumption period are necessary. SC injection alters the morphometrically features of luminal epithelium of endometrium, which could effect on its maturation.

Acknowledgment

This project was performed at the histology laboratory of the Anatomical Sciences and Molecular Biology Department of Isfahan University of Medical Sciences. The authors gratefully thank Fatemeh Amoozegar for her helpful suggestions and assistance.

Financial support and sponsorship

Grant support was provided by Isfahan University of Medical Sciences (MUI) (No. 394919).

Conflicts of interest

There are no conflicts of interest.

References

- Gnainsky Y, Granot I, Aldo PB, Barash A, Or Y, Schechtman E, *et al.* Local injury of the endometrium induces an inflammatory response that promotes successful implantation. *Fertil Steril* 2010;94:2030-6.
- Raziel A, Schachter M, Strassburger D, Bern O, Ron-El R, Friedler S. Favorable influence of local injury to the endometrium in intracytoplasmic sperm injection patients with high-order implantation failure. *Fertil Steril* 2007;87:198-201.
- Kitaya K, Matsubayashi H, Takaya Y, Nishiyama R, Yamaguchi K, Ishikawa T. Clinical background affecting pregnancy outcome following local endometrial injury in infertile patients with repeated implantation failure. *Gynecol Endocrinol* 2016;32:587-90.
- Mangal S, Mehirishi S. To study and compare the effect of vaginal sildenafil and estradiol valerate on endometrial thickness, blood flow and pregnancy rates in infertile women undergoing intrauterine insemination. *Int J Reprod Contracept Obstet Gynecol* 2017;5:2274-7.
- Zhang X, Chen CH, Confino E, Barnes R, Milad M, Kazer RR. Increased endometrial thickness is associated with improved treatment outcome for selected patients undergoing *in vitro* fertilization-embryo transfer. *Fertil Steril* 2005;83:336-40.
- Kasius A, Smit JG, Torrance HL, Eijkemans MJ, Mol BW, Opmeer BC, *et al.* Endometrial thickness and pregnancy rates after IVF: A systematic review and meta-analysis. *Hum Reprod Update* 2014;20:530-41.
- Rashidi B, Malekzadeh M, Goodarzi M, Masoudifar A, Mirzaei H. Green tea and its anti-angiogenesis effects. *Biomed Pharmacother* 2017;89:949-56.
- Rätsep M, Carmeliet P, Adams M, Croy B. Impact of placental growth factor deficiency on early mouse implant site angiogenesis. *Placenta*. 2014;35(9):772-5.
- Miller JW, Le Couter J, Strauss EC, Ferrara N. Vascular endothelial growth factor a in intraocular vascular disease. *Ophthalmology* 2013;120:106-14.
- Ramjiawan RR, Griffioen AW, Duda DG. Anti-angiogenesis for cancer revisited: Is there a role for combinations with immunotherapy? *Angiogenesis* 2017;20:185-204.
- Han JW, Choi D, Lee MY, Huh YH, Yoon YS. Bone marrow-derived mesenchymal stem cells improve diabetic neuropathy by direct modulation of both angiogenesis and myelination in peripheral nerves. *Cell Transplant* 2016;25:313-26.
- Osz K, Ross M, Petrik J. The thrombospondin-1 receptor CD36 is an important mediator of ovarian angiogenesis and folliculogenesis. *Reprod Biol Endocrinol* 2014;12:21.
- Hazzard TM, Stouffer RL. Angiogenesis in ovarian follicular and luteal development. *Baillieres Best Pract Res Clin Obstet Gynaecol* 2000;14:883-900.
- Geva E, Jaffe RB. Role of vascular endothelial growth factor in ovarian physiology and pathology. *Fertil Steril* 2000;74:429-38.
- Folkman J. Fundamental concepts of the angiogenic process. *Curr Mol Med* 2003;3:643-51.
- Lange C, Turrero Garcia M, Decimo I, Bifari F, Eelen G, Quaegebeur A, *et al.* Relief of hypoxia by angiogenesis promotes neural stem cell differentiation by targeting glycolysis. *EMBO J* 2016;35:924-41.
- Semenza GL. Cancer-stromal cell interactions mediated by hypoxia-inducible factors promote angiogenesis, lymphangiogenesis, and metastasis. *Oncogene* 2013;32:4057-63.
- Pacini S, Petrini I. Are MSCs angiogenic cells? New insights on human nestin-positive bone marrow-derived multipotent cells. *Front Cell Dev Biol* 2014;2:20.
- Rashidi B, Soleimani Rad JI, Roshangar L, Alizadeh Miran R. Evaluation of pinopodes expression on the mouse endometrium immediately before implantation by treatment with HMG/HCG and sildenafil citrate administration. *Iran J Basic Med Sci* 2012;15:1091-6.
- Kniotek M, Boguska A. Sildenafil can affect innate and adaptive immune system in both experimental animals and patients. *J Immunol Res* 2017;2017:4541958.
- Zelevsky MJ, Shasha D, Branco RD, Kollmeier M, Baser RE, Pei X, *et al.* Prophylactic sildenafil citrate improves select aspects of sexual function in men treated with radiotherapy for prostate cancer. *The Journal of urology*. 2014;192(3):868-74.
- Dehghani Firouzabadi R, Davar R, Hojjat F, Mahdavi M. Effect of sildenafil citrate on endometrial preparation and outcome of frozen-thawed embryo transfer cycles: A randomized clinical trial. *Iran J Reprod Med* 2013;11:151-8.
- Celik M, Aksoy AN, Aksoy H, Aksoy Y, Halici Z. Sildenafil reduces ischemia-reperfusion injury in rat ovary: Biochemical and histopathological evaluation. *Gynecol Obstet Invest* 2014;78:162-7.
- Saeedi Borujeni MJ, Hami J, Haghiri H, Rastin M, Sazegar G. Evaluation of Bax and Bcl-2 proteins expression in the rat hippocampus due to childhood febrile seizure. *Iran J Child Neurol* 2016;10:53-60.

25. Taskin MI, Yay A, Adali E, Balcioglu E, Inceboz U. Protective effects of sildenafil citrate administration on cisplatin-induced ovarian damage in rats. *Gynecol Endocrinol* 2015;31:272-7.
26. De Palma M, Naldini L. Role of haematopoietic cells and endothelial progenitors in tumour angiogenesis. *Biochim Biophys Acta* 2006;1766:159-66.
27. Li B, Sharpe EE, Maupin AB, Teleron AA, Pyle AL, Carmeliet P, *et al.* VEGF and PlGF promote adult vasculogenesis by enhancing EPC recruitment and vessel formation at the site of tumor neovascularization. *FASEB J* 2006;20:1495-7.
28. Fortune JE, Cushman RA, Wahl CM, Kito S. The primordial to primary follicle transition. *Mol Cell Endocrinol* 2000;163:53-60.
29. Mor YS, Schenker JG. Ovarian hyperstimulation syndrome and thrombotic events. *Am J Reprod Immunol* 2014;72:541-8.
30. Lindsay LA, Murphy CR. Ovarian hyperstimulation affects fluid transporters in the uterus: A potential mechanism in uterine receptivity. *Reprod Fertil Dev* 2014;26:982-90.
31. Sengupta P. The laboratory rat: Relating its age with human's. *Int J Prev Med* 2013;4:624-30.
32. Rashidi B, Rad JS, Roshangar L, Miran RA. Progesterone and ovarian stimulation control endometrial pinopode expression before implantation in mice. *Pathophysiology* 2012;19:131-5.
33. Deane JA, Ong YR, Cain JE, Jayasekara WS, Tiwari A, Carlone DL, *et al.* The mouse endometrium contains epithelial, endothelial and leucocyte populations expressing the stem cell marker telomerase reverse transcriptase. *Mol Hum Reprod* 2016;22:272-84.
34. Wang L, Qiao J, Li R, Zhen X, Liu Z. Role of endometrial blood flow assessment with color Doppler energy in predicting pregnancy outcome of IVF-ET cycles. *Reprod Biol Endocrinol* 2010;8:122.
35. Goldstein SR, Archer DF, Simon JA, Constantine G. Endometrial safety of ospemifene and the ability of transvaginal ultrasonography to detect small changes in endometrial thickness. *Obstet Gynecol* 2014;123:96S-7S.
36. Kovacs P, Matyas S, Boda K, Kaali SG. The effect of endometrial thickness on IVF/ICSI outcome. *Hum Reprod* 2003;18:2337-41.
37. El-Toukhy T, Coomarasamy A, Khairy M, Sunkara K, Seed P, Khalaf Y, *et al.* The relationship between endometrial thickness and outcome of medicated frozen embryo replacement cycles. *Fertil Steril* 2008;89:832-9.
38. Mercé LT, Barco MJ, Bau S, Troyano J. Are endometrial parameters by three-dimensional ultrasound and power Doppler angiography related to *in vitro* fertilization/embryo transfer outcome? *Fertil Steril* 2008;89:111-7.
39. Gonen Y, Casper RF. Prediction of implantation by the sonographic appearance of the endometrium during controlled ovarian stimulation for *in vitro* fertilization (IVF). *J Assist Reprod Genet* 1990;7:146-52.
40. Sher G, Herbert C, Maassarani G, Jacobs MH. Assessment of the late proliferative phase endometrium by ultrasonography in patients undergoing *in-vitro* fertilization and embryo transfer (IVF/ET). *Hum Reprod* 1991;6:232-7.
41. Rashidi B, Rad JS, Rad LR. Immunohistochemical (Ki-67) study of endometrial maturation in mice after use of phosphodiesterase type 5 inhibitor. *Adv Biomed Res* 2015;4:154.