

Healing effect of *Quercus persica* and *Lawsonia inermis* ointment on episiotomy wounds in primiparous women

Sanaz Zibanejad¹, Sepideh Miraj^{2,3}, Mahmoud Rafeian Kopaei⁴

¹Departments of Obstetrics and Gynecology, Shahrekord University of Medical Sciences, Shahrekord, Iran, ²Departments of Obstetrics and Gynecology, Infertility Fellowship, Shahrekord University of Medical Sciences, Shahrekord, Iran, ³Qom University of Medical Sciences, Qom, Iran, ⁴Departments of Pharmacology, Shahrekord University of Medical Sciences, Shahrekord, Iran

Background: Episiotomy is one of the most common surgical interventions performed to facilitate delivery. Anti-inflammatory and antibacterial effects of Persian oak (*Quercus persica*) and henna (*Lawsonia inermis*) have been proved in previous studies. The aim of this study is to evaluate the effect of *Q. persica* and *L. inermis* ointment on episiotomy wound healing in primiparous women and comparing it with placebo group. **Materials and Methods:** This was a double-blind clinical trial conducted on 160 primiparous women who underwent episiotomy. The cases were randomly selected and divided into four groups of forty patients including control, placebo, those who consume topical henna, and those who consume topical Persian oak ointment. Pain and recovery assessment was done at baseline and 7th, 10th, and 14th days after birth and measured by Redness, Edema, Ecchymosis, Discharge, and Approximation (REEDA scale) and patients' pain intensity was also measured by a visual analog scale (VAS). The collected data were analyzed using Chi-square test, one-way ANOVA, and repeated measures ANOVA test by SPSS (version 22). **Results:** The results revealed that according to the reduced score of REEDA till the 14th day after the delivery, the wound healing in the henna group and the oak group (-2.58 ± 0.29 and -2.04 ± 0.31 , respectively) was higher than the control and placebo groups (-1.62 ± 0.34 and -1.95 ± 0.32 , respectively) ($P < 0.05$). Furthermore, on the 14th day, the mean VAS score was not significantly different between henna and oak groups (henna group: 2.58 ± 0.25 and oak group: 2.23 ± 0.18); however, both intervention groups had a significant difference with the placebo and control groups ($P < 0.05$). **Conclusion:** The findings showed that the use of henna and oak ointment improves episiotomy wound healing process, so it is recommended for primiparous women.

Key words: Episiotomy, Lawsonia plant, primiparous women, Quercus, wound healing

How to cite this article: Zibanejad S, Miraj S, Rafeian Kopaei M. Healing effect of *Quercus persica* and *Lawsonia inermis* ointment on episiotomy wounds in primiparous women. J Res Med Sci 2020;25:11.

INTRODUCTION

Episiotomy is a surgical incision used to dilate the vaginal opening for birth. Moreover, it is one of the most common procedures during childbirth. Episiotomy was first conducted in normal deliveries in 1742.^[1,2] Although the use of episiotomy decreased between 1992 and 2003, it is still carried out in almost 33% of vaginal deliveries. By the end of the 1970s, episiotomy was applied commonly to almost all the first time mothers. There is little accurate statistics available on the prevalence of episiotomy in Iran. However, according

to many studies, the frequency of episiotomy has been reported over 80%.^[3] The most common episiotomy cases were midline or mediolateral, which facilitated the second stage of labor and spontaneous labor as well as lower use of assistive devices to improve maternal and infantile outcomes.^[1,2] One reason for episiotomy is the replacement of an incision to direct procedure with easy restoration rather than jagged tears that appeared when episiotomy was not applied.^[4]

Although episiotomy is associated with certain maternal benefits, it may lead to short- and long-term

Access this article online	
Quick Response Code: 	Website: www.jmsjournal.net
	DOI: 10.4103/jrms.JRMS_251_18

This is an open access journal, and articles are distributed under the terms of the Creative Commons Attribution-NonCommercial-ShareAlike 4.0 License, which allows others to remix, tweak, and build upon the work non-commercially, as long as appropriate credit is given and the new creations are licensed under the identical terms.

For reprints contact: reprints@medknow.com

Address for correspondence: Prof. Sepideh Miraj, Departments of Obstetrics and Gynecology, Infertility Fellowship, Shahrekord University of Medical Sciences, and Qom University of Medical Sciences, Iran. E-mail: s.miraj@skums.ac.ir

Submitted: 06-Aug-2019; **Revised:** 11-Oct-2019; **Accepted:** 25-Dec-2019; **Published:** 20-Feb-2020

disability after birth. The complications of episiotomy can be perineal pain, inflammation, edema, dyspareunia, bleeding, infection, abscess, hematoma, sphincter damage and anal mucosa, wound dehiscence, and rupture spread.^[4,5] Furthermore, fatigue, insomnia, problems in seating and hugging children, decreased sexual function, and emotional relationship between mother and child are the additional complications.^[5,6]

On the other hand, the maternal fear of vaginal birth, especially during pregnancy and postpartum perineal pain, prolapse and altered anatomy of the perineum, and the involuntary responses in labor, prompts selective cesarean delivery.^[7] In this regard, several measures have been proposed to alleviate the perineum and wound healing: for instance, regularly washing the perineum and practicing perineal hygiene, keeping the wound dry, applying Savlon and salt in the water, using dry heat by radiation from infrared lamps, hot and cold sitting baths, doing Kegel exercises, and applying pads made of plant extracts such as lavender, chamomile, turmeric, oak, and evergreen.^[7-9]

Henna or *Lawsonia inermis* is a stable perennial *Myrtaceae* shrub from the *Lythraceae* family. The henna leaves contain a substance called lawsone with the chemical name of 2-hydroxy-1, which has antioxidant properties leading to hemolysis.^[9]

In traditional medicine, henna was topically applied to treat joint pain, rash, and ulcers as well as skin and hair dyeing.^[10] Henna has antibacterial effect, particularly on Gram-positive bacteria. It also has antifungal effects on *Trichophyton* tinea fungus *Trichophyton*, *Sporotrichum*, and *Cryptococcus*. The antibacterial and antifungal effects of henna are attributed to lawsone.^[11]

Another traditional herb is oak which is also known by the name of *Quercus persica*.^[12] Different parts of this plant have many therapeutic applications. Polyphenols and tannins are the main substances found in oak which make it useful for the treatment of multiple bleeding, stomach ulcers, dysentery, hemorrhoids, tonsillitis, and laryngitis. Its skin is used as an antidote for poisoning by alkaloids. Moreover, the oak bark decoction is useful for chronic skin diseases, eczema, and varices.^[13]

On the one hand, because episiotomy has physiological, psychological, and socioeconomic effects on women, it is crucial not only having the qualified technique but also the proper following treatment. On the other hand, the long history of herbal medicine and increased concerns of pharmacologists and researchers have once again promoted the use of such substances. Moreover, the previous studies on

henna and oak have proven the pain-relieving, antimicrobial, and anti-inflammatory properties of them.^[14-17] However, a few studies have evaluated their effects on episiotomy wound of which women often complain after natural childbirth. Hence, this study aimed to focus on the healing effect of Persian oak and henna ointment on episiotomy wound in primiparous women admitted to Hajar Hospital, Shahrekord, Iran, during 2014–2015.

MATERIALS AND METHODS

Study design and participants

This double-blind clinical trial was conducted on all the referred primiparous women admitted to Hajar Hospital in Shahrekord (Iran) for normal vaginal delivery during 2014–2015. From them, 160 ones were selected by simple random method. The sample size was calculated using sample size formula taking into account the 95% confidence level, 80% statistical power, the proportion of natural labor in the mentioned hospital which approximately estimated as 71%, and the error level of 0.1.

The inclusion criteria were primiparous, maternal age range of 18–40 years, gestational age of 37–42 weeks, single fetus, nonuse of certain drugs (immunosuppressive, chemotherapy, radiation therapy, and glucocorticoid), no history of conditions interfering with coagulation in chronic disease (such as, pulmonary diseases, cardiovascular diseases, and kidney dysfunction) or coagulation and tissue disorders, diabetes, lack of mental disease, constipation, anemia, psychological disorders, malnutrition, no sensitivity to herbal medicines, body mass index (BMI) between 19.8 and 26, no history of active skin diseases such as allergic disorders associated with lesions or marked vaginitis, and no history of previous contact dermatitis to topical herbal agents. The exclusion criteria were history of surgical repair on the perineum, cephalopelvic disproportion in pelvic examination, prolonged and precipitated labor, manual removal of placenta, Grade 3 and 4 perineal tears, prolonged rupture of membrane (more than 18 h), use of vacuum and forceps, risk of postpartum hemorrhage, a history of genital warts, no regular use of ointment (<7 days or <14 times), and confounding variables such as antibiotics.

Ointment preparation

Persian oak fruit with scientific name of *Q. persica* and henna named *L. inermis* were purchased from Shahrekord's medicinal plant market. A botanical expert of Shahrekord's Herb Medicine Laboratory confirmed their identity. Herbarium samples were recorded with the codes of 426 and 503, respectively, in the herbarium of medicinal plant research center of Shahrekord University of Medical Sciences. It was kept away from sunlight and in a dry and cool until it was extracted.

The seeds of Persian oak were dried inside for 1 week at room temperature ($30^{\circ}\text{C} \pm 5^{\circ}\text{C}$) and were grounded to fine powder using the Moulinex food processor. The hydroalcoholic extract was obtained by maceration of the crude plant powder with ethanol/distilled water (70/30) for 3 days in a temperature chamber (20°C – 25°C) in the dark. After 72 h, the mixture was soaked using the Buchner funnel and Whatman filter paper Grade 1 and the resulting solution was collected in a balloon. Then, alcohol was poured and refined on the remaining material so that a colorless solution was obtained. The solutions were concentrated using a rotary evaporator at 38°C and 60 rpm and then placed in an incubator at 37°C . After 72 h, the extracts were dried and cleaned out of special containers; they were kept in separate containers in a refrigerator at 4°C . After several experiments, Eucerin was diagnosed to be an appropriate base of ointment and the extract was weighted properly and dissolved in polyethylene glyceryl oleate. Then, isopropyl palmitate, cetyl alcohol, ARA-cell[®] 165, and paraffin were mixed together and heat in Bain-Marie 70° to warm up. Then, the dissolved extract was added to it. It is worthy to note that both the ointments were prepared in a same color. Tween 85 was dissolved in water and reached 70°C in Bin Mary. The watery part was added to the fatty part and stirred up to reaching a temperature of 30° . The rate of extract in oak ointment was 5% and in henna was 2%. The placebo was prepared in the same way, but without extracts. Then, they were packed in 30 g tubes.

Intervention

This research project was approved scientifically by the Research Committee of Isfahan University of Medical Sciences and ethically by the ethics committee of the university (Ethic code: 921023). Furthermore, it was registered in the Iranian registration system with IRCT2015060122521N1 before starting participant recruitment.

The eligible subjects filled the consent form and were randomly divided into four groups of control (no intervention) and placebo cream (received Eucerin or cream base) and two consumer groups for 2% oak ointment and 5% henna ointment through randomized block design (40 blocks with size of 4 to compose four groups of 40) [Figure 1]. Sequentially numbered, opaque, sealed envelopes of the same shape and size with the codes of A, B, C, and D were distributed to the subjects. The packages and allocation sequence were prepared by a person who was not involved in the recruitment in hospital drugstore, data collection, and data analysis. Therefore, the investigators and participants were unaware of the type of ointment given to every participant (double-blinding) unless the one who prepare the ointment in laboratory.

Prenatal care, delivery, and episiotomy repair were conducted by the researcher. The mothers in the delivery unit received the essential training on how to take care of

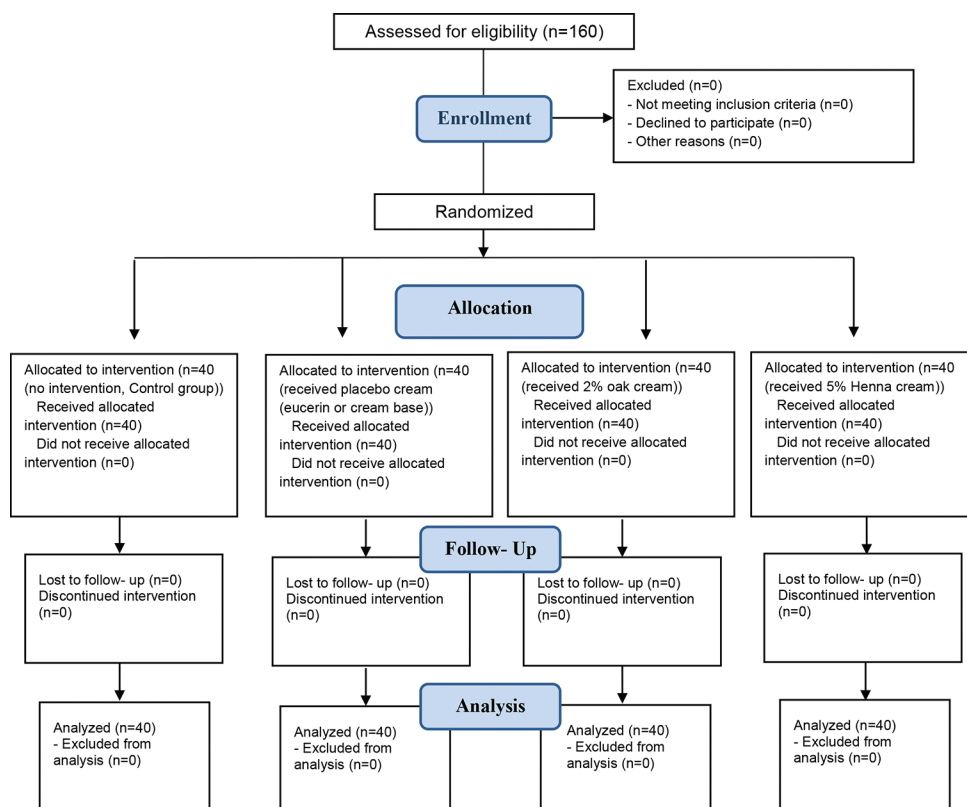


Figure 1: Consort chart

the perineum and sutures, personal hygiene, nutrition, and physical activities, and encoded packages were given to subjects. To this end, after washing the hands and perineum thoroughly and dry them with a clean cloth, the ointment would be applied to the size of a knuckle on the suture. The patient was requested to use a hygiene pad after 1–2 min and continue the use of pad twice daily for the first 10 days. It should be mentioned that in case of discharge, the wound sample was cultured quickly and suitable antibiotics were prescribed. In case of any irritation and dermatitis sign, we asked the patient to stop the topical agent instantly.

We asked them to try to take the given capsules for pain relief only if needed. Moreover, they were asked to return to the hospital at 7th, 10th, and 14th days after delivery for a reassessment and to deliver the empty tubes of the drugs.

Outcome measures

At the beginning of the study, the sociodemographic information of participants (such as age, place of residence, BMI, and education level) was recorded. The episiotomy wound healing score was also evaluated by the Redness, Edema, Ecchymosis, Discharge, and Approximation (REEDA) scale checklist during the baseline (before the intervention) and 7th, 10th, and 14th days after ointment use.^[17] Each item is ranked from 0 to 3. The total score from 0 to 15 determines the overall healing score: a higher score indicates poor wound healing whereas a lower score shows a higher wound healing. Alvarenga *et al.*^[18] in a study investigated the status of episiotomy wound healing by the researcher and the evaluator with a kappa agreement coefficient and confirmed the reliability of this tool over 70%.

Patients' pain intensity was also measured by a visual analog scale (VAS) at the mentioned times. The tool is a

10 cm line which patients had been asked to mark a point over this line from 0 to 10, of which 0 is the absence of pain and 10 is the highest.

Statistical analysis

Finally, the collected data were entered into SPSS (version 22; SPSS Inc., Chicago, IL, USA) and were represented by frequency (percentage) or mean \pm standard deviation. In the analytical statistics level, one-way ANOVA was used to compare the mean of quantitative variables between the four groups followed by Duncan *post hoc* test. Furthermore, repeated measures ANOVA was used to assess the effect of time and intervention on the quantitative variables during 14 days after the intervention. Also, Chi-square test was used to compare the frequency distribution of qualitative data among the four groups. In all analyses, the significance level was considered <0.05 .

RESULTS

This study included 160 primiparous women in four groups of 40 including the control, placebo, oak, and henna. The four groups were matched in terms of factors such as age, BMI, educational level, employment status, economical status, and place of residency with no significant difference between the four groups ($P > 0.05$) [Table 1].

The results of comparing the mean score of REEDA for the evaluation of wound healing trend among the four groups revealed that there was no significant difference among the four groups in terms of the REEDA score at the beginning of the study ($P > 0.5$). However, by the time of day 10, the mean of REEDA score in the oak group and henna group was 0.67 ± 0.13 and 0.72 ± 0.15 , respectively, which was significantly lower than that of the

Table 1: Frequency and descriptive statistics for nulliparous women in four groups

Factors	Control	Placebo	Henna	Oak	P
Age (year)	24.65 \pm 3.13	24.63 \pm 3.71	23.60 \pm 4.15	20.82 \pm 4.92	0.082
BMI	24.85 \pm 3.99	25.86 \pm 5.26	24.34 \pm 3.83	25.15 \pm 5.52	0.563
Educational level (%)					
Primary school	2 (5)	3 (7.5)	1 (2.5)	3 (7.5)	0.140
Guidance school	12 (30)	2 (5)	8 (20)	4 (10)	
High school and diploma	17 (42.5)	18 (45)	15 (37.5)	19 (47.5)	
University	9 (22.5)	17 (42.5)	16 (40)	2 (5)	
Job (%)					
Clerk	4 (10)	4 (10)	4 (10)	3 (7.5)	0.753
Housewife	36 (90)	36 (90)	33 (82.5)	36 (90)	
Economic status (%)					
Weak	2 (5)	5 (12.5)	6 (15)	5 (12.5)	0.522
Moderate	32 (80)	24 (60)	23 (60.5)	24 (60)	
Good	6 (15)	10 (25.6)	9 (23.7)	6 (15)	
Address (%)					
City	23 (57.5)	28 (70)	19 (47.5)	16 (41)	0.054
Village	17 (42.5)	12 (30)	21 (52.5)	23 (57.5)	

BMI=Body mass index

placebo and control groups with the mean of 1.85 ± 0.25 and 1.40 ± 0.21 , respectively ($P < 0.05$). Moreover, on the 14th day, the mean of REEDA score in the oak group and henna groups was 0.23 ± 0.07 and 0.23 ± 0.08 , respectively, which was significantly lower than that of the placebo and control groups with the mean of 0.95 ± 0.21 and 1.03 ± 0.17 , respectively ($P < 0.05$).

Furthermore, according to the REEDA score within 14 days, there was a significant difference among the four groups in terms of wound healing ($P < 0.05$). Although the oak group with the mean difference of -2.04 ± 0.31 and henna group with the mean difference of -2.58 ± 0.29 did not differ significantly ($P > 0.05$), they indicated higher decreased scores as compared to the control group with the mean difference of -1.62 ± 0.34 and placebo group with the mean difference of -1.95 ± 0.32 ($P < 0.05$).

In addition, repeated measures ANOVA revealed that the main effect of intervention ($F = 4.578$; $P = 0.004$) and the main effect of time point ($F = 143.834$; $P < 0.001$) on REEDA scale were significant. Time point \times group interactions were also significant for this scale ($F = 2.381$; $P = 0.012$), so that at the 14 days after intervention, the two intervention groups had the higher mean than noninterventional groups [Table 2].

A more detailed review of each component of the REEDA scale according to the repeated measures ANOVA showed that the main effect of time was significant in all dimensions of REEDA. In addition, the time point \times group interactions were significant in the edema, discharge, and approximation dimensions ($P < 0.05$). No ecchymosis was seen in any of the patients. Furthermore, the two intervention groups had higher improvement rate compared to noninterventional groups (placebo and control) [Table 3].

Finally, the VAS scores of the four groups did not differ significantly at the beginning of the study ($P > 0.05$); however, there was a significant decrease in the VAS scores of the all four groups within 14 days ($F = 287.243$;

$P < 0.001$), and the effect of time point \times group interactions was also significant ($F = 49.027$; $P < 0.001$). So that on the 14th day, there was no significant difference between the henna and oak groups with the mean score of 2.58 ± 0.25 and 2.23 ± 0.18 , respectively; however, they indicated a significant difference with the placebo group with the mean score of 5.53 ± 0.45 and the control group with the mean score of 7.80 ± 0.15 ($P < 0.05$) [Table 4].

DISCUSSION

Episiotomy incision is restored normally without confounding factors such as infection during 3 weeks after delivery.^[19] The complications of episiotomy include painful intercourse, infection, bleeding, and need for repair surgery.^[19]

The current study aimed at examining the effect of henna and Persian oak ointment on improvement of episiotomy wound healing and suggested that the use of herbal remedies such as henna and oak can heal the wound in more than 80% of cases. The findings revealed that gradually at the end of study, i.e., after 14 days, all of the four groups indicated an acceptable improvement. However, the observed improvement was obvious in the intervention groups after 7 days, whereas the improvement occurred slower and was seen after 10 days in the placebo and control groups. In addition, comparing the mean of improvement rates in four groups indicated that improved wound (REEDA total score) in both intervention groups was relatively more than that of the placebo and control groups ($P < 0.05$). However, there was no difference between not only the henna and Persian oak groups ($P > 0.05$) but also the placebo and control groups ($P > 0.05$). However, a more detailed investigation of the components in REEDA scale suggested that the improvement of redness, edema, and approximation in both intervention groups was significant at 14th day ($P > 0.05$), whereas no significant improvement was seen in terms of edema and discharge in placebo and control groups ($P > 0.05$). The latter groups

Table 2: Comparison wound healing score (Redness, Edema, Ecchymosis, Discharge, and Approximation scale, 0-15) between the study groups at different time points

Variables	Day	Control	Placebo	Henna	Oak	P*
REEDA score	Baseline	2.67 ± 0.33^a	3.02 ± 0.32^a	2.85 ± 0.25^a	2.35 ± 0.22^a	0.388
	7 th	1.80 ± 0.25^{ab}	2.45 ± 0.29^a	1.85 ± 0.22^{ab}	1.50 ± 0.17^b	0.042
	10 th	1.40 ± 0.21^a	1.85 ± 0.25^a	0.72 ± 0.15^b	0.67 ± 0.13^b	<0.001
	14 th	1.03 ± 0.17^a	0.95 ± 0.21^a	0.23 ± 0.08^b	0.23 ± 0.07^b	<0.001
Mean difference [†]		-1.62 ± 0.34^a	-1.95 ± 0.32^a	-2.58 ± 0.29^b	-2.04 ± 0.31^b	0.025
P**						Time effect: $F = 143.834$, $P < 0.001$ Intervention effect: $F = 4.578$, $P = 0.004$ interaction time and intervention: $F = 2.381$, $P = 0.012$

[†]The mean of the wound healing from the Baseline until the 14th day after intervention with adjusting the variables of age and BMI, *One-way ANOVA was used for comparison between the four groups and *post hoc* Duncan test was used to compare the two groups, as the similar letters of a and b indicate no difference and nonsimilar letters indicate a significant difference, **Repeated measures ANOVA was used for comparison over time. REEDA=Redness, Edema, Ecchymosis, Discharge, and Approximation; BMI=Body mass index

Table 3: Comparison components of Redness, Edema, Ecchymosis, Discharge, and Approximation scale score between the study groups at different time points

Variables	Day	Control	Placebo	Henna	Oak	P*
Redness	Baseline	0.88±0.17 ^a	1.02±0.17 ^a	0.78±0.16 ^a	0.75±0.15 ^a	0.634
	7 th	0.48±0.11 ^a	0.60±0.09 ^a	0.38±0.08 ^a	0.38±0.09 ^a	0.273
	10 th	0.25±0.08 ^a	0.28±0.07 ^a	0.13±0.06 ^a	0.13±0.05 ^a	0.269
	14 th	0.25±0.09 ^a	0.08±0.04 ^b	0.05±0.3 ^b	0.03±0.02 ^b	0.012
<i>P**</i>		Time effect: $F=85.130, P<0.001$ Intervention effect: $F=1.170, P=0.323$ Interaction time and intervention: $F=0.729, P=0.682$				
Edema	Baseline	0 ^a	0.03±0.02 ^a	0.08±0.04 ^a	0.03±0.02 ^a	0.274
	7 th	0 ^a	0.08±0.05 ^a	0.08±0.04 ^a	0.1±0.06 ^a	0.448
	10 th	0 ^a	0.15±0.08 ^a	0.03±0.02 ^b	0 ^b	0.020
	14 th	0	0	0	0	-
<i>P**</i>		Time effect: $F=3.408, P=0.018$ Intervention effect: $F=1.402, P=0.244$ Interaction time and intervention: $F=2.165, P=0.023$				
Ecchymosis	Baseline	0	0	0	0	-
	7 th	0	0	0	0	-
	10 th	0	0	0	0	-
	14 th	0	0	0	0	-
<i>P**</i>		Time effect: - Intervention effect: - Interaction time and intervention: -				
Discharge	Baseline	0.84±0.08 ^a	0.55±0.08 ^a	0.70±0.07 ^a	0.65±0.10 ^a	0.246
	7 th	0.83±0.11 ^a	0.95±0.10 ^a	1±0.06 ^a	0.98±0.10 ^a	0.574
	10 th	0.80±0.14 ^a	0.85±0.09 ^a	0.45±0.08 ^b	0.50±0.09 ^b	0.011
	14 th	0.65±0.13 ^a	0.80±0.20 ^a	0.18±0.06 ^b	0.20±0.06 ^b	0.001
<i>P**</i>		Time effect: $F=23.516, P<0.001$ Intervention effect: $F=1.717, P=0.166$ Interaction time and intervention: $F=5.678, P<0.001$				
Approximation	Baseline	1.33±0.18 ^a	1.43±0.19 ^a	1.30±0.15 ^a	0.93±0.11 ^a	0.160
	7 th	0.50±0.99 ^{ab}	0.83±0.17 ^a	0.43±0.16 ^{ab}	0.10±0.06 ^b	0.007
	10 th	0.35±0.10 ^{ab}	0.58±0.12 ^a	0.13±0.06 ^{bc}	0.05±0.03 ^c	0.017
	14 th	0.13±0.05 ^a	0.08±0.03 ^{ab}	0 ^b	0 ^b	0.021
<i>P**</i>		Time effect: $F=150.032, P<0.001$ Intervention effect: $F=4.076, P=0.008$ Interaction time and intervention: $F=2.265, P=0.017$				

*One-way ANOVA was used for comparison between the four groups and *post hoc* Duncan test was used to compare the two groups, as the similar letters of a, b and c indicate no difference and non-similar letters indicate a significant difference, **Repeated measures ANOVA was used for comparison over time

Table 4: Comparison the visual analog scale score (0-10) status between the study groups at different time points

Day	Control group	Placebo	Henna	Oak	P*
Baseline	8.93±0.16 ^a	8.50±0.21 ^a	8.40±0.17 ^a	8.45±0.14 ^a	0.141
7 th	9.33±0.09 ^a	7.75±0.30 ^b	7.33±0.24 ^b	7.18±0.27 ^b	<0.001
10 th	8.50±0.08 ^a	6.88±0.36 ^a	5.10±0.27 ^b	4.78±0.23 ^b	<0.001
14 th	7.80±0.15 ^a	5.53±0.45 ^b	2.58±0.25 ^c	2.23±0.18 ^c	<0.001
<i>P**</i>		Time effect: $F=287.243, P<0.001$ Intervention effect: $F=38.801, P<0.001$ Interaction time and intervention: $F=49.027, P<0.001$			

*One-way ANOVA was used for comparison between the four groups and *post hoc* Duncan test was used to compare the two groups, as the similar letters of a and b indicate no difference and nonsimilar letters indicate a significant difference, **Repeated measures ANOVA was used for comparison over time

revealed significant improvements in terms of other symptoms ($P < 0.05$).

In relevant literature, there is not a similar study on henna and oak's effects on episiotomy healing. However, there

are studies providing the impact of henna on improving of the other wound types. For example, henna extract reduced the mean diameter of cutaneous wound and significantly improved the healing up to 12 days.^[11,20] As stated above, some studies confirmed the impact of henna on the other types of the wounds, which is consistent with the current study, arguing that the antibiotic and anti-inflammatory properties of henna are generally effective in wound healing.

Several studies also examined the effects of other types of medicinal plants on episiotomy wound healing. For example, wound secretion, severity of erythema, edema, and bruising wound substantially improved after taking turmeric or lavender ointment by the 14th day, so that healing was promoted during 5–10 days.^[5,21,22]

Persian oak has been recognized in some studies as a powerful antioxidant.^[23] Hemmati *et al.* suggested that the

Persian oak ointment can increase the angiogenesis phase as well as reepithelialization and the process of wound healing in adult male albino rats.^[24] There is some evidence that Persian oak ointment can accelerate angiogenesis. The antimicrobial, antioxidant, and inflammatory effects in most of the plant extracts can help wound healing.^[25] Previous studies have mentioned the similar effects of oak plant extract on animal samples (rats),^[26] in which a considerable amount of biologically active compounds have been found.^[27]

In addition, in line with the findings of the present study, there are studies providing the impact of henna on the improvement of other wound types such as lesions caused by cutaneous leishmaniasis and excremental wounds caused by surgery. The mentioned property of henna can be attributed to its antibiotic and anti-inflammatory properties. Contrary to the current study, some previous literature has reported that there is no significant difference between the restoration of episiotomy wound in primiparous women with singleton pregnancy by topical lidocaine and placebo^[28] or chamomile essential oils and placebo.^[29] It should be noted that although different types of medicinal plants have been used in the current study, all the chamomiles, oak and henna, have antibacterial and antimicrobial properties, which are some of the factors that could be effectively inconsistent with other studies, i.e., wound infection,^[30] size and type of episiotomy incision, and suturing procedure.

The status of pain intensity indicated that reduction in pain intensity between the four groups was evident upon the 7th day, so that the level of pain in the control group was maximum whereas it was minimum in the oak group ($P < 0.05$). Moreover, the pain reduction in the oak group was greater than the henna group, but the difference was not significant between the two groups ($P > 0.05$). In other words, it can be argued that the impact of these two ointments was identical in pain reduction. However, the pain intensity in all four groups was curtailed over time by the 14th day ($P < 0.05$).

According to the analgesic properties and relaxation therapies, especially herbal remedies, it seems that if natural childbirth is pleasant for mothers through different methods used for pain relief, there would be lower desire for cesarean delivery. Studies in Iran show that the most common reason behind cesarean delivery is the fear of episiotomy pain,^[21,22] where information is mostly heard from relatives and friends.^[28] Hence, making the childbirth a pleasant experience would reduce the fear of vaginal delivery.

Therefore, according to the results of the current study and other studies, the authors believe that use of some

herbs (including oak and henna) can be effective as an additive therapy to improve episiotomy and to alleviate pains. Thus, to ensure the correctness of these results, more studies are required to clarify the mechanism by which oak and henna heal the wound and to compare these products with available products in this regard.

Finally, the limitations of this study are the lack of contribution and patient's desire to attend the study and impossibility of accurate examination of episiotomy wound healing through biopsy on clean sutures in humans. Although we tried to control the diet, health and physical exercise which can be effective on wound healing by providing the same trainings and randomized assignment of individuals, the impossibility of complete control on these issues was as some other limitations. In contrast, this study on primiparous women and 14 days of follow-up without any sample size loss can be considered as one of the greatest strengths of this study.

CONCLUSION

The findings of this study showed that episiotomy wound healed after 14 days in each of the four groups, but the wound healing was accelerated in the treatment groups with henna and oak ointment in comparison with the control and placebo. Furthermore, the wound healing and pain reduction in the oak treatment group was slightly greater than the henna treatment group, whereas the two plants were assessed to leave similar impacts.

Acknowledgments

I also place on record, my sense of gratitude to one and all, which directly or indirectly, have lent, their hands in this venture. We would also like to show our gratitude to the mothers who cooperated in this study.

Financial support and sponsorship

Nil.

Conflicts of interest

There are no conflicts of interest.

REFERENCES

- Hajhashemi M, Ghanbari Z, Movahedi M, Rafieian M, Keivani A, Haghollahi F. The effect of *Achillea millefolium* and *Hypericum perforatum* ointments on episiotomy wound healing in primiparous women. *J Matern Fetal Neonatal Med* 2018;31:63-9.
- Safavi M, Honarmand A, Yazdanpanah A. Adding metoclopramide to lidocaine for intravenous regional anesthesia in trauma patients. *Adv Biomed Res* 2014;3:45.
- Navabi Rigi S, Abedian Z, Poorjavad M, Smaeli H. Comparing the effect of cooling jell pads and ice pack, after episiotomy on the intensity of perineal pain. *Tabibe Shargh J* 2007;9:27-36.
- Nager CW, Helliwell JP. Episiotomy increases perineal

- laceration length in primiparous women. *Am J Obstet Gynecol* 2001;185:444-50.
5. Khadivzadeh T, Molkizadeh M, Rakhshandeh M. Evaluation of lavender cream effect on episiotomy pain and wound healing in primiparous women. *Int J Gyn Obst* 2009;107:498-99.
 6. Miraj S. A review study of therapeutic effects of *Peganum harmala*. *Der Pharmacia Lettre* 2016;8:161-66.
 7. Seyyedi F, Rafiean-Kopaei M, Miraj S. Comparison of the effects of vaginal royal jelly and vaginal estrogen on quality of life, sexual and urinary function in postmenopausal women. *J Clin Diagn Res* 2016;10:QC01-5.
 8. Miraj S. *Helianthus annuus*: A systematic review of pharmacological activity. *Der Pharma Chemica* 2016;8:73-6.
 9. Kok AN, Avci B. Henna (*Lawsonia inermis* Linn) induced hemolytic anemia in siblings. *Int J ClinPrac* 2004;58:502-30.
 10. Pirbalouti A. Medicinal plants used in Chaharmahal and Bakhtyari districts of Iran. *Herba Polonica* 2009;55:69-77.
 11. Bafghi FA, Mosadegh MH, Fallahzadeh H. Effectiveness of *Lawsonia inermis* extract on cutaneous leishmaniasis lesion in BALB/c mice. *J Kerman Univ Med Sci* 2008;15:329-35.
 12. Kandel ER, Schwartz JH, Jessell TM, Siegelbaum SA, Hudspeth AJ. *Principles of Neural Science*. New York: McGraw-Hill; 2000.
 13. Portenoy RK. Tolerance to opioid analgesics: Clinical aspects. *Cancer Surv* 1994;21:49-65.
 14. Miraj S, Alesaeidi S. A systematic review study of therapeutic effects of *Matricaria recuitta* chamomile (chamomile). *Electron Physician* 2016;8:3024-31.
 15. Khosravi AD, Behzadi A. Comparison of the antibacterial activity of the seed hull of *Quercus brantii* on some gram negative enteric bacilli with some in-use antibiotics. *Arak Med Univ J AMUJ* 2002;5:1-6.
 16. Ebrahimi A, Khayami M, Nejati V. Evaluation of the antibacterial activity of quercus persica jaub and spach fruit's hidroalcoholic extract in disc diffusion method. *J Med Plants* 2010;1:26-3.
 17. Pakniat H, Bahman A, Movahed F, Mohammadi N. Effects of topical phenytoin cream on episiotomy repair in primiparous women: A double blind clinical trial. *Iran J Pharm Res* 2018;17:1563-70.
 18. Alvarenga MB, Francisco AA, de Oliveira SM, da Silva FM, Shimoda GT, Damiani LP. Episiotomy healing assessment: Redness, Edema, Ecchymosis, Discharge, Approximation (REEDA) scale reliability. *Rev Lat Am Enfermagem* 2015;23:162-8.
 19. Cunningham F, Leveno K, Bloom S, Spong CY, Dashe J. Williams Obstetrics. 24th ed. United States: McGraw-Hill; 2014.
 20. Moezzi N, Varzi HN, Shirali S. Comparing the effect of *Elaeagnus angustifolia* L. extract and *Lowsonia inermis* L. paste, with silver sulfadiazine ointment on wound healing in rat. *Iran J Med Aromat Plants* 2009;25:253-60.
 21. Golmakani N, Refaie Saeidi SH, Mazlum R, Soltani B. Evaluation of the perineal trauma level in primiparous women with routine and selective episiotomy. *Iran J Obs Gyn Inf* 2008;11:39-46.
 22. Vakilian K, Atarha M, Bekhradi R, Chaman R. Healing advantages of lavender essential oil during episiotomy recovery: A clinical trial. *Complement Ther Clin Pract* 2011;17:50-3.
 23. Hemmati AA, Houshmand G, Ghorbanzadeh B, Nemati M, Behmanesh MA. Topical Vitamin K1 promotes repair of full thickness wound in rat. *Indian J Pharmacol* 2014;46:409-12.
 24. Hemmati AA, Houshmand GH, Nemati M, Bahadoram, Nozar Dorestan M, Rashidi-Nooshabadi MR, *et al.* Wound healing effects of Persian Oak (*Quercus brantii*) ointment in rats. *Jundishapur J Nat Pharm Prod* 2015;10:E25508.
 25. Navarro A, De las Heras B, Villar A. Anti-inflammatory and immunomodulating properties of a sterol fraction from sideritis foetens clem. *Biol Pharm Bull* 2001;24:470-3.
 26. Nayak BS, Anderson M, Pinto Pereira LM. Evaluation of wound-healing potential of *Catharanthus roseus* leaf extract in rats. *Fitoterapia* 2007;78:540-4.
 27. Oh H, Kim DH, Cho JH, Kim YC. Hepatoprotective and free radical scavenging activities of phenolic petrosins and flavonoids isolated from *Equisetum arvense*. *J Ethnopharmacol* 2004;95:421-4.
 28. Fardiazar Z, Zahery F, Sadegy Khamene S, Mohammad Alizade S, Kooshavar H. The efficacy of 2% lidocaine gel in healing the episiotomy and relieving its pain during postpartum. *J Ardabil Univ Med Sci* 2006;6:61-6.
 29. Pazandeh F, Savadzadeh SH, Mojab F, Alavi Majd H. The effect of chamomile essence on episiotomy repair in primiparous women. *J Ardebil Univ Med Sci* 2008;4:364-70.
 30. Murray SS, McKinney ES. *Foundations of Maternal-Newborn and Women's Health Nursing-E-Book*. Amsterdam, Netherlands: Elsevier Health Sciences; 2014.