

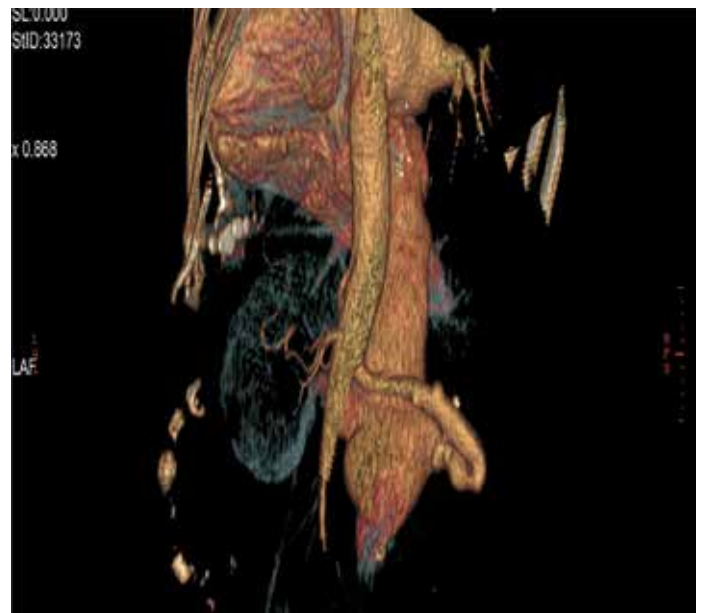

Figure 1. Posterior view: Three-dimensional reconstruction of right AVF communicating with the overdilated IVC

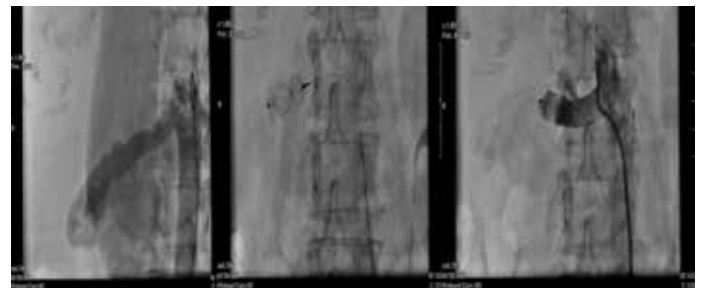


Figure 2. Right renal AVF shown by nonselective angiography (from right to left). Deployment of AVP II into the right renal artery. Successful closure of the right renal AVF

can cause high preload and congestive heart failure. We aimed to highlight the great importance of physical examination by which a proper diagnosis of AVF and successful treatment can be achieved, thus leading to full recovery.

Case Report

A 64-year-old female patient was admitted to our clinic with dyspnea. She had a 4-year history of dyspnea and visited medical centers with no satisfaction. Her past history included right nephrectomy due to renal calculi 33 years ago.

On admission, she presented with tachypnea, normal blood pressure, and no fever. Her low oxygen saturation increased to 95% with oxygen supply. She had sinus rhythm with 90 bpm and no pathologic signs. Jugular distention was noticed. Fine rales were heard in the basal area of the lungs. Ascites and hepatomegaly with a lower board 2 cm below the costa were noted. Lower extremities showed edema. Interestingly, a murmur was

Worth listening to the kidney: An uncommon cause of congestive heart failure 🎧

Elton Soydan, Mustafa Akın
Department of Cardiology, Faculty of Medicine, Ege University;
İzmir-Turkey

Introduction

Renal arteriovenous fistulas (AVFs) are rare communications between the arterial and venous systems. Increased blood flow

heard in the right periumbilical region of the abdomen. The murmur was high-pitched and continuous with no change in position. Chest X-ray showed blunted costophrenic sinuses. No infective or tumoral infiltration was seen. Echocardiographic findings were normal. Abdominal Doppler ultrasonography showed a communication between the right renal artery and the inferior vena cava (IVC). Computed tomography showed a dilated (11 mm) right renal artery with a fistula draining into the IVC (Fig. 1). After stabilization of heart failure symptoms with diuretics, peripheral angiography confirmed a renal AVF (Fig. 2, Video 1). According to the anatomical compatibility of the right renal artery and after consultation with the vascular surgery department, percutaneous closure with Amplatzer vascular plug (AVP) II was decided as the next step. AVP II of 12×9 mm in dimension was delivered percutaneously via the transfemoral approach and implanted into the proximal region of the right renal artery. Selective right renal artery angiography showed occlusion of the flow through the renal artery and IVC (Fig. 2, Video 2). Heart failure signs and symptoms dramatically resolved and the patient was discharged healthy.

Discussion

In clinical practice, we have seen that abdominal auscultation is not regularly performed in heart failure patients because of profound ascites, discomfort, or orthopnea. This case highlights the importance of a thorough physical examination. By listening to the kidney, we were able to make a proper diagnosis and save the patient from this very rare malformation of renal AVF, which has a prevalence of <0.04% (1). Renal AVFs are classified into congenital, idiopathic, and acquired. Acquired ones represent the majority of cases. One of the causes is prior abdominal surgery (1). The pathophysiologic mechanism lies in the shear stress exerted by the blunt-end ligated right renal artery with an irregular dilation. Although no exact mechanisms, chronic shear stress is thought to be an important trigger in the erosion of the venous vessel wall, thus leading to the development of renal AVF (2). Presentation and diagnosis is occasionally achieved late, generally 40 years after nephrectomy (3). Common manifestations include abdominal bruit (90%–100%), hypertension, and congestive heart failure (30%–40%) (1). Therefore, it is very important to auscultate the abdomen and pay attention to a history of nephrectomy when heart failure of unknown origin is encountered. Angiography remains the gold standard for AVF diagnosis (1). Renal AVF can cause congestive heart failure due to their high output flow and should be treated as soon as possible (4). Endovascular embolization is considered the first-line treatment because of its high success rate with lower morbidity and mortality compared with surgery (3). The use

of coils is associated a risk of embolization and low success rate of occlusion; therefore, we decided to use the AVP II, as it offers a more accurate and stable placement through a detachable system and can be safely used in high-flow, short vascular segments, such as renal AVF. The device is usually oversized by 30% of the size target vessel, which allows more stability and less risk of migration (5).

Conclusion

Acquired renal AVF should be included in the differential diagnosis of congestive heart failure of unknown origin. Percutaneous closure should be the first-line treatment in renal AVF with compatible anatomy.

References

1. Abdel-Aal AK, Elsabbagh A, Soliman H, Hamed M, Underwood E, Saddekni S. Percutaneous embolization of a postnephrectomy arteriovenous fistula with intervening pseudoaneurysm using the Amplatzer vascular plug 2. *Vasc Endovascular Surg* 2014; 48: 516-21.
2. Kayser O, Schäfer P. Transcatheter Amplatzer vascular plug-embolization of a giant postnephrectomy arteriovenous fistula combined with an aneurysm of the renal pedicle by through-and-through, arteriovenous access. *Ger Med Sci* 2013; 11: Doc01.
3. Garg N, Kalra M, Friese JL, McKusick MA, Bjarnason H, Bower TC, et al. Contemporary management of giant renal and visceral arteriovenous fistulae. *J Endovasc Ther* 2011; 18: 811-8.
4. Khawaja AT, McLean GK, Srinivasan V. Successful intervention for high-output cardiac failure caused by massive renal arteriovenous fistula-a case report. *Angiology* 2004; 55: 205-8.
5. Resnick S, Chiang A. Transcatheter embolization of a high-flow renal arteriovenous fistula with use of a constrained wallstent to prevent coil migration. *J Vasc Interv Radiol* 2006; 17: 363-7.

Video 1. Peripheral angiography confirming right renal arteriovenous fistula draining into the overdilated inferior vena cava.

Video 2. Effective occlusion of the right renal artery flow by Adequate anchoring of the Amplatzer vascular plug II.

This study was presented as an oral presentation at the 33rd Turkish Cardiology Congress on October 6, 2017.

Address for Correspondence: Dr. Elton Soydan,
Ege Üniversitesi Tıp Fakültesi,
Kardiyoloji Anabilim Dalı,
İzmir-Türkiye
Phone: +90 232 390 49 15
E-mail: eltonsoydan@hotmail.com

©Copyright 2018 by Turkish Society of Cardiology - Available online at www.anatoljcardiol.com

DOI:10.14744/AnatolJCardiol.2018.06982

