

# Conforming with current regulation in Turkey regarding the freezing of oocytes: A case report of the first pregnancy in Turkey achieved through oocyte vitrification

SAGE Open Medical Case Reports  
Volume 5: 1–5  
© The Author(s) 2017  
Reprints and permissions:  
sagepub.co.uk/journalsPermissions.nav  
DOI: 10.1177/2050313X16687917  
journals.sagepub.com/home/sco



Prof. Semra Kahraman<sup>1</sup>, MD, Assoc. Prof. Kahraman Ulker<sup>1</sup>, MD, Caroline Pirkevi Çetinkaya<sup>1</sup>, PhD, Yesim Kumtepe Colakoglu<sup>1</sup>, MSc, Hakan K. Yelke<sup>1</sup>, MSc and Cihangir Yilanlioglu<sup>2</sup>, MD

## Abstract

**Objectives:** To present the first pregnancy achieved in Turkey with frozen–warmed oocytes in a case with previous nine unsuccessful assisted reproductive technology (ART) attempts.

**Methods:** The clinical follow-up of a 33-year-old female applying to our ART centre after a long and complicated history of infertility is described.

**Results:** In April 2013, the woman attempted our centre for her 10th ART trial. She informed us on oocyte pick-up (OPU) day that her husband had been hospitalized following a car crash in Albania and was unable to travel to our clinic to give a sperm sample. We were therefore placed in the position of having to make an emergency decision. OPU was done and seven oocytes were retrieved. Six metaphase II (MII) oocytes out of seven Cumulus Oocyte Complexes (COCs) were vitrified using the Kitazato Vitrification Cryotop Kit. Six months later, in November 2013, the patient applied for transfer. Two blastocysts were transferred and the ART trial resulted with a singleton pregnancy and the birth of a healthy new-born at term via cesarean section.

**Conclusion:** Regulation Codes on Assisted Reproductive Procedures and Assisted Reproductive Technology Centres, published in the Official Gazette of the Republic of Turkey, on 6 March 2010 forbade the freezing of gonad cells and tissues except when essential for medical reasons and stated that this would be specified later. However, the Regulation Codes published in the Official Gazette of the Republic of Turkey, on 30 September 2014 provided no further clarification. Unfortunately, the wording of the regulations did not specifically address this unexpected emergency situation. However, we saw our decision to cryopreserve the oocytes as a valid interpretation of the regulations, bearing in mind also the requirement that sperm and oocyte in the IVF process must be those of a married couple. Turkish medicolegal regulations should be revised to increase the chances of more women taking advantage of the procedure to preserve their reproductive autonomy and to give guidance on what action may be taken in emergency situations.

## Keywords

Women's health, obstetrics/gynaecology, oocyte vitrification, pregnancy, Turkish legislation

Date Received: 27 September 2016; accepted: 13 December 2016

## Case presentation

A 33-year-old Albanian woman applied to our clinic, Istanbul Memorial Hospital Assisted Reproductive Technology (ART) and Genetics Centre, after a long and complicated history of infertility. Patient history is summarized in Table 1.

In April 2013, the woman attempted our centre for her 10th ART trial and she was prepared for oocyte pick-up (OPU). The baseline oestradiol, luteinizing hormone (LH), and progesterone levels were evaluated on cycle Day 2, and

<sup>1</sup>Assisted Reproductive Technologies and Reproductive Genetics Centre, Istanbul Memorial Hospital, Istanbul, Turkey

<sup>2</sup>Department of Obstetrics and Gynecology, Istanbul Memorial Hospital, Istanbul, Turkey

### Corresponding Author:

Caroline Pirkevi Çetinkaya, Assisted Reproductive Technologies and Reproductive Genetics Centre, Istanbul Memorial Hospital, Piyale Pasa Bulvarı, Okmeydanı Sisli, Istanbul 34385, Turkey.  
Email: carolinepirkevi@yahoo.com



**Table 1.** Patient's history.

She had three spontaneous pregnancies	>>	Two of them were induced abortion with dilatation and curettage and one miscarriage (2005–2006)
Two ART trials in Albania	>>	Biochemical pregnancy at first trial. No pregnancy in the second trial (2007)
Ovarian cyst	>>	Laparoscopic cystectomy (2008)
Spontaneous tubal twin pregnancy	>>	Salpingostomy via laparotomy (2008)
ART trial in another centre in Turkey	>>	No pregnancy (2009)
Diagnostic laparoscopy after a failed ART trial (Albania)	>>	Left salpingectomy. Right tube obstructed (2010)
New ART trial in Albania resulting in six embryos >> three embryos were transferred to the patient and the remaining three embryos were transferred to a prospective surrogate mother	>>	No pregnancy resulted (2010)
Diagnostic hysteroscopy in Istanbul Memorial Hospital	>>	Normal findings (2011)
ART trial in our centre	>>	Repeated negative pregnancy tests in Albania resulting in a right tubal ectopic pregnancy, laparoscopic partial right salpingectomy in Albania (2011)
Right tubal pyosalpingitis 1 month after the operation in Albania	>>	Laparoscopic right total salpingectomy in Albania. Consequently, absolute tubal factor (2011)
Pelvic inflammatory disease in Albania	>>	She recovered following 1-week hospitalization (2011)
Two ART trials in Albania (one of them with donor oocytes)	>>	No pregnancy (2011)
ART trial in our centre	>>	No pregnancy (2012)
New ART trial resulting in pick-up of seven oocytes, six of which were mature	>>	Her husband had a traffic accident in Albania and was unable to give sperm for intracytoplasmic sperm injection. Therefore, all of the available oocytes were frozen (2013)
ART trial with the insemination of thawed oocytes	>>	First-term pregnancy resulting in healthy birth (2014)

ART: assisted reproductive technology.

baseline ultrasound scans were performed on the same day. Recombinant follicle-stimulating hormone (rFSH) (Gonal-F®; Merck Serono, Switzerland) was used for ovarian stimulation at a dosage of 225 IU daily. From the fifth day of rFSH therapy onwards, patient was monitored daily or every other day for hormone levels (oestradiol, LH, and progesterone when-ever needed) and follicular measurements. The stimulation protocol was as outlined previously.<sup>1,2</sup> A daily administration of 0.25 mg GnRH antagonist (Cetrotide®; Merck Serono) was started when the follicle reached 12–13 mm in size. Follicular maturation was achieved using 250 µg recombinant human chorionic gonadotropin (hCG) (Ovitrelle®; Merck Serono) when at least three follicles reached a minimum mean diameter of 17 mm. Transvaginal ultrasound-guided oocyte retrieval was scheduled after 36 h. However, she informed us on OPU day that her husband had been hospitalized following a car crash in Albania and was unable to travel to our clinic to give a sperm sample. We were therefore placed in the position of having to make an emergency decision. OPU was done, and seven oocytes were retrieved. Six metaphase II (MII) oocytes out of seven cumulus-enclosed oocyte complexes (COCs) were vitrified using the Kitazato Vitrification Cryotop Kit (Kitazato, Japan) according to the manufacturer's instructions.<sup>3–7</sup>

After 6 months, in November 2013, the patient applied for transfer. Written informed consent was obtained from husband and wife before thawing the frozen oocytes to be used for intracytoplasmic sperm injection (ICSI) procedure. Her endometrium was prepared with 2 mg oestradiol valerate

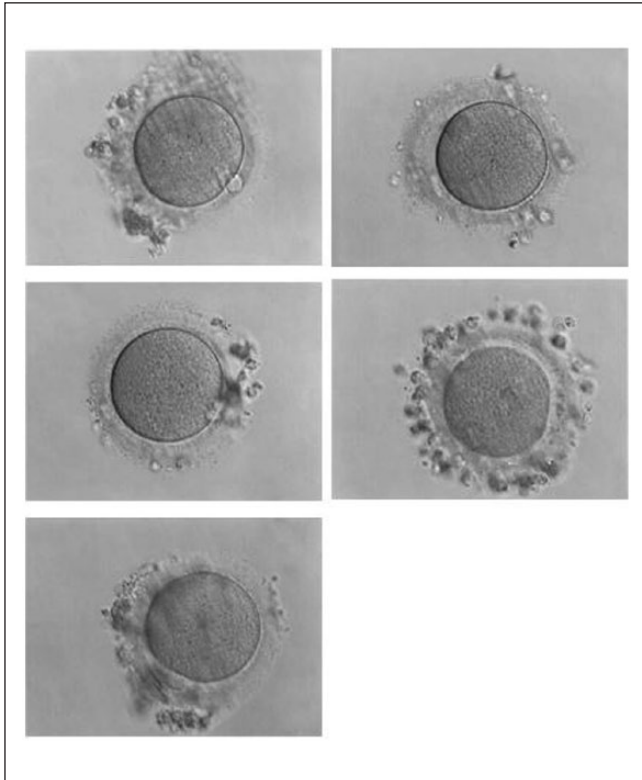
three times per day (total dose: 6 mg). On Day 14 of the cycle, the endometrial thickness was 11 mm and the frozen oocytes were thawed according to the manufacturer's instructions of the Kitazato Thawing Kit (Kitazato). Warmed oocytes were incubated for 2 h, and five surviving oocytes with normal morphology (Figure 1) were injected with the husband's fresh sperm. Figure 2 shows five frozen-thawed MII oocytes analysed by polarized microscopy before ICSI.

Of the developed four zygotes, three were classified as good quality embryos on Day 3. The embryos were monitored using a time-lapse incubator (EmbryoScope™ time-lapse system; Vitrolife, Sweden). Figure 3 shows the timeline of the five thawed oocytes incubated in EmbryoScope until Day 4 (oocyte nos 2 and 3 were further transferred).

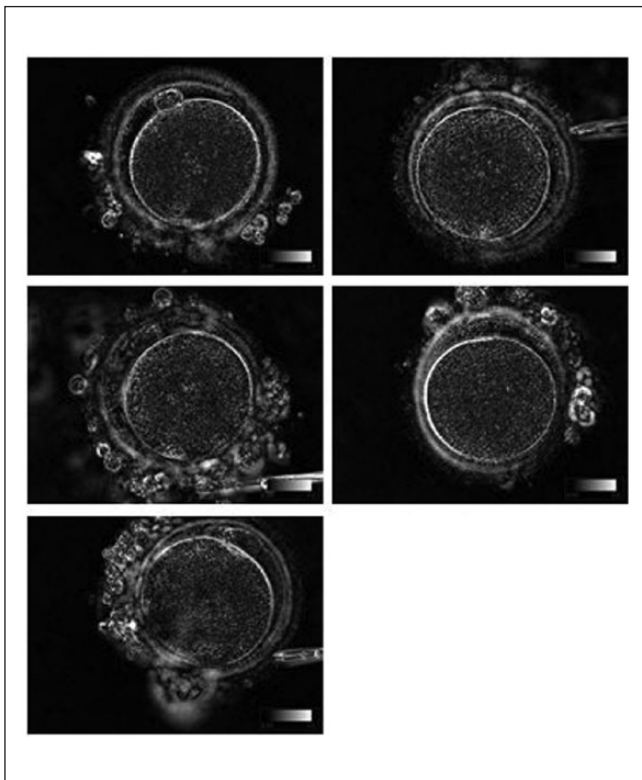
On Day 5, two blastocysts (4BB and 2AA) were transferred (Figure 4). Luteal phase was supported with progesterone 8% gel (Crinone® 8%; Merck Serono) twice daily starting on the 14th day of the cycle. The ART trial resulted with a singleton pregnancy and the birth of a healthy newborn at term via caesarean section.

## Discussion


To our knowledge, this is the first successful birth after a pregnancy achieved using vitrified-warm oocytes in Turkey. The story of our couple includes complex aspects of infertility including ovarian cyst, pelvic infection, induced abortion, missed abortion, dilatation and curettage, laparoscopy, laparotomy, OPU, oocyte vitrification, embryo transfer and



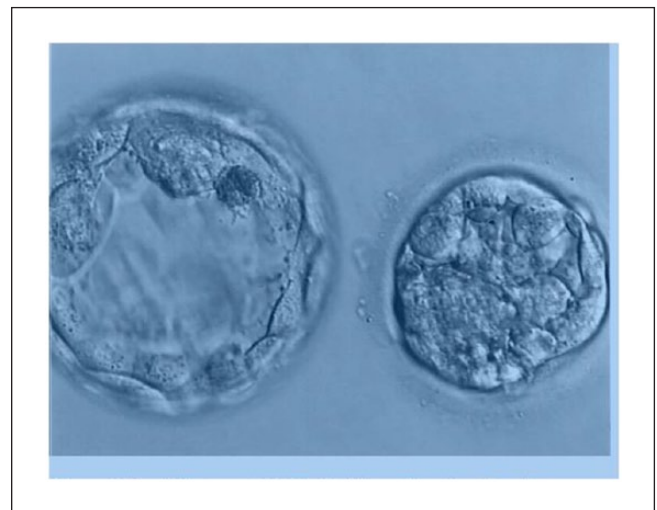**Figure 1.** Photos of the five MII oocytes obtained from the patients on her 10th IVF.



**Figure 2.** Five frozen-thawed MII oocytes were analysed by polarized microscopy before ICSI.



**Figure 3.** Timeline of the five thawed oocytes incubated in Embryoscope until Day 4 (oocyte nos 2 and 3 were further transferred).



**Figure 4.** Two blastocysts (4BB and 2AA) transferred on Day 5.

obligatory travels abroad, an accident, a crucial decision for future fertility, and finally successful pregnancy at the 10th ART attempt. Moreover, it illustrates the difficulty of making decisions in 2013 in an emergency situation while conforming to regulations which seemed open to interpretation.

Regulation Codes on Assisted Reproductive Procedures and ART Centres,<sup>8</sup> published in the *Official Gazette of the*

Republic of Turkey no. 27513, on 6 March 2010, forbade the freezing of gonad cells and tissues except when essential for medical reasons and stated that this would be specified at a later date. Regulation Codes on Assisted Reproductive Procedures and ART Centres,<sup>9</sup> published in the *Official Gazette of the Republic of Turkey* no. 29135, on 30 September 2014, provided no further clarification.

To return to the case in question, on the day of OPU, the patient informed us that her husband had been hospitalized following a car crash in Albania and was unable to travel to our clinic to give sperm sample. We were therefore placed in the position of having to make an emergency decision. Should we allow the patient to lose this chance of a pregnancy at her 10th ART attempt by allowing spontaneous ovulation and loss of her eggs or should we allow her the chance of a future pregnancy by freezing the eggs. Unfortunately, the wording of the regulations did not specifically address this unexpected emergency situation. We saw our decision to cryopreserve the oocytes as a valid interpretation of the regulations, bearing in mind also the requirement that sperm and oocyte in the in vitro fertilization (IVF) process must be those of a married couple.

In 2014, a Committee on Gynaecologic Practice Opinion from the American College of Obstetricians (ACOG) and Gynaecologists supported the 2013 joint document of the American Society for Reproductive Medicine and the Society for Reproductive Technology and suggested that oocyte vitrification would no longer be considered experimental.<sup>10</sup>

In Turkey, regulations on oocyte cryopreservation have similarities with the ACOG Committee Opinion and they are included in the 'Regulation Codes on Assisted Reproductive Procedures and ART Centres'<sup>9</sup> redesigned in 2014 by the Turkish Ministry of Health.

According to the code, the cryopreservation of oocytes or ovarian tissues is permitted only in the following medical circumstances as documented by a panel of three specialist doctors: prior to treatments such as chemotherapy or radiotherapy which may damage reproductive cells; prior to surgery such as the removal of the ovaries which may result in the loss of reproductive functions; in cases of low ovarian reserve where the woman is childless or there is a family history of early menopause.

In cases where the immediate need for essential oocyte cryopreservation arises, regulations do not sufficiently describe the options. For example, as in the case of our patient, a difficulty may arise when a married couple has undergone preparation for ART but an unexpected social/personal or medical event intervenes at a critical point, resulting in uncertainty over whether or not oocytes may or may not be frozen for use at an appropriate future time. Our patient, despite a very complex and complicated medical history, gave birth to a healthy child at the 10th ART attempt. If her oocytes had not been frozen, she would have lost the chance of a pregnancy resulting from this cycle. It is therefore extremely important that regulations should be amended to describe emergency situations.

Regulation codes in Turkey allow oocyte vitrification in cases where medical and/or surgical procedures jeopardize

the existence of female reproductive cells and in single women with a family history of early menopause or diminished ovarian reserve. However, it is not clear whether married women with similar conditions may also benefit from the regulation. As an example, can married women with diminished ovarian reserve and wishing to postpone pregnancy use the oocyte cryopreservation option? It is well known that there is a close correlation between female age, a higher number of obtained oocytes, the successful freezing of oocytes, and higher chances of pregnancy.<sup>6,7</sup> Therefore, why should not women with high ovarian reserve be offered oocyte vitrification in order to allow for better clinical outcomes in the future. The limitation of the freezing of oocytes to cases of low ovarian reserve, where outcomes are much less likely to be successful, should be reconsidered.

In conclusion, using vitrified/thawed oocytes has comparable clinical outcomes with using fresh oocytes in ART. However, Turkish medicolegal regulations should be revised to increase the chances of more women taking advantage of the procedure to preserve their reproductive autonomy and to give guidance on what action may be taken in emergency situations.

### Declaration of conflicting interests

The author(s) declared no potential conflicts of interest with respect to the research, authorship and/or publication of this article.

### Ethical approval

Our institution does not require ethical approval for reporting individual cases or case series.

### Funding

The author(s) received no financial support for the research, authorship and/or publication of this article.

### Informed consent

Written informed consent was obtained from the patient(s) for their anonymized information to be published in this article.

### References

1. Kahraman S, Kumtepe Y, Sertyel S, et al. Pronuclear morphology scoring and chromosomal status of embryos in severe male infertility. *Hum Reprod* 2002; 12: 3193–3200.
2. Kahraman S, Karlikaya G, Sertyel S, et al. Clinical aspects of preimplantation genetic diagnosis for single gene disorders combined with HLA typing. *Reprod Biomed Online* 2004; 5: 529–532.
3. Cobo A, Kuwayama M, Pérez S, et al. Comparison of concomitant outcome achieved with fresh and cryopreserved donor oocytes vitrified by the Cryotop method. *Fertil Steril* 2008; 89: 1657–1664.
4. Cobo A, Vajta G and Remohí J. Vitrification of human mature oocytes in clinical practice. *Reprod Biomed Online* 2009; 19(Suppl. 4): 4385.
5. Cobo A, Meseguer M, Remohí J, et al. Use of cryo-banked oocytes in an ovum donation programme: a prospective,

- randomized, controlled, clinical trial. *Hum Reprod* 2010; 25: 2239–2246.
6. Rienzi L, Romano S, Albricci L, et al. Embryo development of fresh ‘versus’ vitrified metaphase II oocytes after ICSI: a prospective randomized sibling-oocyte study. *Hum Reprod* 2010; 25: 66–73.
  7. Rienzi L, Cobo A, Paffoni A, et al. Consistent and predictable delivery rates after oocyte vitrification: an observational longitudinal cohort multicentric study. *Hum Reprod* 2012; 27: 1606–1612.
  8. Regulation Codes on Assisted Reproductive Procedures and Assisted Reproductive Technology Centers (no. 27513). *Official Gazette of the Republic of Turkey*, 2010.
  9. Regulation Codes on Assisted Reproductive Procedures and Assisted Reproductive Technology Centers (no. 29135). *Official Gazette of the Republic of Turkey*, 2014.
  10. Practice Committees of American Society for Reproductive Medicine and the Society for Assisted Reproductive Technology. Mature oocyte cryopreservation: a guideline. *Fertil Steril* 2013; 99: 37–43.