

## Outcome of large angle exotropia treated by single stage adjustable strabismus surgery with monitored conscious anesthesia

Fasna Asafali, Muralidhar Rajamani, Chidambaram Periannan, Sekar Michael, Ramamurthy Dandapani

**Purpose:** To evaluate the outcomes of large-angle exotropia by single-stage adjustable strabismus surgery (SSASS) under monitored conscious anesthesia. **Methods:** A prospective study was done in 33 patients above 14 years with  $\geq 40$  prism diopters (PD) of exotropia. All patients underwent SSASS under monitored conscious anesthesia (topical anesthesia plus intravenous sedation). For deviations of  $\leq 55$  PD, two horizontal rectus muscles, and for  $> 55$  PD, three rectus muscles were operated and a decision on adjustment/operating on an additional rectus muscle was taken after assessing the alignment. Monitored conscious anesthesia allowed us to check our results after surgery and plan further surgery/adjustment to achieve the desired alignment. **Results:** Mean preoperative deviation for distance was  $52 \pm 11.1$  PD. The target alignment was achieved with the initial surgical plan in 10/21 patients with  $< 55$  PD exotropia and 4/12 patients with  $> 55$  PD exotropia, and one patient in each group needed adjustment. The remaining patients needed additional rectus muscle surgery. One patient with  $> 55$  PD exotropia needed both adjustment and additional rectus surgery. The success rate for distance correction was 85% at 6 months and 1 year. The overall success rate was 71% at 6 months. Percentage of patients with binocular single vision improved from 31% preoperatively to 78% by 6 months. Incidence of oculocardiac reflex was 6.1%. **Conclusion:** SSASS under monitored conscious anesthesia is a viable option for large-angle strabismus correction with good patient comfort and safety.

**Key words:** Large-angle strabismus, monitored conscious anesthesia, SSASS

Large-angle horizontal strabismus has been variedly defined in the literature. Various studies have used a cut-off value of 40–60 PD to define large-angle strabismus.<sup>[1-3]</sup> The management of large-angle strabismus is challenging. Two, three, and four muscle surgery have been tried by various authors.<sup>[1,4]</sup> Tables for strabismus correction, in general, are designed for two muscle surgery, and there are no large-scale studies validating the surgical dosage for three and four muscle surgery to the best of our knowledge. Reported approaches (for managing large-angle horizontal strabismus) include doing large surgeries on two horizontal rectus muscles,<sup>[5-8]</sup> operating on three horizontal rectus muscles (putting all of them on adjustable),<sup>[4,9]</sup> recessing two horizontal rectus muscles in both eyes by a specified amount and adding a third or fourth rectus muscle based on surgical tables/dosing formulated by the author,<sup>[10]</sup> dividing a surgical amount of 18–19 mm into three rectus muscles, dividing the deviation by two to decide the surgical dosing for one eye and doing the same in the fellow eye.<sup>[11]</sup> Some authors have tried adjustable strabismus surgery,<sup>[1,4,10]</sup> while others have stuck to using fixed surgical dosages.<sup>[1,3,9]</sup> The success rate of surgery for large-angle horizontal strabismus has varied between 40% and 89% across studies.<sup>[1-5]</sup>

Department of Strabismus and Pediatric Ophthalmology, The Eye Foundation, Coimbatore, Tamil Nadu, India

**Correspondence to:** Dr. Muralidhar Rajamani, Department of Strabismus and Pediatric Ophthalmology, The Eye Foundation, 582A, D. B. Road, R. S. Puram, Coimbatore – 641002, Tamilnadu, India. E-mail: rajamanimurali@hotmail.com

Received: 17-Jan-2021

Revision: 16-Feb-2021

Accepted: 28-Jul-2021

Published: 26-Nov-2021

Video Available on:  
www.ijo.in

Access this article online

Website:  
www.ijo.in

DOI:  
10.4103/ijo.IJO\_85\_21

Quick Response Code:



Single-stage adjustable strabismus surgery (SSASS) under monitored conscious anesthesia has been reported to give good success rates for patients with comitant exotropia.<sup>[12-14]</sup> We used this technique in our study patients. The surgery is done on two/three horizontal rectus muscles (depending on the measured deviation) with the recessed muscle placed on adjustable sutures under topical anesthesia supplemented with subconjunctival lignocaine, intravenous (i.v.) fentanyl, and midazolam.<sup>[15-17]</sup> Further surgery/adjustment is done based on the correction achieved. The purpose of this study was to determine if this allows us to optimize the number of rectus muscles operated and achieve good motor alignment. To the best of our knowledge, there are no reported studies on the correction of large-angle strabismus with SSASS.

### Methods

This was a prospective interventional study conducted in a tertiary eye care hospital in South India from August 2017 to May 2019. Patients with large-angle exotropia of  $\geq 40$  PD and above 14 years of age were included in the study. Patients with significant vertical deviations, and neurological problems

This is an open access journal, and articles are distributed under the terms of the Creative Commons Attribution-NonCommercial-ShareAlike 4.0 License, which allows others to remix, tweak, and build upon the work non-commercially, as long as appropriate credit is given and the new creations are licensed under the identical terms.

**For reprints contact:** WKHLRPMedknow\_reprints@wolterskluwer.com

**Cite this article as:** Asafali F, Rajamani M, Periannan C, Michael S, Dandapani R. Outcome of large angle exotropia treated by single stage adjustable strabismus surgery with monitored conscious anesthesia. Indian J Ophthalmol 2021;69:3592-7.

precluding cooperation were excluded. The study adhered to the tenets of the Declaration of Helsinki and was approved by the institution's ethics committee. All patients underwent a comprehensive preoperative evaluation that included vision, cycloplegic refraction, ocular deviation measured in relevant gazes for distance (primary, 25-degree upgaze, and 35-degree downgaze, side gazes) and near (Krimsky test was done in cases with poor fixation), binocular single vision status (BSV) with the Bagolini striated glasses, and stereopsis with the Randot stereo test. The presence of an X response (without any central scotoma) was taken as evidence of binocularity. An improvement (from preoperative to a postoperative review at one month or more) from gross stereopsis/absent stereopsis to any level of stereopsis better than 400 s of arc or improvement two levels or more (if the preoperative stereopsis was better than 400 s of arc), e.g., 100 s of arc preoperative to 50 s postoperative was considered significant. Ocular deviations in patients with intermittent exotropia were measured after 45 min of patch. All patients were operated on by the second author under anesthesiologist supervision. Monitored conscious anesthesia was achieved with intravenous fentanyl (0.5–4.0 µg/kg) and Midazolam (10–20 µg/kg).<sup>[12]</sup> All patients were premedicated with i.v. glycopyrrolate and ondansetron. Patients were maintained in a verbally arousable but painless state (Ramsay sedation score: 2–3).<sup>[18]</sup> Lignocaine jelly (2%) was placed in the conjunctival fornix of the eye to be operated on first 5 min before surgery, and topical proparacaine 0.5% was instilled before surgical aseptis. Patients were instructed to respond in case of pain/discomfort and nausea. Supplemental i.v. fentanyl/midazolam was given and a drop of proparacaine was instilled whenever the patient reported pain/discomfort. Further, 1 cc of lignocaine 2% mixed with adrenaline was injected subconjunctivally near the limbus in all cases prior to commencement, before the second/third muscle, and whenever the patient reported pain. A drop of topical proparacaine was instilled in the conjunctival sac and 25–50 µg of i.v. fentanyl and 0.5–1 mg of i.v. midazolam were administered before hooking the muscles (in addition to subconjunctival lignocaine). Further, i.v. medication and subconjunctival lignocaine were given based on patient requirement and before operating on oblique muscles.

The patient's vitals were monitored throughout the surgery. Should there be a drop in pulse rate >20% from the baseline, the hooked extraocular muscle was released. The procedure was resumed after the pulse rate stabilized [Video 1].

For recessions, the rectus muscle was secured with 6-0 Vicryl® sutures and placed on a hangback suture at the insertion. Resections were done by a standard technique. Every effort was made to minimize traction on the extraocular muscles.

If the ocular deviation was between 40 and 55 PD, two horizontal rectus muscles were operated. For deviations of >55 PD, three rectus muscles [2 Lateral rectus (LR) +1 medial rectus (MR) or 2 MR + 1 LR surgery] was initially done with the recessed muscle(s) on adjustable sutures. Our surgical dosing was modeled on Yang *et al.*'s table<sup>[2]</sup> with one important difference. Yang *et al.*<sup>[2]</sup> operated on 3 horizontal recti for deviations between 40 and 55 PD and 4 horizontal recti for deviations of >55 PD. As we used SSASS on all our study patients, we performed less surgery initially and added more when needed. This allowed us to optimize the number

of muscles operated. For patients with sensory strabismus, only the eye with poor vision was operated upon. When there was a discrepancy between the distance and near deviations, the surgical dosage was planned for the smaller deviation and then adjusted in the event of residual deviation. After completion of surgery based on the initial plan, the patient was made to sit up. We removed the speculum and sterile drape, wiped off the blood, and washed the cornea with BSS before getting the patients to sit up. The extraocular movements were evaluated. If more than 2- limitation on a scale of 1 to 4<sup>[19]</sup> was noted in any direction or if the patient failed to cooperate, the evaluation and adjustment were postponed to the next surgery day. The alignment was assessed by fixing on a Snellen letter chart placed 3.5 m away for distance fixation and at 33 cm for near fixation (with the optical correction if any). For patients requiring optical correction, the glasses were wiped with isopropyl alcohol and then with lens cleaning solution using sterile cotton before asking the patient to wear them. The surgical area was again painted with povidone-iodine, and a sterile adhesive drape was applied before further surgery/adjustment. Residual deviations were corrected by further recessing the recessed muscle or by operating on an additional muscle. Pattern strabismus (A/V patterns) was corrected either by recessing the oblique muscles (when there was overelevation/overdepression in adduction) or by vertical shift of the horizontal rectus muscles in other patients. The target angle was an alignment of 4–6 PD esotropia for patients with exotropia. On completion of surgery, the anesthesia staff requested the patient to rate his/her pain on a scale of 0–10 with 0 implying no pain, 1–3 implying mild pain, 4–6 as moderate pain, and 7–10 referring to severe pain.<sup>[20]</sup> A note was made of postoperative nausea and vomiting for the first 24 h after surgery. A subjective surgeon comfort based on patient cooperation during surgery was also noted on a scale of 1–10. Postoperatively patients were placed on a tapering regime of topical loteprednol for 10 days, moxifloxacin eye drops for 5 days, and artificial tears for 6 weeks. The ocular deviations were measured on postoperative day 1, 1 month, 3 months, and 6 months thereafter. For non-normally-distributed quantitative parameters, Wilcoxon signed *t*-test and Mann-Whitney *u* test were used, and for categorical outcomes, Chi-square test/Fisher's Exact test was used. *P* < 0.05 was considered statistically significant.

## Results

A total of 33 patients with a median age of 23 years (range: 15–69 years) met the study criteria. Ten patients had intermittent exotropia. The number of rectus muscles operated and the percentage of patients who needed adjustment and additional rectus muscle surgery for deviation of <55 PD and >55 PD are given separately in Table 1. Six patients also had surgery on the inferior oblique, and five patients needed superior oblique weakening procedures for pattern exotropia. Three patients had sensory exotropia and were operated on the eye with poor vision. The average amount of surgery was 20.3 ± 5.7 mm (average recession: 13.1 ± 4.5 mm), and we got a dose-response of 2.8 ± 0.7 PD/mm. The mode of number of muscles (rectus + obliques) operated was 3 (range: 2–5).

The median pain score was 2. Two patients reported severe pain and four had moderate pain. Seven patients had no pain throughout the surgery and the remaining experienced

**Table 1: Details of adjustment and number of rectus muscle surgery in patients with <55 PD and >55 PD deviations**

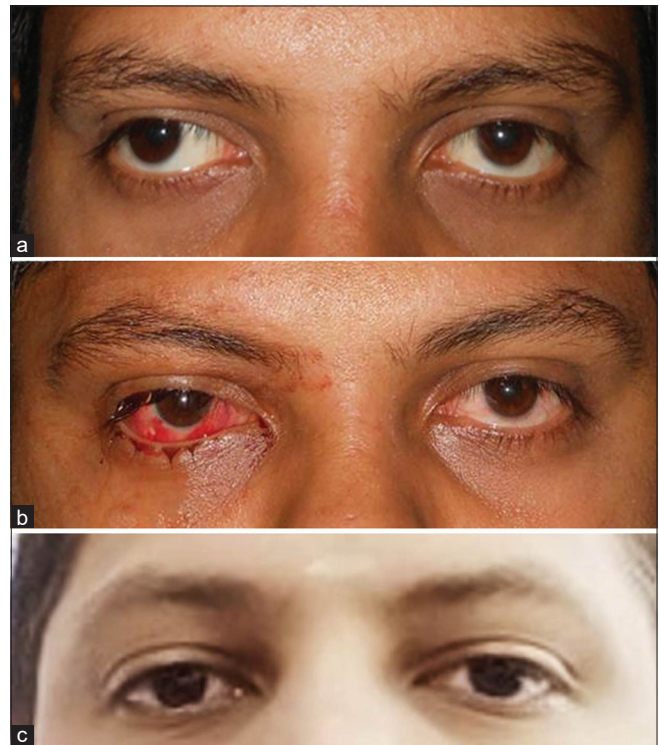Number of patients	Ortho with initial plan (2 rectus surgery for $\leq 55$ PD, 3 rectus surgery for $>55$ PD)	Adjustment needed (slippage/ advancement)	Additional muscle surgery needed	Both adjustment and additional muscle surgery
$\leq 55$ PD EXOTROPIA ( $n=21$ )	10 (47.6%)	1 (4.7%)	10 (47.6%)	
$>55$ PD EXOTROPIA ( $n=12$ )	**4 (33.3%)	1 (8.3%)	6 (50%)	1 (8.3%)

\*\*Out of four patients, three patients had 3 rectus surgery, but one patient with sensory exotropia was managed with supramaximal LR recession of 12.5 mm, MR plication 6 mm in single eye. Ortho - orthophoric

mild pain. In all patients, the pain was intermittent and occurred during hooking of the extraocular muscles and subsided with supplemental anesthesia. The pain score was not substantially different in patients who underwent surgery on oblique muscles ( $P = 0.09$ ). Only one patient had vomiting in the postoperative period. The mean duration of surgery was  $1.3 \pm 0.4$  h (0.7–2.30 h). The surgeon's comfort during the procedure was high (median score was 9; range: 5–10). Two patients needed further adjustment/additional muscle surgery after 3 days as alignment could not be assessed after the initial surgical plan. One patient needed repeated injection of fentanyl and midazolam for pain relief. He was too drowsy to cooperate for assessment. In another patient, repeated use of subconjunctival lignocaine in the right eye made a reliable assessment of deviation difficult (restricted ocular motility more than 2-). The second eye surgery was done three days later in both the patients. The other patients were satisfactorily managed with the preplanned dose of intravenous fentanyl and midazolam as mentioned in the methods section. The initial surgical plan was effective in achieving the target angle in fourteen patients and the remaining needed adjustment/further surgery [Table 1]. Representative patients are shown in Figs. 1a–c and 2a–d. The post-op first-day deviation in primary gaze was not significantly different from the deviation obtained at the end of surgery (excluding the two patients who had deferred adjustment) and hence it is unlikely that lignocaine affected the primary gaze deviation much. Asymptomatic oculocardiac reflex occurred in two patients (6.1%) and subsided on temporarily releasing the hooked muscle. Drop in heart rate was 20% and 22% respectively in those two patients. None of the other patients had significant variations in heart rate. No patient had clinically significant variation in oxygen saturation or blood pressure. All surgeries were done under anesthetist supervision and the pulse and SpO<sub>2</sub> were monitored continuously by anesthesia staff. No other intra/postoperative complications were noted in any of the other patients.

The mean deviation preoperatively and at various visits postoperatively is given in Table 2. The mean correction achieved for distance was  $52.7 \pm 12$  PD for exotropia. The postoperative alignment significantly improved compared to preoperative deviation ( $P < 0.001$ ). The mean pattern deviation (difference between up gaze and downgaze deviation) was  $26.4 \pm 9$  PD preoperatively, which significantly reduced to zero at POD 1 and  $8.1 \pm 8.6$  at 3 months and  $8.7 \pm 8$  PD at 6 months ( $P < 0.05$ ). The mean correction of pattern strabismus attained at 1 month was  $20.3 \pm 9.2$  and at 3 months was  $18 \pm 11.9$  PD ( $P < 0.05$ ).

Six-month follow-up data were available for 26 patients and one-year data for 20 patients. At any visit, an alignment in primary position within 10 prism diopters (PD) was



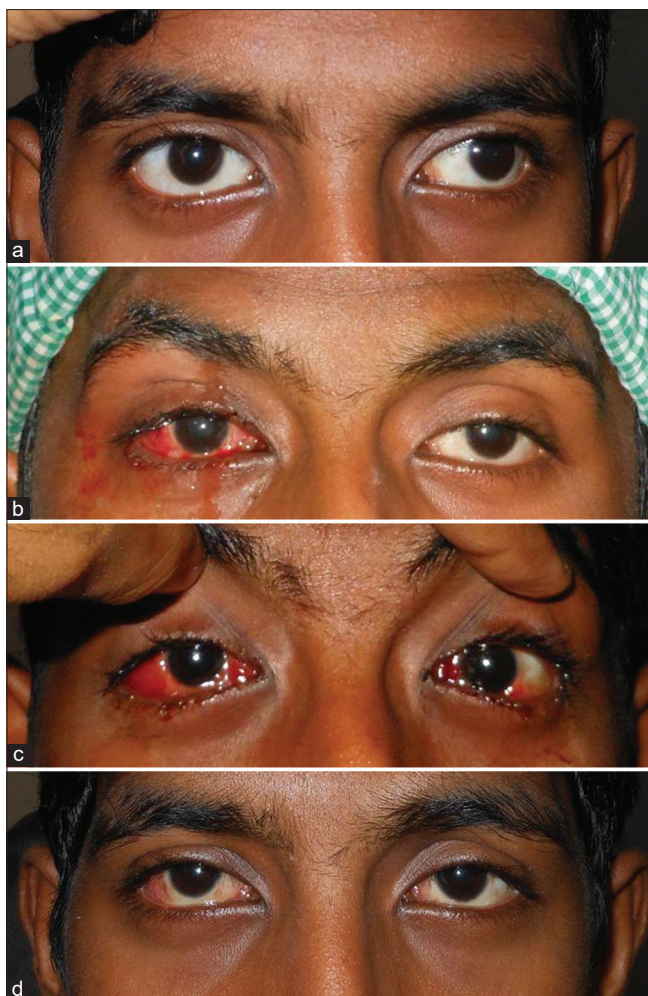**Figure 1:** (a) Preoperative photograph of a patient with 45 PD exotropia. (b) Immediate postoperative photograph of patient in Fig. 2 showing satisfactory alignment with 2 rectus surgery; further surgery was not needed. (c) Late postoperative photograph of patient showing good alignment

considered as a surgical success. The success rates at various visits in patients who were orthotropic/overcorrected and undercorrected are given in Fig. 3. Patients who met success criteria at 3 months constituted 70% of the lost to follow-up cases at 6 months and 1 year. Success rate for distance correction was 85% at 6 months and 1 year. Success rates at various follow-up visits are given in Table 2. Patients who were orthotropic/overcorrected on the first postoperative day had better outcomes compared to patients who were undercorrected [Fig. 3]. The mean exotropic drift was  $3.6 \pm 2.5$  PD in the study group. Twelve patients developed an exotropic drift and eight patients had an esotropic drift over six months review. Three patients complained of intermittent diplopia on the first postoperative day. This subsided by the first month review. No patient had ocular motility restriction of more than 1 (on a scale of 1 to 4) by the third-month review. No patient requested a second surgery for the residual deviation.

**Table 2: Alignment and success rates at various reviews**

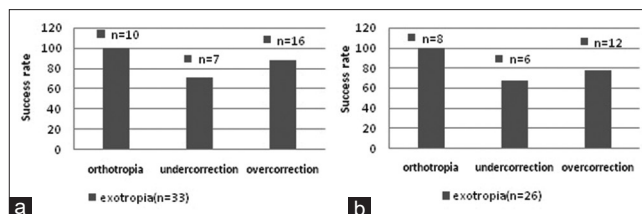
Parameters	Preoperative	1 month	3 months	6 months	1 year
*Deviation (PD) Mean/SD	52±11.1	4.2±6.7	4.7±6	5.5±6.2	4.8±5.9
*Deviation Median (IQR)	50 (45,60)	0 (0,8.5)	3 (0,8)	4 (0,9.25)	3 (0,8.75)
Success rate (%) (distance)	-	88%	88%	85%	85%
Success rate (near)	-	85%	75%	78%	60%
Overall success (distance + near)	-	79% (n=33)	76% (n=33)	71% (n=26)	60% (n=20)

\*Distance deviation. At any visit, an alignment in primary position within 10 prism diopters (PD) was considered as a surgical success



**Figure 2:** (a) Preoperative photograph of a patient with 55 PD exotropia. (b) Residual exotropia after right eye surgery of the patient. Therefore, the right lateral rectus was slipped further and the left medial rectus was plicated. (c) Final alignment of the patient in Fig. 3a after OU surgery showing good alignment in primary position (d) Photograph taken one month after surgery showing good alignment

Preoperatively only 9 patients (31%) had fusion with gross stereopsis in two of them. There were 3 patients with poor vision in one eye and they were excluded from the analysis. Patients with BSV (fusion) increased to 78% by 6 months, and 83% by one year ( $P < 0.05$ ). 67% patients had measurable stereopsis by 6 months. Stereopsis better than 100 arc seconds was attained in 37.5% patients by 6 months and 47% patients by one year. The difference was not statistically significant ( $P = 0.12$ ).



**Figure 3:** (a) Success rate at 3 months in patients with overcorrection/undercorrection/orthotropia on the first postoperative day. (b) Success rate at 6 months in patients with overcorrection/undercorrection/orthotropia on the first postoperative day The figure correlates success rates with alignment attained on the first postoperative day. The patients are divided into three groups based on the first-day alignment as orthotropia, overcorrection, and undercorrection

### Discussion

The surgical management of large-angle horizontal strabismus has been a matter of considerable debate. Surgery restricted to two horizontal rectus muscles would save time and reduce patient discomfort and would leave two rectus muscles for future surgery when needed. This would be the logical choice in patients with sensory exotropia as surgery on the “good” eye is avoided.<sup>[5,6]</sup> Chang *et al.*<sup>[5]</sup> and Yang *et al.*<sup>[2]</sup> showed that supramaximal surgery on the horizontal rectus muscles for large deviations did not produce cosmetically disfiguring ocular motility restrictions or palpebral fissure changes. Schwartz *et al.*<sup>[8]</sup> also showed that a large recession on the LR was not associated with severe motility restrictions. Elkamshoushy *et al.*<sup>[21]</sup> reported success rates of 77% at 6 months in patients with large-angle exotropia (60–140 PD) treated with bimodal resection (8–12 mm). Other studies have shown reduced success rates with surgery limited to two rectus muscles. Livir-Rallatos *et al.*<sup>[22]</sup> reported that surgery on two muscles was not reliable in correcting deviations above 50 PD and resulted in under correction. In comparison, bilateral LR recessions were successful in 86% of patients with deviations of <45 PD. Millán *et al.*<sup>[23]</sup> reported that monocular surgery resulted in under corrections in 100% of patients with >65 PD.

Cifuentes *et al.*<sup>[11]</sup> reported success rates of 89% for near and 85% for distance with three muscle surgery. However, only six patients in his series had deviations of >50 PD. Lau *et al.*<sup>[9]</sup> reported 75% successful alignment for exotropia ranging from 60 to 85 PD. Bilateral LR recessions of 9.0 mm were done aiming for a correction of 50 PD. The remaining deviation was corrected with unilateral MR resection assuming a correction of 5 PD for every millimeter of resection. Chen *et al.*<sup>[1]</sup> reported on the results of 3 and 4 muscle surgeries for 40–80 PD. The author’s table of surgical dosing was used. He noted that

larger preoperative angles of deviation were associated with a greater chance of under correction. The use of adjustable strabismus surgery was associated with greater success rates (63% compared with 33% for traditional suture surgery at the last review).

Putting all the aforementioned studies in perspective [Table 3] and considering our results presented in Table 2, there is no denying that the management of large-angle strabismus is challenging. There is a great variation in the surgical results obtained. In our series, 47.6% patients with deviations of <55 PD (n = 21) needed surgery on third rectus muscle and 50% patients with deviations of >55 PD (n = 12) needed surgery on four rectus muscles. Two muscle surgery may therefore be inadequate for deviations between 40 and 55 PD in many instances. We found that placing recessed muscles on adjustable sutures was of help in achieving a good initial alignment and found the need to use them in three of our patients. As the surgery was done under topical anesthesia with monitored conscious anesthesia, the decision to operate on a third muscle

in the same sitting was easy. Again the decision for more surgery could be easily made without moving the patient out of the operating room. As mentioned earlier, only two patients had a deferred adjustment and further surgery as a two-staged procedure. A result similar to ours was reported by Currie *et al.*<sup>[10]</sup> in a series of 26 patients with large-angle exotropia. Two, three, and four muscle procedures were used with adjustable sutures in 25/26 patients. The criteria for choosing the number of muscles, surgical dosing, type of anesthesia, and the timing of adjustment were not specified by the authors. Hong Li *et al.*<sup>[4]</sup> reported on the management of very large-angle exotropia with three muscle surgery under topical anesthesia and all three muscles were placed on adjustable sutures (single-stage adjustment) after supramaximal surgery and obtained 83% success. We believe that having an Anesthetist on standby and administering intravenous analgesia/sedation (in addition to topical anesthesia) eases the surgery. A review of current literature on the treatment of large-angle horizontal strabismus can be found in Table 3. We supplemented intravenous

**Table 3: A review of current literature on large-angle strabismus**

Author	Sample size	Study type	Large-angle strabismus definition	Adjustable	Anesthesia	Success	No. of recti	Surgical dosing mentioned
Schwartz <i>et al.</i> <sup>[8]</sup> (1980)	22	Retrospective	>40 PD	No	Not mentioned	77%	2	Yes
Livir-Rallatos <i>et al.</i> <sup>[22]</sup> (2002)	63	Retrospective	>35 PD	No	Not mentioned	≤50 PD - 71% >50 PD - 18%	2	Yes
Currie <i>et al.</i> <sup>[10]</sup> (2003)	26	Retrospective	>45 PD	Yes	Not mentioned	77%	2/3/4	No
Millán <i>et al.</i> <sup>[23]</sup> (2009)	92	Retrospective	>40 PD	No	LA + 5 mg Diazepam oral	>15 PD residual in all cases >65 PD	2	Yes
Thomas <i>et al.</i> <sup>[3]</sup> (2010)	50	Retrospective	>50 PD	No	LA/GA	60% (esotropia) 44.45% (exotropia)	2/3	Yes
Lau <i>et al.</i> <sup>[9]</sup> (2010)	24	Prospective	>60 PD	No	GA	75%	3	Yes
Chang <i>et al.</i> <sup>[5]</sup> KJO (2011)	4	Prospective	>75 PD	Yes	GA	Cosmetically acceptable in all cases-4/4 had good alignment	2	No
Camuglia <i>et al.</i> <sup>[24]</sup> (2011)	51 Infantile esotropia	Prospective	>60 PD	Not mentioned	GA	95.7% at 6 months	3	Yes
Li <i>et al.</i> <sup>[4]</sup> J AAPOS (2013)	23 Constant exotropia	Prospective	>120 PD	*yes	TA alone	82.6%	3	Yes
John H Chen <i>et al.</i> <sup>[1]</sup> (2015)	47 Exotropia	Retrospective	> 40 PD	*Yes	Not mentioned	42% (3 muscle) 50% (4 muscle)	3/4	Yes
Min Yang <i>et al.</i> <sup>[2]</sup> (2016)	40 Intermittent exotropia	Retrospective	>60 PD	Not mentioned	GA	77.5%	2/3	No
Elkamshoushy <i>et al.</i> <sup>[21]</sup> (2017)	64	Retrospective	>60 PD	No	Not mentioned	77%	2	Yes
Cifuentes <i>et al.</i> <sup>[11]</sup> (2018)	28	Retrospective	>30 PD	In some cases	Not mentioned	85% (distance) 89% (near)	3	Yes
Our study	33	Prospective	>40 PD	Yes (SSASS)	Monitored conscious anesthesia and TA/LA	85% (distance) 71% (overall)	2/3/4 recti + oblique muscles	Yes

LA - local anesthesia, GA - general anesthesia, TA - topical anesthesia SSASS - single-stage adjustable strabismus surgery PD - prism diopters

medications with liberal use of topical proparacaine and subconjunctival lignocaine (irrigated near the limbus). This affected ocular motility and precluded same-day adjustment in only one patient. We titrated subconjunctival lignocaine dosage based on the patient's requirements. It may be argued that this may influence ocular motility or the primary position deviation. We believe that this was unlikely. The injection was given near the limbus away from the muscle. Also, ocular motility limitation was never more than 1 in any patient. It is difficult to say if limitation (when present) was due to the effect of recession or local anesthetic agent. Whenever we noted a greater restriction (as in the patient mentioned above), we deferred single-stage adjustment. The first postoperative day alignment was not significantly different from that obtained at the end of surgery.

We report an overall success rate of 71% at 6 months. We also observed a better success rate in patients who were orthotropic/overcorrected on the first postoperative day [Fig. 3]. None of our patients needed a re-surgery, and all our patients were satisfied with the cosmetic outcome. It would therefore be reasonable to recommend the routine use of adjustable sutures in large-angle horizontal strabismus given the highly variable response to surgery. SSASS may provide additional advantages of minimizing patient visits to the operating room especially if there is a large undercorrection that cannot be remedied by adjustment alone. Sedation under intravenous fentanyl and midazolam allows the patient to be maintained in a verbally arousable but painless state.<sup>[18]</sup> This allows adjustment and additional surgery (where needed) to be done in the same sitting with good patient comfort and cooperation. The patients must however be counseled about the rare possibility of having to reschedule the adjustment to a later time in the event of drowsiness or globe hypokinesia. The use of conscious sedation in comitant exotropia was first reported by Sharma *et al.*<sup>[12]</sup> The authors concluded that it was a safe procedure and provided better results than conventional strabismus surgery. They reported a 73.34% incidence of oculo-cardiac reflex. The low incidence of this complication in our series was likely due to routine premedication with intravenous glycopyrrolate. The limitations of our study include small sample size and limited follow-up.

## Conclusion

To sum up, SSASS under monitored conscious anesthesia is a viable option in treating large-angle exotropia. The operating surgeon may make an initial plan and add an additional muscle or adjust depending on the results achieved. Its role needs further evaluation in a larger series of patients.

## Acknowledgements

The second author wishes to acknowledge his mentor, Prof. Pradeep Sharma, for having taught him the technique of SSASS using fentanyl and midazolam. We also wish to thank our operating room and anesthesia staff for their unflinching support.

## Financial support and sponsorship

Nil.

## Conflicts of interest

There are no conflicts of interest.

## References

- Chen JH, Morrison DG, Donahue SP. Three and four horizontal muscle surgery for large angle exotropia. *J Pediatr Ophthalmol Strabismus* 2015;52:305-10.
- Yang M, Chen J, Shen T, Kang Y, Deng D, Lin X, *et al.* Single stage surgical outcomes for large angle intermittent exotropia. *PLoS One* 2016;11:e0150508. doi: 10.1371/journal.pone.0150508.
- Thomas S, Guha S. Large-angle strabismus: Can a single surgical procedure achieve a successful outcome. *Strabismus* 2010;18:129-36.
- Li JH, Zhang LJ. Three-muscle surgery for very large-angle constant exotropia. *J AAPOS* 2013;17:578-81.
- Chang JH, Kim HD, Lee JB, Han S-H. Supramaximal recession and resection in large-angle sensory exotropia. *Korean J Ophthalmol* 2011;25:139-41.
- Velez G. Surgical treatment of exotropia with poor vision. *Strabismus II. Proceedings of the Fourth Meeting of the International Strabismological Association* 1984, 263-7.
- Burian HM, Spivey BE. The surgical management of exodeviations. *Am J Ophthalmol* 1965;59:603-20.
- Schwartz RL, Calhoun JH. Surgery of large angle exotropia. *J Pediatr Ophthalmol Strabismus* 1980;17:359-63.
- Lau FHS, Fan DSP, Yip WWK, Yu CBO, Lam DSC. Surgical outcome of single- staged three horizontal muscles squint surgery for extra-large angle exotropia. *Eye* 2010;24:1171-6.
- Currie ZI, Shipman T, Burke JP. Surgical correction of large-angle exotropia in adults. *Eye* 2003;17:334-9.
- Cifuentes DL, Pineles SL, Demer JL, Velez FG. Surgical success and lateral incomitance following three-muscle surgery for large-angle horizontal strabismus. *J AAPOS* 2018;22:17-21.
- Sharma P, Julka A, Gadia R, Chhabra A, Dehnan M. Evaluation of single-stage adjustable strabismus surgery under conscious sedation. *Indian J Ophthalmol* 2009;57:121-5.
- Carruthers JD, Mills K, Bagaric D. Can adjustable suture surgery be performed with conscious sedation? *J Pediatr Ophthalmol Strabismus* 1995;32:17-9.
- Cogen MS, Guthrie ME, Vinik HR. The immediate postoperative adjustment of sutures in strabismus surgery with maintenance of anesthesia using propofol and midazolam. *J AAPOS* 2002;6:241-5.
- Liu LL, Gropper MA. Postoperative analgesia and sedation in the adult intensive care unit: A guide to drug selection. *Drugs* 2003;63:755-67.
- Sharma P, Reinecke RD. Single-stage adjustable strabismus surgery for restrictive strabismus. *J AAPOS* 2003;7:358-62.
- Miller DR. Intravenous anaesthesia: New drugs, new concepts, and clinical applications. *Can J Anaesth* 1996;43:142-54.
- Ramsay MA, Savege TM, Simpson BR, Goodwin R. Controlled sedation with alphaxalone- alphadolone. *Br Med J* 1974;2:656-9.
- Rowe FJ. Diagrammatic recording of ocular motility. *Clinical Orthoptics*. 3<sup>rd</sup> ed. Wiley-Blackwell 2012, pp 424-5. ISBN: 978-1-444-33934-5.
- Herr KA, Spratt K, Richardson G. Pain intensity assessment in older adults. *Clin J Pain* 2004;20:207-19.
- Elkamshoushy AA. Bilateral medial rectus resection for primary large-angle exotropia. *J AAPOS* 2017;21:112-6.
- Livir-Rallatos G, Gunton KB, Calhoun JH. Surgical results in large angle exotropia. *J AAPOS* 2002;6:77-80.
- Millán T, Carvalho KM de, Minguini N. Results of monocular surgery under peribulbar anesthesia for large-angle horizontal strabismus. *Clinics* 2010;64:303-8.
- Camuglia JE, Walsh MJ, Gole GA. Three horizontal muscle surgery for large-angle infantile esotropia: Validation of a table of amounts of surgery. *Eye* 2011;25:1435-41.