

Endoscopic Third Ventriculostomy and Simultaneous Tumor Biopsy in Pineal Region Tumors using the “Single Burr Hole” Technique: An Analysis of 34 Cases

Abstract

Background: Pineal region tumors often present with hydrocephalus. Endoscopic third ventriculostomy (ETV) and simultaneous tumor biopsy remain a minimally invasive procedure offering both diagnostic and therapeutic advantages in the management of these tumors. However, different operative techniques have been described in the literature. **Aim:** The aim is to study the ETV success rate, diagnostic rate of simultaneous tumor biopsy, complications, and follow-up of patients of pineal region tumors managed with ETV and simultaneous tumor biopsy using the single burr hole technique. **Methods:** The study was performed by retrospectively reviewing the records of patients of pineal region tumors managed by simultaneous ETV and tumor biopsy using a “single burr hole” technique from January 2012 to December 2019. **Results:** Thirty-four patients (22 males and 12 females) with a mean age of 28.7 years were analyzed. ETV was successful in relieving hydrocephalus in 29 (87.8%) patients. Three patients needed a ventriculoperitoneal shunt, and one required Ommaya reservoir placement for persistent hydrocephalus. Histological diagnosis was successfully established in 26 (78.8%) patients. There were two procedure-related mortalities. Two patients underwent craniotomy and tumor excision subsequently. Radiotherapy was given to 11 patients, and 9 patients were managed by observation alone. The mean follow-up of our study was 15.8 months. **Conclusions:** Simultaneous ETV and tumor biopsy using a single burr hole technique is a safe, minimally invasive procedure for the management of pineal region tumors.

Keywords: Endoscope, pineal region tumors, posterior third ventricle tumors, single burr hole, third ventriculostomy

Gagandeep Attri,
Jaskaran Singh
Gosal,
Deepak Khatri,
Kuntal Kanti Das,
Kamlesh Singh
Bhaisora,
Anant Mehrotra,
Jayesh Sardhara,
Arun Kumar
Srivastava,
Sanjay Behari,
Sushila Jaiswal¹,
Awadhesh Kumar
Jaiswal

Departments of Neurosurgery
and ¹Pathology, SGPGIMS,
Lucknow, Uttar Pradesh, India

Introduction

Ever since Dandy^[1] used ventriculoscope for the visualization and coagulation of choroid plexus for the treatment of hydrocephalus in 1918, neuroendoscopy has come a long way in the management of hydrocephalus of different etiology. In 1973 for the first time, Fukushima^[2] introduced the concept of endoscopic tumor biopsy (ETB) in paraventricular tumors, and during the last 20 years, concurrent endoscopic third ventriculostomy (ETV) and tumor biopsy for pineal region tumors have evolved into standard initial treatment.^[3-6] This procedure is a minimally invasive, safe, and effective technique to essentially “kill many birds with one stone,” that is, resolving the hydrocephalus and obtaining tumor biopsy and cerebrospinal fluid (CSF) at the same time. More often than not, simultaneous ETV and tumor biopsy is the

only surgical procedure required in pineal region tumors because of the efficacy of radiation and chemotherapy in many of the histopathological subtypes. This operative strategy is currently regarded as indispensable, however, different techniques of simultaneous ETV and biopsy have been described, and there is no standardized technique of doing this procedure as of now.^[4,7-9] In this article, the authors present their experience of simultaneous ETV and tumor biopsy in 34 patients with pineal region tumors using a “single burr hole” technique.

Methods

Patients

All patients with the pineal region tumors managed with simultaneous ETV and

Address for correspondence:
Prof. Awadhesh Kumar Jaiswal,
Department of Neurosurgery,
SGPGIMS, Raibareli
Road, Lucknow - 226 014,
Uttar Pradesh, India.
E-mail: jaiswal_dr_2002@
yahoo.co.in

Video available on:
www.asianjns.org

Access this article online

Website: www.asianjns.org

DOI: 10.4103/ajns.AJNS_194_20

Quick Response Code:



How to cite this article: Attri G, Gosal JS, Khatri D, Das KK, Bhaisora KS, Mehrotra A, *et al.* Endoscopic third ventriculostomy and simultaneous tumor biopsy in pineal region tumors using the “Single Burr Hole” technique: An analysis of 34 cases. *Asian J Neurosurg* 2020;15:976-82.

Submitted: 03-May-2020

Revised: 07-May-2020

Accepted: 15-May-2020

Published: 19-Oct-2020

This is an open access journal, and articles are distributed under the terms of the Creative Commons Attribution-NonCommercial-ShareAlike 4.0 License, which allows others to remix, tweak, and build upon the work non-commercially, as long as appropriate credit is given and the new creations are licensed under the identical terms.

For reprints contact: WKHLRPMedknow_reprints@wolterskluwer.com

tumor biopsy from January 2012 to December 2019 at our institute were included in this retrospective analysis. In all 34 patients, we used a single trajectory approach except in 1 patient where the two burr holes were used. We reviewed the clinical features, radiological findings, surgical procedure, pathological biopsy, clinical outcomes, and follow-up of all the patients. Written informed consent was taken from all the patients, and the ethical approval to undertake the study was taken from the hospital's ethics committee.

Operative technique

All patients underwent magnetic resonance imaging (MRI) of the brain with contrast. We used a sagittal T2-weighted MRI midline cut to preoperatively plan the location of the burr hole to be used for ETV and tumor biopsy. As shown in Figure 1, two imaginary lines were drawn: one line (line A) starting from the floor of the third ventricle at the level of the prepontine space to the posterior edge of the widened foramen of Monro (FOM) and second line (line B) starting from the anterior-most point of the tumor to the anterior edge of the widened FOM. Then, both of these lines were extended upward tangentially toward the calvaria to generate two points over the skull surface. A point midway between these two points was marked on the scalp as the site of burr hole (point C) for the endoscope for both the ventriculostomy and the biopsy. The distance of this point from the coronal suture was measured on preoperative radiology to assist in intraoperative marking of the same point on the calvaria. It was our observation that on an average, the site of burr hole would usually come just

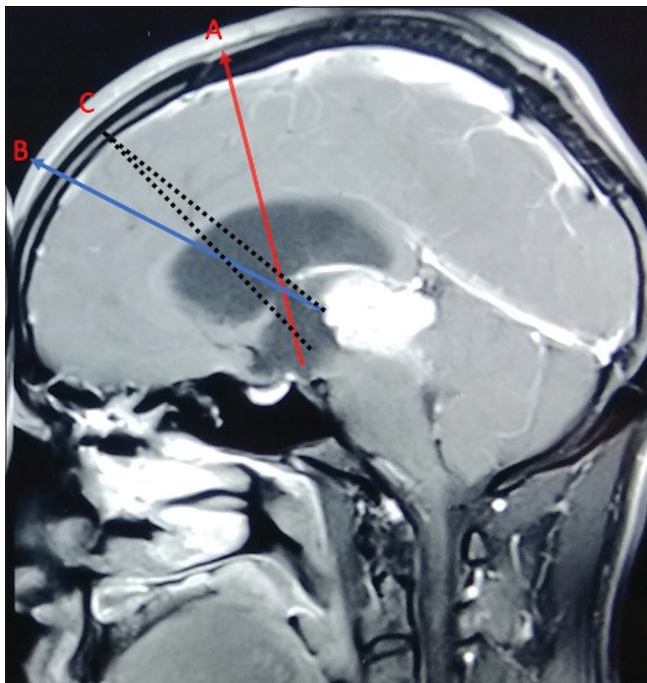


Figure 1: A T1 postcontrast sagittal magnetic resonance demonstrating the single burr hole/trajectory C technique, calculated as a point midway between A and B (detail in text)

behind the hairline. Then, we mark the C-shaped incision so as to incorporate both the incision and burr hole just behind the hairline.

The patient is placed supine with the head placed on a head ring in a slightly flexed position under general anesthesia. An electrocardiography electrode is placed over the nasion to determine the midline during the surgery. We performed simultaneous ETV and tumor biopsy using a single burr hole in all cases except in one case where two burr holes were made: one for ETV and the other one for tumor biopsy. The position of the proposed burr hole is marked over the skull, and a standard burr hole is made. The dura is opened in a cruciform manner, and the underlying pia is coagulated and incised. The endoscope sheath along with its obturator is introduced into the brain parenchyma perpendicular to the burr hole till a feeling of “give way” is obtained, following which the obturator is removed leaving the endoscope sheath in place. This give way feel suggests entry into the lateral ventricle, and CSF also egresses out through this sheath. The CSF is collected at this point for studying the tumor markers and the malignant cytology. After this, the 3.6-mm ventriculoscope is passed into the sheath, and the lateral ventricular cavity is visualized. First, the choroid plexus is identified which is followed anteriorly where it dips into the third ventricle through the FOM. The septal and thalamostriate veins are identified. The ventriculoscope is passed into the third ventricle through the FOM, and the third ventricular floor having the infundibular recess, dorsum sellae, premammillary membrane, and mammillary bodies (from anterior to posterior) are identified. Usually, this floor is very thin due to hydrocephalus and often basilar tip is seen through the premammillary membrane. An opening in the third ventricular floor is made with the help of tip of Fogarty catheter size 4 Fr, which is further enlarged with successive inflation and deflation of the Fogarty catheter balloon. After this, the ventriculoscope is passed through this stoma into the prepontine cistern to look for any second membrane, which is also opened, if present, to establish free CSF flow across the stoma. This completes the procedure of ETV. After this, the ventriculoscope is slightly withdrawn and is directed toward the posterior third ventricular area (by passing the scope above the massa intermedia) to visualize the tumor. Taking the scope above the massa intermedia not only helps to avoid injury to the adjacent structure but also a straight forward visualization of the tumor area. We do not prefer to cauterize the tumor surface first before taking the biopsy, except in a few cases where the tumor surface was reddish-pink, in order to decrease the cautery artifacts in the biopsy specimen. On an average, we take 4–5 samples of biopsy with the cupped biopsy forceps in each patient [Supplementary Video 1]. Bleeding from the tumor surface was managed in most of the cases with irrigation alone and cauterization of the tumor surface in a few. We did not encounter any significant tumor-related

bleeding in any of our patients except in one patient wherein major bleeding occurred from choroid plexus, and an external ventricular drain (EVD) had to be placed intraoperatively in this patient.

Results

There were 22 male and 12 female patients with a mean age of 28.7 years (range: 4–61 years). Thirty-three patients underwent ETV and simultaneous tumor biopsy at presentation. We could not perform ETV and tumor biopsy in one patient due to significant intraoperative bleeding from the choroid plexus injury and poor visibility caused by intraoperative bleeding. Table 1 lists the clinical features and postprocedural improvement of patients in our series.

Outcome of endoscopic third ventriculostomy

Twenty-nine (87.8%) patients showed symptomatic relief following ETV and did not require any further CSF diversion procedure. Three patients required ventriculoperitoneal (VP) shunt placement, and in one patient, Ommaya reservoir was placed within 1 month of the ETV for persistent symptomatic hydrocephalus.

Diagnostic yield of endoscopic tumor biopsy

Histological diagnosis was successfully established in 26 (78.8%) patients [Table 2]. In one patient, biopsy could

not be taken due to intraoperative bleeding. Histopathology was inconclusive in seven patients (21.2%). Of these, one patient, unfortunately, succumbed to meningitis due to CSF leak within 15 days of ETV and biopsy; hence, the final diagnosis could not be established. The remaining six patients were advised for definitive surgery. Three patients with radiological diagnosis of thalamic glioma with posterior third ventricle extension had inconclusive biopsies. One patient was planned for definitive surgery but never turned up for follow-up. Two patients in whom biopsy was inconclusive are doing well and are planned for definitive surgery by open craniotomy for establishing the diagnosis. One patient underwent craniotomy and gross total tumor excision with the final diagnosis of meningioma. One patient with an initial tumor of pineal parenchymal tumors of intermediate differentiation (PPT-ID) was operated by craniotomy due to an increasing tumor bulk with the final biopsy of pineoblastoma.

Complications

The various complications occurring in our series are summarized in Table 3. There were two procedure-related deaths in our initial cases. One patient had massive intraoperative bleed from injury to the choroid plexus, which could not be controlled with irrigation and plexus cauterization; hence, neither ETV nor tumor biopsy could be performed, and an EVD was placed intraoperatively, later developed meningitis, and died in postoperative period. The second patient also died due to meningitis secondary to CSF leak from the ETV wound site. In ten cases, there was minor intraoperative bleed, which could be managed with irrigation alone. Minor forniceal contusion was noticed in 6 cases, however, no memory dysfunction was reported in any of them.

Management of patients postendoscopic third ventriculostomy and tumor biopsy and follow-up

The mean follow-up of our study group is 15.8 months (range: 2–60 months). Overall, 11 patients received radiotherapy, and two patients received a combination of radio and chemotherapy post-ETV and tumor biopsy. Nine patients (five – low-grade glioma, two – PPT-ID, one – pilocytic astrocytoma, and one – pineal cyst) were managed with observation alone. The mean follow-up in this subgroup of patients managed with observation alone is 10 months (range: 2–25 months). Two patients were reoperated by craniotomy for gross total excision [Table 4]. Two patients of PPT-ID were advised craniotomy and excision of tumor and refused definitive surgery. Interestingly, they are doing well without any complaints at a follow-up of 9 months and 2 years, respectively [Figure 2].

Two patients (1 having thalamic lesion with posterior third ventricle extension and another one having a mesencephalic lesion) were admitted in poor sensorium and were discharged in the same neurological status despite

Table 1: Clinical features and their improvement postendoscopic third ventriculostomy and simultaneous tumor biopsy

Clinical features	Number of patients	Improvement postprocedure
Raised ICP	25	20
Parinaud’s syndrome	3	1
FND	11	7
Altered sensorium	10	7
Blurring of vision	18	12
Headache	26	22
Vomiting	19	18
Cognitive impairment	10	6

ICP – Intracranial pressure; FND – Focal neurological deficit

Table 2: Results of endoscopic tumor biopsy

Histopathology	Number of patients
LGG	7
PPT-ID	5
Pineoblastoma	4
Ependymoma	3
PNET	2
Pilocytic astrocytoma	2
Germinoma	2
Pineal cyst	1
Inconclusive	7

PPT-ID – Pineal parenchymal tumor of intermediate differentiation; PNET – Primitive neuroectodermal tumor; LGG – Low-grade glioma

Table 3: Complications in our series

Complication	Number of patients
Minor intraoperative bleed	10
IVH	3
Gaze palsy	2
Thalamic injury	1
Meningitis	1
CSF leak	1
Deaths	2

IVH – Intraventricular hemorrhage; CSF – Cerebrospinal fluid

Table 4: Management of patients postendoscopic third ventriculostomy and tumor biopsy

Management	Number of patients
Definitive surgery	2
Chemotherapy + radiotherapy	2
Radiotherapy alone	11
Observation alone	9
Need for postoperative VP shunt	3

VP – Ventriculoperitoneal

resolution of the hydrocephalus and ultimately succumbed to death after discharge from the hospital at 2 months. One patient (biopsy-inconclusive) died due to pregnancy-related complications at other hospitals after 2 months following ETV and tumor biopsy. One patient had a seizure after 2 months of surgery at home and died due to aspiration pneumonitis. One patient died after 2 years due to the recurrence of tectal glioma (biopsy – low-grade astrocytoma).

After excluding deaths and patients lost to follow-up, 24 patients are doing well on regular follow-up.

Discussion

Tumors of the pineal gland and posterior third ventricle are rare, constituting $\leq 1\%$ of all central nervous system tumors in adults and between 3% and 8% of all tumors in the pediatric population.^[10] Although heterogeneous regarding histology and imaging, 90% of them present clinically with raised intracranial pressure due to obstructive hydrocephalus.^[10,11] Since the treatment of choice for many pineal region tumor types is radiation and/or chemotherapy (even observation alone after ETV in low-grade gliomas),^[4,10] establishing the histological diagnosis of the tumor and alleviating the hydrocephalus simultaneously through ETV and tumor biopsy is a reasonable strategy and has revolutionized the treatment of these tumors in the modern era.^[12]

With more technical advances in neuroendoscopy,^[13-15] an endoscopic biopsy from intraventricular and paraventricular regions has become increasingly popular. Ellenbogen and Moores first described simultaneous ETV and biopsy in 1997.^[16] Since then, there have been multiple clinical series published describing the different techniques, efficacy, and safety of this procedure.

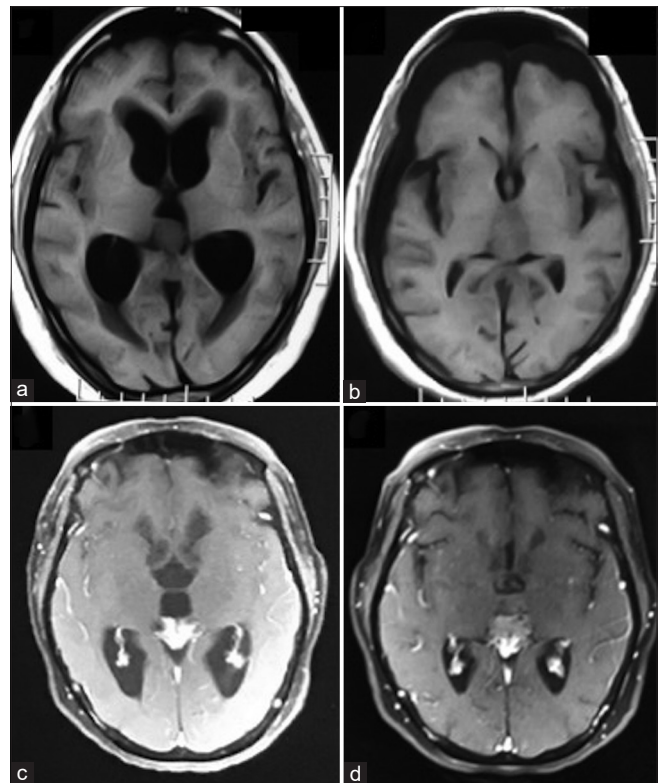


Figure 2: (a) Preoperative axial T1 magnetic resonance: Pineal region tumor with hydrocephalus. (b) Postoperative axial T1 magnetic resonance (9 months postendoscopic third ventriculostomy/endoscopic tumor biopsy): Marginal increase in tumor size with no hydrocephalus. Biopsy – pineal parenchymal tumor of intermediate differentiation. (c) Preoperative axial T1 contrast magnetic resonance of another patient: Pineal region tumor with hydrocephalus. (d) Postoperative axial T1 contrast magnetic resonance (2 years postendoscopic third ventriculostomy/endoscopic tumor biopsy): Stable tumor size with no hydrocephalus

Although stereotactic biopsy (STB) is an option,^[17] simultaneous ETV and tumor biopsy has many distinct advantages: (1) direct tumor visualization along with accurate biopsy of the suspect areas is possible, (2) in addition to establishing the diagnosis, it is therapeutic in resolving the acute crisis of hydrocephalus, (3) possibility of inspection of the ventricular wall from inside to look for any leptomeningeal spread of tumor, (4) CSF sample can be collected for malignant cytology as well as tumor markers, and (5) last but not the least, less bleeding risk unlike in STB.^[4,9]

We present our series of posterior third ventricle region tumors in which simultaneous ETV and tumor biopsy were performed using a rigid endoscope through a single burr hole. There are several surgical considerations in performing simultaneous ETV and tumor biopsy.

Flexible versus the rigid endoscope

Some surgeons employ flexible endoscope for ETB, especially using a single burr hole for posterior third ventricle tumors to decrease the risk of forniceal injury during its maneuvering around the FOM.^[4,18,19] However,

the problem with the flexible scope is the poor image quality and the small biopsy sample it provides. We used only the rigid endoscope in all our cases due to its superior image quality and large bits of tissue it can take and found that there were no significant forniceal contusions (minor forniceal contusions in six of our patients) with its movement around the FOM. Thus, the rigid scope has definite advantages over the flexible scope.^[7,9]

Single versus the double burr hole technique

Probably, one of the most pressing controversies is whether to employ a single or two burr holes for simultaneous ETV and tumor biopsy. The rationale for the two burr holes is that it allows two different trajectories: one for ETV and other for tumor biopsy through the FOM. Chibbaro *et al.* and Oi *et al.*^[20,21] claimed that double burr hole technique allows for a better diagnostic biopsy rate and lesser forniceal manipulation as compared to the single burr hole technique. However, Morgenstern *et al.*^[8] have compared the single versus dual burr hole technique and found no difference between the two in terms of safety and diagnostic efficacy of the procedure, thus advocating a single burr hole technique if the tumor is in the anterior third ventricle, or the disease process has enlarged the FOM.^[8] Ahmed *et al.* and Mohanty *et al.*^[7,9] used single burr hole technique with rigid scope in all of their patients, irrespective of the location of tumor in the third ventricle or FOM size with excellent results. We used a single burr hole technique similar to that described by Knaus *et al.*^[22] We did not face any operative difficulty using single burr hole technique, and in our opinion, it has three advantages over dual burr hole technique: (1) single trajectory is used in the brain parenchyma to reach the third ventricle for both ventriculostomy and the biopsy of tumor, (2) the second burr hole (anterior to the precoronal one) in the dual burr hole technique sometimes has to be made over the forehead anterior to the hairline which is avoidable in the single burr hole technique, and (3) no significant forniceal contusions were observed in the single burr hole technique.

Is neuronavigation helpful in deciding trajectory?

Zhu *et al.* and Knaus *et al.*^[22,23] have shown the advantages of using neuronavigation in deciding the trajectory and the exact position of the single burr hole. On the other hand, Oppido *et al.*^[24] did not find neuronavigation guidance of much use. Although we did not use the navigation in any of case in our series, still we do feel that its use may further lead to increased safety and better results.

What to be done first endoscopic third ventriculostomy or the tumor biopsy?

While doing ETV and tumor biopsy together, we did ETV first followed by biopsy of the tumor as done by most of the authors.^[4,8,9,25-27] This sequence is advised to avoid any difficulty in performing the ventriculostomy from any

inadvertent hemorrhage that may occur while taking the biopsy.

Does low-grade glioma of posterior third ventricle need any further intervention?

Low-grade glioma is the most common histopathological diagnosis in our series similar to Ahmed *et al.*^[7] but is different from other series [Table 5]. Out of seven patients with low-grade glioma, five patients in our series are doing well with no complaints after simultaneous ETV and tumor biopsy at a mean follow-up of 10 months. They did not receive any further intervention, and tumor size remained stable over the mean follow-up period. O'Brien *et al.*^[4] have also reported that posterior third ventricular low-grade glioma is very slow growing and can be managed conservatively.

Mohanty *et al.*^[9] described a single trajectory rigid scope technique in 41 cases of posterior third ventricle tumors, however, they did not specify whether they used zero or the 30° rigid scope. Their success of ETV and diagnostic biopsy rates are similar to that of our study. In contrast to Mohanty *et al.*,^[9] where the biopsy of superior vermian lesions gave maximum negative results, negative biopsy rate was maximum in thalamic lesions with posterior third ventricle extension in our series. Ahmed *et al.*^[7] also used the single trajectory rigid scope technique in 47 patients, but they did not describe the operative technique of performing the single burr hole in their study. Moreover, their mean follow-up was only 3 months. Our ETV success rate (88.2% vs. 91%) is comparable, and ETB diagnostic rates are more negative (21% vs. 16%) as compared to them. Open craniotomy was done only in two of our patients as compared to 24 patients in series by Ahmed *et al.*^[7] Table 5 summarizes the comparison of our series with other major series published in the endoscopic treatment of pineal region tumors.

Limitations of the study

A few limitations of our study include the retrospective nature of the collection of data, no use of neuronavigation in our case series, and some cases which were lost to follow-up. Increasing the cohort size and a prospective randomized study in this direction could be of potential interest.

Conclusions

ETV and simultaneous tumor biopsy is a safe, minimally invasive procedure and is used currently as the treatment of choice in pineal region tumors with hydrocephalus. This can be performed safely and effectively using a single burr hole technique with a 0° rigid endoscope, providing better visibility and no additional risk of memory loss. In one-third of cases of posterior third ventricle tumors, especially in low-grade glioma, concurrent ETV and tumor biopsy might be the only procedure required.

Table 5: Summary of major case series of endoscopic third ventriculostomy and simultaneous endoscopic tumor biopsy in posterior third ventricle tumors till now

Author/year	Number of cases	Rigid/flexible scope	0/30 degree scope	Single/double burr hole	ETV success rate (%)	Need of VP shunt/redo-ETV	Diagnostic biopsy (%)	Open craniotomy	Major complications	Mean follow-up (months)	Patients managed with OA	MC Bx
Ahmed <i>et al.</i> (2015) ^[7]	47	Rigid	Did not specify	Single	91.5	4	85	24	Diplopia (3), CSF leak (1)	3	19	LGG
O'Brien <i>et al.</i> (2006) ^[4]	33 ^a	Flexible	-	Single	68	13	76	5	6 th nerve paresis (1), IVH (1)	32	NA	NA
Knaus <i>et al.</i> (2011) ^[22]	11 ^b	Rigid	0°	Single	86.7	2	86.7	1	None	34	NA	Arachnoid cyst
Mohanty <i>et al.</i> (2011) ^[9]	41 ^c	Rigid	Did not specify	Single	86	29	83	12	Bleeding (16), forniceal contusion (8), death (3)	23	-	Glial tumors
Morgenstern <i>et al.</i> (2011) ^[8]	15	Rigid	Both	Both	100	0	86.7	9	None	6	NA	Germinoma
Yamini <i>et al.</i> (2004) ^[19]	8	Both	-	Single	50	4	67	5	IVH (1), transient hemiparesis (8)	25.5	NA	Pineoblastoma
Zhu <i>et al.</i> (2013) ^[23]	11	Rigid	30°	Single	100	0	100	4	IVH (1)	-	1	Germinoma
Present study	34	Rigid*	0°	Single	87.8	3	78.8	2	Gaze palsy (2), thalamic injury (1), death (2)	15.8	9	LGG

^aSimultaneous ETV/ETB done in 33 patients, ETV alone done in 42 patients; ^bTotal 15 patients; ^cTotal 87 patients of paraventricular tumors; *We used 3.6 mm Karl Storz ventriculoscope. ETV – Endoscopic third ventriculostomy; VP – Ventriculoperitoneal; Bx – Biopsy; OA – Observation alone; MC – Most common; IVH – Intraventricular hemorrhage; LGG – Low-grade glioma; CSF – Cerebrospinal fluid; ETB – Endoscopic tumor biopsy

Financial support and sponsorship

Nil.

Conflicts of interest

There are no conflicts of interest.

References

- Piatt JH Jr. Hydrocephalus: Treatment. In: Wilkins RH, Rengachary SS, editors. *Neurosurgery*. 2nd ed. New York: McGraw-Hill; 1996. p. 3633.
- Fukushima T. Endoscopic biopsy of intraventricular tumors with the use of a ventriculofiberscope. *Neurosurgery* 1978;2:110-3.
- Al-Tamimi YZ, Bhargava D, Surash S, Ramirez RE, Novegno F, Crimmins DW, *et al.* Endoscopic biopsy during third ventriculostomy in paediatric pineal region tumours. *Childs Nerv Syst* 2008;24:1323-6.
- O'Brien DF, Hayhurst C, Pizer B, Mallucci CL. Outcomes in patients undergoing single-trajectory endoscopic third ventriculostomy and endoscopic biopsy for midline tumors presenting with obstructive hydrocephalus. *J Neurosurg* 2006;105:219-26.
- Pople IK, Athanasiou TC, Sandeman DR, Coakham HB. The role of endoscopic biopsy and third ventriculostomy in the management of pineal region tumours. *Br J Neurosurg* 2001;15:305-11.
- Shono T, Natori Y, Morioka T, Torisu R, Mizoguchi M, Nagata S, *et al.* Results of a long-term follow-up after neuroendoscopic biopsy procedure and third ventriculostomy in patients with intracranial germinomas. *J Neurosurg* 2007;107:193-8.
- Ahmed AI, Zaben MJ, Mathad NV, Sparrow OC. Endoscopic biopsy and third ventriculostomy for the management of pineal region tumors. *World Neurosurg* 2015;83:543-7.
- Morgenstern PF, Osbun N, Schwartz TH, Greenfield JP, Tsiouris AJ, Souweidane MM. Pineal region tumors: An optimal approach for simultaneous endoscopic third ventriculostomy and biopsy. *Neurosurg Focus* 2011;30:E3.
- Mohanty A, Santosh V, Devi BI, Satish S, Biswas A. Efficacy of simultaneous single-trajectory endoscopic tumor biopsy and endoscopic cerebrospinal fluid diversion procedures in intra- and paraventricular tumors. *Neurosurg Focus* 2011;30:E4.
- Weinberg JS. Pineal region tumors. In: Harbaugh RE, Shaffrey C, Couldwell WT, Berger MS, editors. *Neurosurgery Knowledge Update- A Comprehensive Review*. 1st ed. New York: Thieme; 2015. p. 907.
- Zimmerman RA. Pineal region masses: Imaging. In: Wilkins RH, Rengachary SS, editors. *Neurosurgery*. 2nd ed. New York: McGraw-Hill; 1996. p. 1003.
- Azab WA, Nasim K, Salaheddin W. An overview of the current surgical options for pineal region tumors. *Surg Neurol Int* 2014;5:39.
- Parab A, Khatri D, Singh S, Gosal JS, Deora H, Das KK, *et al.* Endoscopic keyhole retromastoid approach in neurosurgical practice: Ant-man's view of the neurosurgical marvel. *World Neurosurg* 2019;126:e982-8.
- Kumar A, Gosal JS, Dixit P, Rangari K, Singh P, Jaiswal AK. Retromastoid suboccipital keyhole craniectomy and endoscopic controlled excision of a left middle cerebellar peduncle cavernoma. In: Behari S, Jaiswal AK, Srivastava AK, editors. *The Operative Atlas of Neurosurgery: A Compendium of 120 Neuro-Oncological, Case-based, Surgical Approaches*. 1st ed. New Delhi: Thieme; 2020.
- Ravisankar M, Khatri D, Gosal JS, Arulalan M, Jaiswal AK, Das KK. Surgical excision of trigeminal (V3) schwannoma through endoscopic transpterygoid approach. *Surg Neurol Int* 2019;10:259.
- Ellenbogen RG, Moores LE. Endoscopic management of a pineal and suprasellar germinoma with associated hydrocephalus: Technical case report. *Minim Invasive Neurosurg* 1997;40:13-5.
- Kreth FW, Schätz CR, Pagenstecher A, Faist M, Volk B, Ostertag CB. Stereotactic management of lesions of the pineal region. *Neurosurgery* 1996;39:280-9.
- Roth J, Constantini S. Combined rigid and flexible endoscopy for tumors in the posterior third ventricle. *J Neurosurg* 2015;122:1341-6.
- Yamini B, Refai D, Rubin CM, Frim DM. Initial endoscopic management of pineal region tumors and associated hydrocephalus: Clinical series and literature review. *J Neurosurg* 2004;100:437-41.
- Chibbaro S, Di Rocco F, Makiese O, Reiss A, Poczos P, Mirone G, *et al.* Neuroendoscopic management of posterior third ventricle and pineal region tumors: Technique, limitation, and possible complication avoidance. *Neurosurg Rev* 2012;35:331-38.
- Oi S, Shibata M, Tominaga J, Honda Y, Shinoda M, Takei F, *et al.* Efficacy of neuroendoscopic procedures in minimally invasive preferential management of pineal region tumors: A prospective study. *J Neurosurg* 2000;93:245-53.
- Knaus H, Matthias S, Koch A, Thomale UW. Single burr hole endoscopic biopsy with third ventriculostomy-measurements and computer-assisted planning. *Childs Nerv Syst* 2011;27:1233-41.
- Zhu XL, Gao R, Wong GK, Wong HT, Ng RY, Yu Y, *et al.* Single burr hole rigid endoscopic third ventriculostomy and endoscopic tumor biopsy: What is the safe displacement range for the foramen of Monro? *Asian J Surg* 2013;36:74-82.
- Oppido PA, Fiorindi A, Benvenuti L, Cattani F, Cipri S, Gangemi M, *et al.* Neuroendoscopic biopsy of ventricular tumors: A multicentric experience. *Neurosurg Focus* 2011;30:E2.
- Depreitere B, Dasi N, Rutka J, Dirks P, Drake J. Endoscopic biopsy for intraventricular tumors in children. *J Neurosurg* 2007;106:340-6.
- Ahn ES, Goumnerova L. Endoscopic biopsy of brain tumors in children: Diagnostic success and utility in guiding treatment strategies. *J Neurosurg Pediatr* 2010;5:255-62.
- Oertel JM, Baldauf J, Schroeder HW, Gaab MR. Endoscopic options in children: Experience with 134 procedures. *J Neurosurg Pediatr* 2009;3:81-9.