

Best practice guidelines for arthroscopic intervention in femoroacetabular impingement syndrome: results from an International Delphi Consensus Project—Phase 1

Sarkhell Radha^{1*}, Jonathan Hutt², Ajay Lall³, Benjamin Domb³,
T. Sean Lynch⁴, Damian Griffin⁵, Richard E. Field⁶ and Josip Chuck-Cakic^{7†}

¹Trauma and Orthopaedics, Croydon University Hospital, Croydon District, London CR7 7YE, UK,

²Hip Reconstruction Unit, University College Hospital London, Bloomsbury, London NW1 2BU, UK,

³America Hip Institute, Chicago, IL 60018, USA,

⁴Northwestern University, Chicago, IL 60208, USA,

⁵University Hospitals Coventry and Warwickshire, Clifford Bridge Rd, Coventry CV2 2DX, UK,

⁶Research Department, South West London Elective Orthopaedic Centre, London KT18 7EG, UK and

⁷Fourways Life Hospital, Johannesburg, South Africa.

*Correspondence to: S. Radha. E-mail: Sarkhell.radha1@gmail.com

†All other authors involved in this project are listed in the supplementary author list.

Submitted 13 June 2019; Revised 27 September 2019; revised version accepted 3 October 2019

ABSTRACT

Arthroscopic procedures to treat hip pathologies such as femoroacetabular impingement (FAI) syndrome are now established in mainstream orthopaedic practice. Surgical techniques, rehabilitation protocols and outcomes are widely published. However, consensus on standards of practice remains to be determined. The International Hip Preservation Society (ISHA) has undertaken a research study to identify current areas of consensus across the global hip preservation community. The study focussed on consensus statements on the operative steps in the arthroscopic treatment of FAI syndrome. The study methodology was an online Delphi consensus method to collect aggregate opinions from hip preservation surgeons worldwide. Phase 1 of the planned three-phase study is presented here—focusing on consensus statements on the operative steps in the arthroscopic treatment of FAI syndrome. Ninety-nine statements achieved >80% consensus from a panel of 165 surgeons from six continents. This study is the first to evaluate global consensus on the arthroscopic treatment of FAI syndrome, as well as highlighting areas of contention and avenues for future research.

INTRODUCTION

It has been 15 years since Ganz *et al.* [1] described how femoroacetabular impingement (FAI) syndrome could lead to osteoarthritic degeneration of the hip joint. Arthroscopic surgery for FAI syndrome is undertaken by a global community of surgeons with increasing frequency and continues to evolve. Whilst evidence-based guidance on best practice in FAI syndrome surgery would facilitate consistent information to patients and guidance for surgeons, there is a current lack of prospective randomized studies—this

necessitates other avenues to guide best practice and identify areas where research is required to improve patient care. The level to which current available information and research informs global practice is also unknown. This study was undertaken to evaluate areas of consensus in practice across the global hip preservation community.

The Delphi method is a structured communication technique using a systematic, interactive forecasting method, through a panel of experts. The experts assess statements in multiple rounds of the study process. After

each round, research facilitators use an anonymized summary of the responses to modify statements where there is disagreement for the next iteration—these statements are then presented back to the panel. During this process, the range of the responses diminishes and the group converges towards a consensus on each topic. The Delphi process has been applied in two recent studies on FAI syndrome [2, 3]. The former focussed on the descriptors used in diagnosis whilst the latter, presented at the 2018 Vail Hip Arthroscopy meeting, provided the first US consensus-based Best Practice Guidelines from fifteen high volume US hip arthroscopists. Recognizing the value of this study, Dr Chuck Cacic, the 2017–18 International Hip Preservation Society (ISHA) President, proposed that a global ISHA consensus study would fulfil the World Health Organization (WHO) recommendation that standardized interventions should be developed for patient safety utilizing evidence-based processes and best practice initiatives [4]. The study aim was to utilize a Delphi consensus method to identify whether global consensus-based guidelines for arthroscopic intervention for FAI syndrome could be developed.

MATERIALS AND METHODS

Study participants

All members of ISHA were invited to take part in the study via a link to an online questionnaire circulated via email. ISHA members are surgeons with a special interest in hip preservation surgery. Those who agreed to participate provided details of their geographical region of practice, years of practice and annual and total numbers of hip arthroscopies performed.

Study design

This initial phase of the ISHA Delphi consensus study focussed on the intra-operative steps of arthroscopic treatment for FAI syndrome. A literature search was performed using electronic databases, EMBASE and Medline and Cochrane via the Ovid platform from 1998 until 2018. In addition, grey literature and trial registry searches were conducted using the WHO International Clinical Trials Registry Platform, Current Controlled Trials and the United States National Institute of Health Trials Registry. The National Institute of Health Research (NIHR) Clinical Research Portfolio Database was searched as was the ISI Web of Knowledge and OpenGrey System for Information on Grey Literature in Europe.

A study group was formed to coordinate the proposed work. The group collated a list of potential topics to include along with indicative initial statements. These were reviewed by the ISHA Executive Board Members via an

online survey tool. The ISHA Executive Board Members were asked to rank the topics with regard to their relevance for inclusion on a scale of 1–10, and then to say whether they would put the statement forward in its current form or to offer further suggestions. They were also asked at what percentage level of agreement they would consider consensus to have been achieved. From these results, the study group developed an initial set of 99 statements with a level for consensus set at 80% agreement or higher. An ‘80% agreement or higher’ level of consensus was agreed by the study group following opinion-based discussions and literature review. The content validity ratio (CVR) as described by Lawshe in 1975 was not used in this project. CVR is a linear transformation of a proportional level of agreement. The main benefit of CVR is to readily indicate whether the level of agreement among panel members exceeds 50%. However, as agreement was agreed at 80% or higher, CVR was not needed.

These initial statements were put to the participating wider ISHA members in the weeks preceding the 10th Annual Scientific Meeting in Melbourne, 2018. Online questionnaires were conducted using the Mesydel platform (Seraing, Belgium). Participants were provided with individual encrypted login details and asked to consider each statement using a four-point Likert scale of strongly disagree, disagree, agree and strongly agree. If they disagreed, they were invited to comment and offer an alternative statement to which they could agree. The responses were then analysed anonymously. After each round, those statements that had achieved an 80% consensus on either end of the Likert scale were recorded and removed from subsequent survey rounds. The responses to those that did not reach consensus were reviewed by the study group and used as a basis to reword the statements, which were then put to the participants in a further questionnaire round.

The overall study design is summarized in Fig. 1.

RESULTS

One hundred and sixty-five ISHA members from seven global regions (Table 1) with a mean of 11.5 years (range 2–30 years) in practice registered to participate.

The mean number of hip arthroscopies performed annually was 118 (range 5–450), with a total number of 19 447 per year and 157 443 overall.

Two rounds of the Delphi process were conducted, with a complete response rate from 135 of the 165 registered participants (82%) in each round.

Of the initial set of 99 statements, 81 reached consensus in the first round. Following a review of the results and additional comments, the 18 statements that did not reach consensus were revised as shown in Table II. Following the

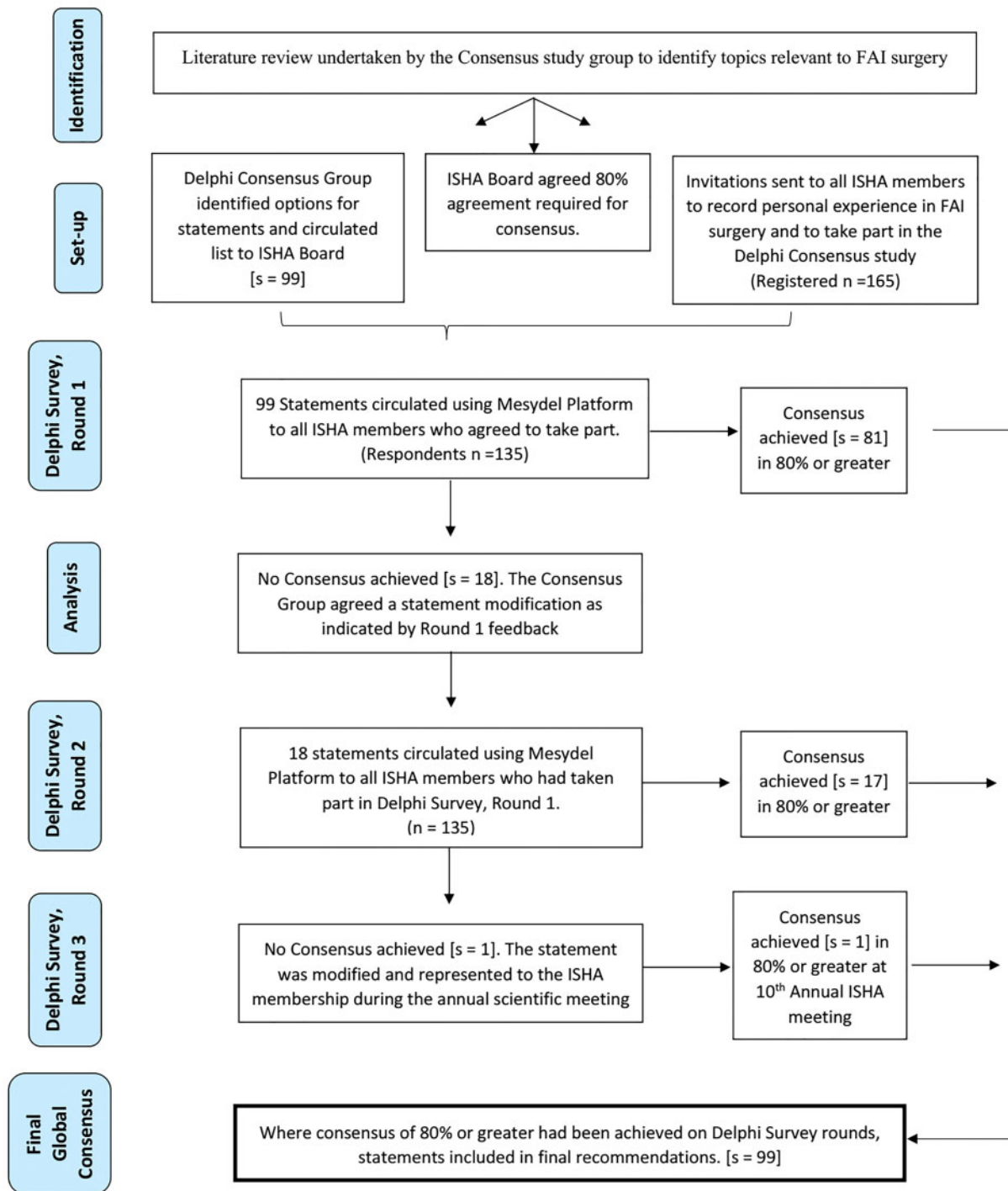


Fig. 1. Delphi survey method.

second round, only one statement did not reach consensus. This statement ‘Labral reconstruction should be avoided in the presence of irreversible chondral damage’, achieved 77.8% consensus. This topic was felt to be of significance, and following review of the comments by the study group,

the same statement was modified to ‘Labral reconstruction is not recommended in the presence of irreversible chondral damage’ and put forward to all ISHA members who routinely perform labral reconstruction surgery at the Annual General Meeting of the 10th ISHA Annual Conference,

Table I. Illustrates the spread of ISHA respondents

Continents	Number of ISHA respondents
Australia and New Zealand	16
Africa	3
North America	50
South America	19
Asia	11
Europe and Middle East	63
Other	3

where 100% consensus was reached. The complete set of consensus statements is shown in [Table III](#).

DISCUSSION

We present the first international consensus on arthroscopic intervention for patients with FAI syndrome. Our expert panel comprised 135 surgeons with expertise in hip preservation surgery, thereby making recommendations easily generalizable. The Delphi technique allowed participants to respond individually and anonymously, thus avoiding many problems associated with live workshops or focus groups, where strong characters or the ‘majority view’ can overwhelmingly dominate. Our chosen method also offered participants the opportunity to review and revise their opinions throughout the process, leaving time for thoughtful reflection and consideration. Three main categories of clinical practice were considered: set up and planning, exposure and closure and treatment of intraoperative findings. After three rounds of survey, and analysis with 135 participants per round, our study achieved consensus at a minimum agreement threshold of 80% on 99 statements pertaining to the treatment of patients diagnosed with FAI syndrome via hip arthroscopy.

The online Delphi consensus technique appears to be a well-established method of harnessing opinions among a diverse group of experts regarding practice-related problems. This technique has previously been used in orthopaedic surgery with promising results. In 2016, Eubank *et al.* [5] used the technique to establish a clinical consensus for the diagnosis and treatment of patients with rotator cuff pathology. More recently, Lynch *et al.* [2] reported best practice guidelines for hip arthroscopy in FAI syndrome using the Delphi process. However, both studies were subject to the significant limitation of sample size, which included a total of 14 and 15 participants, respectively. In comparison, our inclusion of 135 international

participants is, to our knowledge, the largest Delphi consensus study conducted regarding management of FAI syndrome.

The Delphi study group and authors of this study acknowledge there are inherent limitations of this technique. The limitations include potential attrition between rounds, along with the absence of the stimulation and cross-fertilization of ideas that can occur when people meet face-to-face. Additionally, there is a possibility that anonymity could encourage carelessness on the part of participants because they are not publicly accountable for their response. There will also be variability in participants’ expertise in arthroscopic hip surgery. However, this variability can potentially be seen as a study strength since consensus among varying surgical skill levels is imperative when recommending and implementing consensus statements to an international patient population within a relatively new field of surgical practice. In addition, although the authors recognize the role of open surgery in FAI syndrome for the management of complex or non-focal disease, and major acetabular and/or femoral version abnormalities, the standardization of these interventions is beyond the scope of this study.

The authors would like to highlight certain areas covered by the consensus statements with relation to the significant debate within the current literature, in particular, the intraoperative management of the capsule, labrum, cartilage defects, ligamentum teres (LT) and bony impingement.

Capsule

Adequate visualization and access to central and peripheral hip compartments during arthroscopy can present as a challenge. The hip capsule provides both static and dynamic restraint and poor management of this structure could lead to post-operative pain, micro-instability, gross anterior dislocation, heterotopic ossification and seroma formation [6–8]. Optimal management of the hip capsule has therefore been a matter of great debate in literature [9]. Current access techniques include interportal capsulotomy, T capsulotomy and puncture capsulotomy [10]. Not surprisingly, access to the central and the peripheral compartments was a contentious issue during this consensus study ([Table II](#)). After two rounds, there was >80% consensus that formal interportal capsulotomy is not being required for access to central compartment in all cases, which is likely due to the current interest in maintaining hip stability post-operatively. It is generally agreed that capsular repair or plication should be undertaken in situations where large capsulotomies are performed, such as the T—capsulotomy, as well as in cases of dysplasia, or generalized

Table II. Illustrates the statements which not receive consensus after the initial 99 statements and the modified questions

<i>Statements which did not receive consensus</i>	<i>Consensus</i>	<i>Modified Statements</i>	<i>Consensus</i>
Set up and planning			
Every department undertaking arthroscopic surgery for femoroacetabular impingement (FAI) syndrome should have a standardized surgical protocol	77%	Every department undertaking arthroscopic surgery for femoroacetabular impingement (FAI) syndrome should have standardized surgical guidelines	>80%
Exposure and closure			
A formal interportal capsulotomy is not required for optimal central compartment access	64%	Formal interportal capsulotomy is not required for optimal central compartment access in all cases	>80%
In the majority of cases, adequate access to the peripheral compartment can be achieved through capsular puncture and zona expansion.	70%	In some cases, adequate access to the peripheral compartment can be achieved through capsular puncture and zona expansion	>80%
When performing a capsulotomy, division of iliofemoral ligament should be avoided	70%	When performing a capsulotomy, care should be taken to minimize disruption to the iliofemoral ligament	>80%
Assessment of intra-operative findings			
Visualisation of the medial synovial fold	77%	The following features should be routinely documented during the procedure	>80%
Treatment of intra-operative findings			
Labral reconstruction should only be considered in the presence of healthy chondral surfaces	77%	Labral reconstruction should be avoided in the presence of irreversible chondral damage	<80%
For delaminating cartilage flaps, the following treatments should be considered		For delaminating cartilage flaps, the following treatments should be considered	>80%
Repair with fibrin glue or similar	67%	Debridement	>80%
Cartilage transplantation techniques	66%	Microfracture	>80%
Collagen patch	64%	For delaminating cartilage flaps, there is currently no consensus on the use of the following treatments	>80%
		Repair with fibrin glue or similar	>80%

(continued)

Table II. (continued)

<i>Statements which did not receive consensus</i>	<i>Consensus</i>	<i>Modified Statements</i>	<i>Consensus</i>
<p>In cases where there is sufficient labral tissue for reattachment, simple rim recession or labral detachment before rim recession are equally effective</p>	76%	<p>Cartilage transplantation techniques</p> <p>Collagen patch</p> <p>Any treatment for delaminating cartilage flaps should only be considered in cases where the remaining articular cartilage is healthy</p>	<p>> 80%</p> <p>> 80%</p> <p>> 80%</p>
<p>In cases where there is sufficient labral tissue for reattachment, simple rim recession or labral detachment before rim recession are equally effective</p>	76%	<p>In cases where the labrum is preserved, either labral detachment before rim recession or rim recession with preservation of the chondrolabral junction may be undertaken</p>	> 80%
<p>Treatment of intra-operative findings—the following may be helpful in judging the adequacy of rim recession</p>		<p>The following may be helpful in guiding the adequacy of rim recession or cam resection</p>	> 80%
<p>Pre-operative three-dimensional imaging (if available)</p>	79%	<p>Pre-operative three-dimensional imaging (if available)</p>	> 80%
<p>Pre-operative three-dimensional imaging (if available)</p>		<p>Pre-operative motion analysis (if available)</p>	> 80%
<p>Pre-operative three-dimensional imaging (if available)</p>		<p>Intra-operative fluoroscopy (static views)</p>	> 80%
<p>Pre-operative three-dimensional imaging (if available)</p>		<p>Intra-operative fluoroscopy (dynamic views)</p>	> 80%
<p>Pre-operative three-dimensional imaging (if available)</p>		<p>Intra-operative dynamic visual impingement testing</p>	> 80%

Table III. Best practice guidelines for arthroscopic intervention for FAI syndrome

<i>Questions</i>	
Set up and planning	<p>Every department undertaking arthroscopic surgery for femoroacetabular impingement (FAI) syndrome should have a standardized surgical guidelines</p> <p>Anaesthetic technique should be a collaborative decision between surgeon and anaesthetist</p> <p>There is equal validity in undertaking hip arthroscopy in the supine or lateral position</p> <p>The following equipment have always to be available</p> <p>Image Intensifier</p> <p>Perineal post</p> <p>Radiofrequency ablation probes</p> <p>Arthroscopic knife</p> <p>Working portal</p> <p>Fibrin glue</p> <p>Fluid management system</p> <p>Anchors</p> <p>Suture passing instrument</p> <p>Labral allograft</p>
Exposure and closure	<p>Initial viewing portals should be made under image intensifier control</p> <p>Further portals should be made under direct vision</p> <p>An image intensifier should be available as a back-up for making further portals</p> <p>Formal interportal capsulotomy is not required for optimal central compartment access in all cases</p> <p>T capsulotomy maximizes exposure of, and access to, the peripheral compartment</p> <p>In some cases, adequate access to the peripheral compartment can be achieved through capsular puncture and zona expansion</p> <p>When performing a capsulotomy, care should be taken to minimize disruption to the iliofemoral ligament</p>

(continued)

Table III. (continued)*Questions*

Capsular repair is not required in all cases
 The capsule should be repaired in hypermobility
 The capsule should be repaired in mild dysplasia

Assessment of intra-operative findings

The following features should be routinely documented

Condition of the synovium
 Presence of capsulolabral adhesions
 Assessment of capsular laxity

Condition of the labrum

Labral tears

Irritation of the labrum in the psoas groove

Condition of acetabular cartilage

Condition of the ligamentum teres

Condition of the femoral cartilage

Visualisation of the medial synovial fold

Presence and location of a pincer

Presence and location of cam lesion

Presence of subspinous impingement

Treatment of intra-operative findings

The labrum should be repaired rather than debrided whenever possible

There is no proven superiority of any particular labral suturing technique

Labral reconstruction with graft should be considered in the following situations

Absent labrum

(continued)

Table III. (continued)

Questions
Attenuated labrum
Revision surgery with a failure of labral repair
Labral reconstruction should be avoided in the presence of irreversible chondral damage
For delaminating cartilage flaps, the following treatments should be considered
Debridement
Microfracture
For delaminating cartilage flaps, there is currently no consensus on the use of the following treatments
Repair with fibrin glue or similar
Cartilage transplantation techniques
Collagen patch
Any treatment for delaminating cartilage flaps should only be considered in cases where the remaining articular cartilage is healthy
Treating a chondral defect greater than 3 cm ² will seldom result in clinical benefit
In cases where rim recession is required, the first step is to identify whether the remaining labral tissue is sufficient for reattachment
In cases where the labrum is preserved, either labral detachment before rim recession or rim recession with preservation of the chondrolabral junction may be undertaken
The following may be helpful in guiding the adequacy of rim recession or cam resection
Pre-operative 3D imaging (if available)
Pre-operative motion analysis (if available)
Intra-operative fluoroscopy (static views)
Intra-operative fluoroscopy (dynamic views)
Intra-operative dynamic visual impingement testing

hypermobility [2]. The group reached consensus on the statement 'In some cases, capsular puncture and zona expansion may be enough to access peripheral compartment'. This technique has been shown to minimize the risk of instability and persistent pain following hip arthroscopy. Furthermore, capsular closure is not required following this technique, which avoids limitations of range of movement that may occur following capsular closure [10]. Although general agreement exists that attention to capsular management is an important factor in arthroscopic management of FAI syndrome, future high-quality studies are required to determine optimal surgical techniques and post-operative protocols.

Labrum

Labral tears are commonly identified in patients with symptomatic FAI syndrome and surgical treatment of these tears with resection or repair has been proven to be successful [11–16]. Increasingly, however, the literature reports in favour of labral repair rather than debridement due to its perceived benefit to the patient's clinical outcome [17]. It has been reported that labral resection may reduce labral thickness, which can, in turn, disrupt the physiological suction seal between the free edge of labrum and femoral head, thereby impacting static stability of the hip joint [18–24]. As such, the goal of a labral repair is to restore the labral anatomy and re-establish a suction seal around the femoral head and neck [25]. Consensus reached through ISHA Delphi process was that the labrum should be repaired rather than debrided when possible. In the setting of an irreparable labrum, or where it is macerated, attenuated or absent, labral reconstruction may be an alternative to debridement. This may be particularly important in young, active patients to prevent premature cartilage degradation and progression to hip joint osteoarthritis [25–29]. Addressing the fact that not all hip arthroscopists routinely perform labral reconstruction, the ISHA Delphi process was obliged to forward this question to members who routinely perform this procedure. Subsequently, 100% consensus was reached on the statement that labral reconstruction is not recommended in the presence of irreversible chondral damage. Preservation of the native labrum has been shown to have superior patient-reported outcomes when compared to debridement, however, to date, no particular suture configuration or fixation technique has been proven as optimal method. Similarly, long-term studies are needed to determine the outcomes of various labral reconstruction/augmentation techniques that have been developed for both primary and revision hip arthroscopy.

Articular cartilage

Articular cartilage damage is a common finding during hip arthroscopy procedures. Several techniques have been described to address this pathology but within the literature, debridement has been considered essential [30]. Consensus was reached on treating delaminated articular cartilage with both debridement and microfracture on both the acetabulum and femoral head (>80%) during the first round of Delphi. Microfracture was first developed by Steadman [31], addressing articular cartilage defects of the knee with favourable results for full-thickness defects. This technique requires penetration of the subchondral bone, thereby creating a bleeding bone interface and formation of fibrocartilage scar from differentiation of mesenchymal stem cells. This technique is typically reserved for lesions <2 cm [32]. The use of fibrin adhesive is a newly described technique and thus only few studies have published favourable results in the short-term. Nehrer *et al.* [33], published a preliminary clinical study in humans which showed that fibrin glue, in combination with harvested autologous chondrocytes and proprietary growth factor, had good clinical and magnetic resonance imaging results at the one-year follow-up. Tzaveas and Villar [34] also reported that fibrin is a safe and appears to be a viable option for the repair of the delamination-type cartilage. Stafford *et al.* [35], reported 1–3 years of follow-up of patients using fibrin glue combined with microfracture for delaminated acetabular articular cartilage. The fibrin adhesive was used to bond delaminated articular cartilage to the subchondral bone and significant improvement was reported in mean Hip Harris score ($P < 0.0001$) at latest follow-up among 43 patients.

Reflecting what is published in the current literature, our study participants reached consensus that there is currently no agreement on the use of fibrin glue, collagen patch or cartilage transplantation techniques to treat delaminating cartilage injuries. Although some midterm results are encouraging, further long-term comparative studies with larger patient samples are required to draw meaningful conclusions.

Lastly, when treating FAI syndrome patients diagnosed with hip arthroscopy, the overall status of the hip joint must be considered. When chondral damage extends to central and load-bearing areas in the acetabulum with variable thickness, or when femoral head chondral damage shows progressive defibrillation and diffuse pathology, there is limited or no benefit of hip arthroscopy [36]. Consensus of >80% was obtained that any treatment of femoral or acetabular delaminating cartilage flaps should only be considered in cases where the remaining acetabular cartilage is healthy. Furthermore, our study reached

consensus that treating acetabular or femoral chondral defect of $>3\text{ cm}^2$ will seldom lead to clinical benefit. The size and the extent of chondral damage have been reported as important determinants of outcome following hip arthroscopy. McCarthy *et al.* [37], reported 10-year follow-up in 111 patients after hip arthroscopy and described advanced chondral lesions (Outerbridge four types) as an important predictor of the poor outcome. Haviv and O'Donnell [38] reported that 50% of their 564 patients with osteoarthritis stages between Tönnis 1 and 3 who were treated with arthroscopy had to have a THA on average 1.5 years later. Tönnis 3 was among important poor prognostic factors.

Various modifiable (e.g. smoking status, body mass index, generalized ligamentous laxity) and non-modifiable factors (e.g. age, sex, intra-articular cartilage damage) exist in all patients undergoing hip arthroscopy for the management of FAI syndrome. Future studies should help determine both positive and negative factors with statistical methods such as risk factor calculators or predictive models, which can help quantify a patient's projected outcome.

Ligamentum teres

LT pathology is a common finding in patients with FAI syndrome and has been shown to have an incidence as high as 70% [39]. The presence of LT tears in patients with FAI syndrome often indicates overall joint degeneration or underlying hip abnormalities such as microinstability. There is increased interest in assessing LT pathology as well as planning adequate treatment methods during hip arthroscopy. Past recommended treatments vary from simple debridement to thermal shrinkage. More recently, LT reconstruction has been attempted with only short- to mid-term clinical outcomes within the literature [40–42]. The ISHA Delphi process reached consensus ($>80\%$) to consider debridement, thermal shrinkage in patient with LT tears in the setting of FAI syndrome.

Although consensus was achieved on attempting some modalities in the management of LT injuries, there is a paucity of data to support indications for any technique. High-quality biomechanical and long-term comparative outcome studies are needed to determine optimal reconstruction techniques as well as efficacy of treatment techniques.

Bony impingement

Although bony over-resection has been shown to cause hip instability, inadequate resection is more common and is an important cause of persistence of FAI syndrome. Philippon *et al.* and Heyworth *et al.* [43, 44], reported inadequate resection, or failure to fully address bony lesions, as a leading cause for revision cases (92% and 79%, respectively).

Participants of this study reached consensus that when rim recession is required; the first step is to assess viability of labral tissue and to determine if its quality is sufficient for reattachment. Furthermore, there was consensus that in case where the labrum is to be preserved, either labral detachment before rim recession or rim recession with preservation of the chondrolabral junction may be undertaken. Labral detachment prior to pincer resection allows excellent visualization of anterosuperior pincer lesions. Several methods have been used to assess adequacy of bony resection during arthroscopic FAI syndrome management. Depending on availability, this consensus study agreed upon pre-operative three-dimensional imaging, motion analysis, intra-operative fluoroscopy and intra-operative dynamic impingement testing.

Accurate bony resection with the use of pre-operative computed tomography or intra-operative fluoroscopy has been advocated for in most, if not all, hip preservation procedures. High-quality studies are needed to assess newer technologies, which have been shown to improve surgical accuracy and technique, such as computer navigation or robotic-arm assistance.

The creation of these international consensus-based statements is of critical importance, as the use of hip arthroscopy is becoming increasingly utilized. Further studies on the arthroscopic management of FAI syndrome utilizing the Delphi consensus method are underway to look at indications for surgical management as well as post-operative rehabilitation protocols.

CONCLUSION

This Delphi consensus study involved experienced arthroscopic hip surgeons from a diverse international hip preservation community. Three main areas in the arthroscopic treatment of FAI syndrome were considered: set up and planning, exposure and closure and treatment of intra-operative findings. After 3 rounds, 99 consensus statements were produced. We encourage our junior and senior hip arthroscopy colleagues to consider these statements both in an effort to standardize the treatment of FAI syndrome internationally and to aid in the design of future research.

SUPPLEMENTARY DATA

Supplementary data are available at *Journal of Hip Preservation Surgery* online.

ACKNOWLEDGEMENTS

The authors of this would like to thank all the ISHA Board Members who contributed to this International Delphi

Consensus Project—Phase 1. The authors would like to thank The International Hip Preservation Society. The authors of this work would like to thank Irrum Afzal from the South West London Elective Orthopaedic for her hard work in supporting this International Delphi Consensus Project—Phase 1.

FUNDING

This work was supported by the ISHA—The Hip Preservation Society.

CONFLICT OF INTEREST STATEMENT

The authors of this work have no conflicts of interest to declare in relation to this work or publication.

REFERENCES

- Ganz R, Parvizi J, Beck M *et al.* Femoroacetabular impingement: a cause for osteoarthritis of the hip. *Clin Orthop Relat Res* 2003; **413**: 112–20.
- Reiman M, Thorborg K, Covington K *et al.* Important clinical descriptors to include in the examination and assessment of patients with femoroacetabular impingement syndrome: an international and multi-disciplinary Delphi survey. *Knee Surg Sports Traumatol Arthrosc* 2017; **25**: 1975–86.
- Lynch TS, Minkara A, Aoki S, Bedi A *et al.* Best practice guidelines for hip arthroscopy in femoroacetabular impingement: results of a Delphi process. *J Am Acad Orthop Surg* 2019. doi: 10.5435/JAAOS-D-18-00041.
- World Health Organization. The High 5s Project Interim Report. Available at: http://www.who.int/patientsafety/implementation/solutions/high5s/High5_InterimReport.pdf. Accessed 18 January 2019.
- Eubank B, Mohtadi N, Lafave M *et al.* Using the modified Delphi method to establish clinical consensus for the diagnosis and treatment of patients with rotator cuff pathology. *BMC Med Res Methodol* 2016; **16**: 56.
- Harris J, Slikker W, Gupta A *et al.* Routine complete capsular closure during hip arthroscopy. *Arthrosc Tech* 2013; **2**: e89–94.
- Duplantier N, McCulloch P, Nho S *et al.* Hip dislocation of subluxation after hip arthroscopy: a systematic review. *Arthroscopy* 2016; **32**: 1428–34.
- Shu B, Safran MR. Hip instability: anatomic and clinical considerations of traumatic and atraumatic instability. *Clin Sports Med* 2011; **30**: 349–67.
- Harris D. Capsular management in hip arthroscopy. *Clin Sports Med* 2016; **35**: 373–89.
- Conaway W, Martin S. Puncture capsulotomy during hip arthroscopy for femoroacetabular impingement: preserving anatomy and biomechanics. *Arthrosc Tech* 2017; **6**: e2265–9.
- Philippon MJ, Briggs KK, Yen Y-M *et al.* Outcomes following hip arthroscopy for femoroacetabular impingement with associated chondrolabral dysfunction: minimum two-year follow-up. *J Bone Joint Surg* 2009; **91-B**: 16–23.
- Larson CM, Giveans MR. Arthroscopic debridement versus refixation of 101-the acetabular labrum associated with femoroacetabular impingement. *Arthroscopy* 2009; **25**: 369–7.
- Beck M, Leunig M, Parvizi J *et al.* Anterior femoroacetabular impingement: part II. Midterm results of surgical treatment. *Clin Orthop Relat Res* 2004; **418**: 67–73.
- Bedi A, Chen N, Robertson W *et al.* The management of labral tears and femoroacetabular impingement of the hip in the young, active patient. *Arthroscopy* 2008; **24**: 1135–45.
- Byrd JWT, Jones KS. Hip arthroscopy for labral pathology: prospective analysis with 10-year follow-up. *Arthroscopy* 2009; **25**: 365–8.
- Ejnisman L, Philippon MJ, Lertwanich P. Acetabular labral tears: diagnosis, repair, and a method for labral reconstruction. *Clin Sports Med* 2011; **30**: 317–29.
- Carton P, Filan D. Labral cuff refixation in the hip: rationale and operative technique for preserving the chondrolabral interface for labral repair: a case series. *J Hip Preserv Surg* 2018; **5**: 78–87.
- Song Y, Ito H, Kourtis L *et al.* Articular cartilage friction increases in hip joints after the removal of acetabular labrum. *J Biomech* 2012; **45**: 524–30.
- Ferguson SJ, Bryant JT, Ganz R *et al.* An in vitro investigation of the acetabular labral seal in hip joint mechanics. *J Biomech* 2003; **36**: 171–8.
- Cadet ER, Chan AK, Vorys GC *et al.* Investigation of the preservation of the fluid seal effect in the repaired, partially resected, and reconstructed acetabular labrum in a cadaveric hip model. *Am J Sports Med* 2012; **40**: 2218–23.
- Lertwanich P, Plakseychuk A, Kramer S *et al.* Biomechanical evaluation contribution of the acetabular labrum to hip stability. *Knee Surg Sports Traumatol Arthrosc* 2016; **24**: 2338–45.
- Henak C, Ellis B, Harris M *et al.* Role of the acetabular labrum in load support across the hip joint. *J Biomech* 2011; **44**: 2201–6.
- Shibutani N. Three-dimensional architecture of the acetabular labrum—a scanning electron microscopic study. *Nippon Seikeigeka Gakkai Zasshi* 1988; **62**: 321–9.
- Petersen W, Petersen F, Tillmann B. Structure and vascularization of the acetabular labrum with regard to the pathogenesis and healing of labral lesions. *Arch Orthop Traum Surg* 2003; **123**: 283–8.
- Ye K, Singh PJ. Arthroscopic labral repair of the hip, using a through-labral double-stranded single-pass suture technique. *Arthrosc Tech* 2014; **3**: e615–9.
- Kelly BT, Williams RJ III, Philippon MJ. Hip arthroscopy: current indications, treatment options, and management issues. *Am J Sports Med* 2003; **31**: 1020–37.
- Ferguson SJ, Bryant JT, Ganz R, Ito K. The influence of the acetabular labrum on hip joint cartilage consolidation: a poroelastic finite element model. *J Biomech* 2000; **33**: 953–60.
- McCarthy JC, Noble PC, Schuck MR *et al.* The Otto E. Aufranc Award: the role of labral lesions to development of early degenerative hip disease. *Clin Orthop Relat Res* 2001; **393**: 25–37.
- Redmond J, Cregar W, Martin T *et al.* Arthroscopic labral reconstruction of the hip using semitendinosus allograft. *Arthroscopy Techniques* 2015; **4**: e323–9.
- Jannelli E, Fontana A. Arthroscopic treatment of chondral defects in the hip: AMIC, MACI, microfragmented adipose tissue transplantation (MATT) and other options. *SICOT J* 2017; **3**: 43.

31. Rodrigo JJ, Steadman JR, Silliman JF *et al.* Improvement of full thickness chondral defect healing in the human knee after debridement and microfracture using continuous passive motion. *Am J Knee Surg* 1994; **7**: 109–16.
32. Steinwachs M, Guggi T, Kreuz P. Marrow stimulation techniques. *Injury* 2008; **39**: 26–31.
33. Nehrer S, Chiari C, Domayer S *et al.* Results of chondrocyte implantation with a fibrin-hyaluronan matrix: a preliminary study. *Clin Orthop Relat Res* 2008; **466**: 1849–55.
34. Tzaveas A, Villar R. Arthroscopic repair of acetabular chondral delamination with fibrin adhesive. *HIP Int* 2010; **20**: 115–9.
35. Stafford G, Bunn J, Villar R. Arthroscopic repair of delaminated acetabular articular cartilage using fibrin adhesive. Results at one to three years. *Hip Int* 2011; **21**: 744–50.
36. Mella C, Villalón I, Núñez Á *et al.* Hip arthroscopy and osteoarthritis: where are the limits and indications? *SICOT J* 2015; **1**: 27.
37. McCarthy J, Jarrett B, Ojeifo O *et al.* What factors influence long-term survivorship after hip arthroscopy? *Clin Orthop Relat Res* 2011; **469**: 362–71.
38. Haviv B, O'Donnell J. The incidence of total hip arthroplasty after hip arthroscopy in osteoarthritic patients. *Sports Med Arthrosc Rehabil Ther Technol* 2010; **2**, 18.
39. Chahla J, Soares EAM, Devitt BM *et al.* Ligamentum teres tears and femoroacetabular impingement: prevalence and preoperative findings. *Arthroscopy* 2016; **32**: 1293–7.
40. Bardakos NV, Villar RN. The ligamentum teres of the adult hip. *J Bone Joint Surg Br* 2009; **91**: 8–15.
41. Simpson JM, Field RE, Villar RN. Arthroscopic reconstruction of the ligamentum teres. *Arthroscopy* 2011; **27**: 436–41.
42. Philippon MJ, Pennock A, Gaskill TR. Arthroscopic reconstruction of the ligamentum teres: technique and early outcome. *J Bone Joint Surg* 2012; **94**: 1494–8.
43. Philippon MJ, Schenker ML, Briggs KK *et al.* Revision hip arthroscopy. *Am J Sports Med* 2007; **35**: 1918–21.
44. Heyworth BE, Shindle MK, Voos JE *et al.* Radiologic and intraoperative findings in revision hip arthroscopy. *Arthroscopy* 2007; **23**: 1295.