

Comparison of Three Ultrasound Views for Internal Jugular Venous Cannulation in Patients Undergoing Cardiac Surgery: A Randomized Trial

G. N. Chennakeshavallu, Shrinivas Gadhinglajkar*, Rupa Sreedhar, Saravana Babu, Sruthi Sankar, Prasanta Kumar Dash

Department of Cardiac Anesthesia, Sree Chitra Tirunal Institute for Medical Sciences and Technology, Thiruvananthapuram, Kerala, India

Abstract

Background: The quality of needle visualization during ultrasound-guided internal jugular vein (IJV) cannulation determines the ease of procedure, whereas posterior IJV wall puncture is the most common risk associated. The IJV can be imaged in different views, which offer certain advantages over each other. We compared three different ultrasound views for IJV cannulation short axis (SAX), long axis (LAX), and oblique axis (OAX) with respect to the quality of needle visualization, first pass success rate, and posterior IJV wall puncture. **Methods:** Two hundred ten patients undergoing elective cardiac surgery were analyzed in this prospective randomized clinical trial. Patients were randomly assigned to one of the three groups: SAX ($n = 70$), LAX ($n = 70$), and OAX ($n = 70$). The quality of needle visualization, first pass success rate, and incidence of posterior IJV wall puncture in each of the three ultrasound views were studied. The Chi-square test and ANOVA were used for the comparison of means and proportion between the groups. **Results:** The quality of needle visualization was graded as good in 90% patients in OAX group, 81.4% patients in LAX group, and 14.2% patients in SAX group, respectively ($P < 0.0001$). OAX group had the highest first pass success rate (94.2%) followed by SAX (88.5%), and then, LAX (82.8%), but it was statistically insignificant among the groups ($P = 0.105$). The mean IJV access time was longer in LAX group when compared to OAX and SAX group ($P < 0.0001$). The incidence of IJV posterior wall puncture was 14.2% patients in SAX group and none in other groups ($P = 0.0011$). **Conclusion:** The results suggest that OAX view can be adopted as standard approach during ultrasound-guided IJV cannulation as it safe and reliable.

Keywords: Internal jugular venous, ultrasound, views

INTRODUCTION

Internal jugular vein (IJV) cannulation is a commonly performed procedure in the perioperative period for monitoring central venous pressure, administration of vasoactive drugs, and rapid fluid resuscitation. The IJV cannulation can be performed either by landmark technique or under ultrasound guidance. The reported success rate in the landmark technique varies between 60% and 95%, whereas the incidence of complications occurs more often with less experienced operators.^[1,2] Ultrasound facilitates direct visualization of the IJV, and assessment of its dimension, orientation, and surrounding structures resulting in improved first pass success rate, reduced number of needle passes, and less inadvertent injury to surrounding structures.^[3,4] The National Institute for Clinical Excellence (NICE) published guidelines supporting the routine

use of ultrasound guidance for IJV cannulation.^[5] The IJV can be imaged under ultrasound in different three orientations: short axis (SAX), long axis (LAX), and oblique-axis view (OAX).^[6,7] There are several advantages and disadvantages with each of these approaches. Although numerous studies have shown significant benefits of using real-time ultrasound for IJV cannulation, only a few studies have compared these three ultrasound views for IJV cannulation. Hence, we undertook this study with the primary objective of comparing the SAX, LAX, and OAX in terms of quality of needle visualization, first pass success rate, and incidence of posterior venous wall

Address for correspondence: Dr. Shrinivas Gadhinglajkar, Department of Cardiac Anesthesia, Sree Chitra Tirunal Institute for Medical Sciences and Technology, Thiruvananthapuram - 695 011, Kerala, India. E-mail: drgadhinglajkar@gmail.com

Received: 11-07-2020 Revised: 15-09-2020 Accepted: 21-10-2020 Available Online: 11-02-2021

Access this article online

Quick Response Code:



Website:
www.jmuonline.org

DOI:
10.4103/JMU.JMU_135_20

This is an open access journal, and articles are distributed under the terms of the Creative Commons Attribution-NonCommercial-ShareAlike 4.0 License, which allows others to remix, tweak, and build upon the work non-commercially, as long as appropriate credit is given and the new creations are licensed under the identical terms.

For reprints contact: WKHLRPMedknow_reprints@wolterskluwer.com

How to cite this article: Chennakeshavallu GN, Gadhinglajkar S, Sreedhar R, Babu S, Sankar S, Dash PK. Comparison of three ultrasound views for internal jugular venous cannulation in patients undergoing cardiac surgery: A randomized trial. J Med Ultrasound 2021;29:176-80.

puncture. The secondary objective of the study was to evaluate the incidence of complications.

MATERIALS AND METHODS

This prospective, randomized, controlled trial was approved by the Institutional Ethics Committee (SCT/IEC/1012/December 2016) and was registered with the Clinical Trials Registry of India (CTRI/2018/03/012705). After obtaining written informed consent, 210 patients aged between 18 and 65 years undergoing elective cardiac surgery were included in this trial. Patients who had a history of previous neck surgeries, neck tumors, coagulopathy, carotid artery disease, and severe left ventricular dysfunction (left ventricular ejection fraction < 30%) were excluded. Patients were assigned to one of the three groups (SAX, LAX, and OAX) comprising of seventy patients in each group using a computer-generated randomization table and allocation was done using sealed-opaque envelope technique. All the IJV cannulation of the study participants were performed in the operating room by three anesthesiologists who had successfully performed at least fifty ultrasound-guided IJV procedures using these three approaches. In the operation room, after the induction of general anesthesia and establishing monitoring as recommended by the American Society of Anesthesiologists, right IJV cannulation was carried out in all patients under aseptic precautions. Patients were placed in Trendelenburg position with the head turned slightly toward the left side (30–40° from mid line). Imaging of the IJV was done using MyLab™One/Touch ultrasound system with the probe frequency of 6–13 MHz. The probe was covered with a sterile sheath after applying sterile ultrasound gel to the inner portion of the sheath. Both the ultrasound transducer and puncture needle were handled by a single operator during the procedure.

In SAX group, short-axis view of IJV was obtained by placing the probe transversely over the neck. Once the vein was centralized in the middle of the ultrasound image, the needle puncture was made in a plane perpendicular to the long axis of the transducer [Figure 1a]. In LAX group, long-axis view of the vein was achieved by placing the transducer longitudinally over the neck, and the vein was identified and centralized in the ultrasound image. The needle was then inserted just underneath the probe from the cranial to caudal direction [Figure 1b]. In OAX group, the OAX view was attained by rotating the probe from SAX to a position of mid-way between the SAX and LAX views. Subsequently, the needle was inserted underneath the footprint of the probe from the lateral to medial direction [Figure 1c]. In all the three groups, ultrasound navigation (rocking the probe) was employed to obtain the best possible image of the needle entering the IJV, along with the aspiration of venous blood into the syringe. Intraluminal guide-wire position was confirmed with ultrasound and Seldinger technique was employed for catheter insertion. The following outcomes of the study were recorded: (1) quality of needle visualization (Good – needle shaft and tip visualized; Adequate – needle tip visualized; and Poor – only tissue indentation seen), (2) first pass success rate (the cannulating

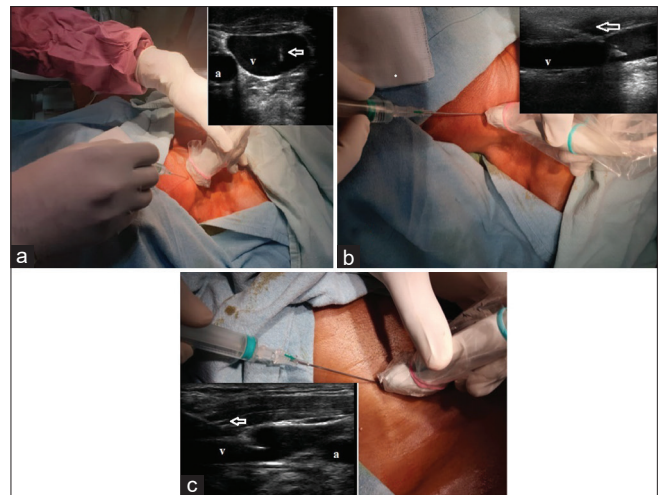


Figure 1: Ultrasound transducer orientation and needle insertion with corresponding ultrasound images showing the quality of needle visualized. (a) Short-axis view. (b) Long-axis view. (c) Oblique-axis view. a: Carotid artery, v: Internal jugular vein, Arrows: Quality of needle visualized

needle was advanced forward into IJV without any backward movement at first attempt), (3) IJV access time (defined as time from skin puncture with introducer needle to free aspiration of venous blood into the syringe), (4) indentation of anterior wall of IJV > 50% of its diameter (diameter of IJV is reduced by more than 50% at the time of puncture), (5) incidence of IJV posterior IJV wall puncture (defined as inability to obtain free aspiration of venous blood or inability to advance the guidewire freely once the operator had initially identified the needle tip using real-time ultrasound in lumen of IJV), and^[6] incidence of complications such as carotid artery puncture, neck hematoma, and arrhythmias. In our study, cannulation was considered successful if guidewire was advanced without resistance and detected inside the IJV ultrasonographically. Cannulation failure was defined if guidewire could not be inserted in three needle passes and an alternative approach was used for IJV cannulation. All patients were followed up with chest radiograph in the postoperative period to detect catheter misplacement.

Statistical analysis

Sample size calculation was based on a previous study by Batllori *et al.*^[8] where first pass success rate was compared as primary outcome with an alpha level of 0.05 and power of 80%. To find a significant difference in the first pass success rate of around 20% between the groups, we enrolled seventy patients in each group. Patient's characteristics and outcome measures are presented using the number and percentages for the categorical variables. The quantitative data were presented as mean ± standard deviation. Kolmogorov–Smirnov test was used to test the normality of the variables.

The Chi-square test was used to analyze the categorical variables. Continuous variables were compared using the ANOVA. $P < 0.05$ was considered statistically significant. The analysis was conducted using the SPSS for Windows (version 22.0; SPSS Inc., Chicago, IL, USA).

RESULTS

A total of 225 patients were eligible for the study. Five patients refused to participate and 10 patients did not meet the inclusion criteria (four patients had severe left ventricular dysfunction, four patients had coagulopathy, and two patients had associated carotid artery stenosis). Hence, 210 patients were randomized and analyzed in this study with 70 patients in each group [Figure 2]. There was no significant difference in the demographic variables among the groups [Table 1]. The mean age and mean IJV diameter of the subjects involved in the study were 55.2 ± 14.1 years and 8.8 ± 1.3 mm, respectively. The primary outcome parameters of the study compared between the groups are given in Table 2 and Figure 3.

Although the first needle pass success rate was the highest in OAX group (94.2%) followed by SAX (88.5%) and then LAX (82.8%) groups, the data were statistically insignificant among the groups. The quality of needle visualization during ultrasound-guided cannulation was graded as good in 90% patients in OAX group, 81.4% patients in LAX group and in 14.2% patients in SAX group. Visualization of the needle was classified as adequate in 77.1% patients in SAX group, 18.5% patients in LAX group, and in 10% patients in OAX

Table 1: Demographic profile of the patients in different groups

	SAX (n=70)	LAX (n=70)	OAX (n=70)	P
Age (years)	54.21±14.08	55.83±14.39	55.80±14.08	0.743
Sex (male/ female)	52/18	47/23	52/18	0.555
BMI	25.29±4.24	25.26±3.71	25.26±3.39	0.999
IJV diameter (mm)	9.4±1.7	8.5±1.2	8.5±1.1	0.370

Results are presented as mean±SD and proportions. Chi-square test and ANOVA were applied for comparison between groups. SAX: Short axis, LAX: Long axis, OAX: Oblique axis, BMI: Body mass index, IJV: Internal jugular vein, SD: Standard deviation

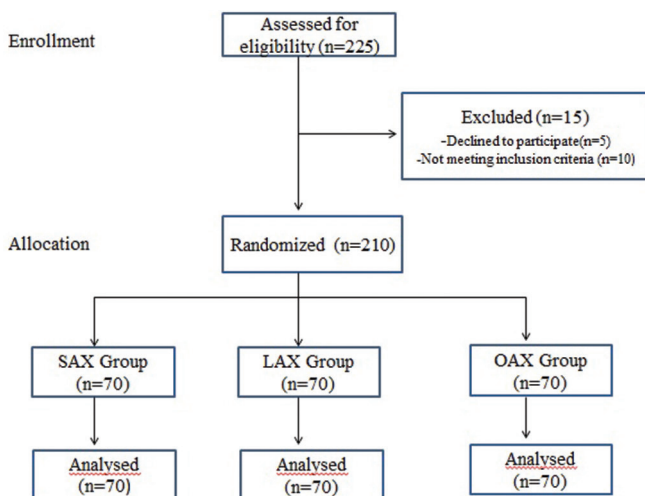


Figure 2: Consolidated standards of reporting trials flow diagram of participants through each stage of randomized trial

group. In SAX group, seven patients had poor quality of needle visualized. There was a statistically significant difference between LAX group and SAX group and also between OAX group and SAX group with respect to the quality of needle visualization ($P < 0.0001$). The mean IJV access time was longer in LAX group (17.62 ± 5.97 s) when compared with OAX (11.85 ± 2.73) and SAX (11.07 ± 2.93) with a statistically significant difference ($P < 0.0001$). The indentation of anterior wall of IJV $> 50\%$ was observed in 14 (20%) patients in SAX and none in other groups ($P = 0.0001$). Similarly, the incidence of IJV posterior wall puncture was the highest in SAX (14.2%) where none of the patients in other groups had posterior wall puncture ($P = 0.0011$). In LAX group, two patients had carotid artery puncture which was statistically insignificant ($P = 0.058$) when compared with other groups [Table 3]. In our study, all IJV cannulation were successful, and they were performed on the side and ultrasound view initially chosen by the investigators.

DISCUSSION

Ultrasound has been recommended as a standard of care for IJV cannulation by the American Society of Echocardiography (ASE) and NICE.^[1,5] A meta-analysis demonstrated that ultrasound-guided IJV cannulation clearly reduces the number of complications, failures, and time required for cannulation.^[9] SAX, LAX, and OAX views are the three different approaches commonly described for USG-guided IJV. Each of these techniques has its own merits and demerits. The SAX view facilitates the better visualization of surrounding structures and their positions relative to the needle (especially the carotid artery) so that it becomes easier to direct the needle toward the target vessel, away from the carotid artery. However, SAX view does not image the entire needle pathway or provide an appreciation of insertion depth.^[10] The LAX view provides the visualization of the needle throughout its course and depth of insertion, as significant portion of the needle shaft and tip are imaged within the ultrasound imaging

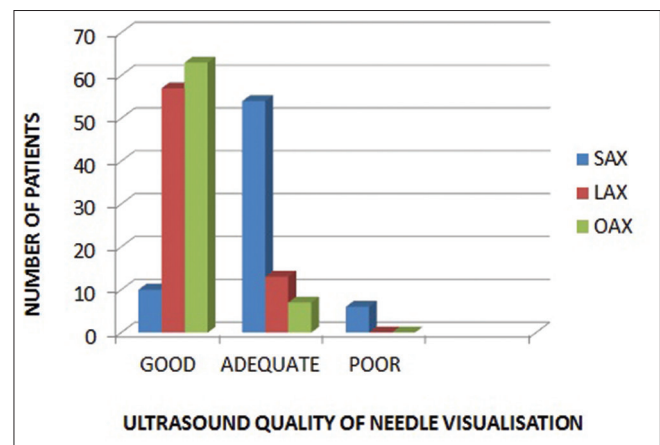


Figure 3: Ultrasound quality of needle visualization among three groups. The results are expressed as numbers. The Chi-square test was applied. There was a statistically significant difference between short axis and long axis groups ($P < 0.0001$) and between short axis and long axis groups ($P < 0.0001$)

Table 2: Ultrasound/catheterization characteristics among the three groups

	SAX (n=70)	LAX (n=70)	OAX (n=70)	P
First needle pass success rate (%)*	62 (88.5)	58 (82.8)	66 (94.2)	0.105
Number of needle passes (1/2/3)*	62/8/0	58/8/4	66/4/0	0.105
IJV access time (s) [#]	11.07±2.93	17.62±5.97	11.85±2.73	<0.0001 ^{ab}
Anterior wall indentation of IJV >50%* (%)	14 (20)	0	0	0.0001 ^{ac}
Posterior IJV wall puncture* (%)	10 (14.2)	0	0	0.0011 ^{ac}

Results are presented as mean±SD and percentages. *Chi-square and [#]ANOVA was applied for comparison between the groups, ^aSignificant between groups SAX and LAX, ^bSignificant between groups LAX and OAX, ^cSignificant between groups SAX and OAX. SAX: Short axis, LAX: Long axis, OAX: Oblique axis, SD: Standard deviation, IJV: Internal jugular vein

Table 3: Complications among the three groups

	SAX (n=70)	LAX (n=70)	OAX (n=70)	P
Arterial puncture	0	2	0	0.058
Hematoma	0	0	0	-
Arrhythmias	0	0	0	-

SAX: Short axis, LAX: Long axis, OAX: Oblique axis

plane, thereby avoiding the insertion of needle beyond the target vessel. However, as the surrounding structures are not visualized with LAX view, it becomes difficult to discern if the needle overlies the artery or vein.^[11] The OAX view not only allows better visualization of the needle shaft and tip, but also offers the benefit of simultaneous visualization of surrounding structures in the same view, thus overcoming the drawbacks of both the SAX and LAX approaches.^[6]

The main objective of this study was to determine the most favorable scanning axis for the vascular access. Improved visualization of the needle during ultrasound-guided IJV cannulation facilitates the success of cannulation rate and prevents the incidence of complications. Hence, we compared the quality of needle visualization among the groups using an objective scale (good/adequate/poor). We found that although the incidence of first needle pass success rate was statistically insignificant among the groups, there were differences with respect to the quality of needle visualization. The visibility of needle on the ultrasound image (quality of needle visualization) was the best in OAX and LAX when compared to SAX. Stone *et al.*^[12] have also reported improved visibility of the needle tip with LAX approach in a simulated vascular access model. Chapman *et al.*^[13] found that the needle visualization was better in LAX view as the needle traverses more perpendicular to the ultrasound beam and the image of the needle can be constructed by aligning multiple dots.

In our study, the success rate of first needle pass was higher in OAX group (94.2%) followed by SAX group (88.5%) and then LAX group (82.8%). Although the ultrasonic imaging of needle was better appreciated in LAX group than SAX group, this did not translate into higher first pass success in LAX group. This may be attributed to the limitations of operator in maintaining the alignment between the ultrasound transducer and the needle. Our findings were consistent with a study published by Batllori *et al.*^[8] wherein the authors reported the cannulation success rate on first needle pass of 69.9%, 52%, and 73.6% in patients in

SAX group, LAX group, and OAX group, respectively, which was statistically significant ($P < 0.005$). A statistically significant higher success in first pass cannulation using SAX view (98%) than LAX view (78%) was also reported by Chittoodan *et al.*^[14] Baidya *et al.* compared the SAX and OAX approach using ultrasound-guided right IJV cannulation in 200 patients.^[15] Similar to our study, they noticed that first attempt success rate was higher in OAX group (87%) than the SAX group (85%), although it was statistically insignificant ($P = 0.538$). In contrast to our findings, Chaudhari *et al.*^[16] have observed a higher first pass needle success rate in LAX view (92%) as compared to SAX view (76%), but the difference was statistically insignificant ($P = 0.128$), which could be associated with a small sample size and limited experience of the operator. We found that the mean IJV access time was shorter in SAX and OAX group when compared with LAX group ($P < 0.0001$). In agreement with our study, shorter venous access time was reported by Stone *et al.*^[12] in SAX group (12.4s) when compared with LAX (14.8s) but it was statistically insignificant ($P = 0.48$). The longer access time in LAX group is attributed to the need for aligning the needle in the plane of ultrasound.

The incidence of posterior wall puncture of IJV in our study population was 14.2% of patients in SAX group. This high incidence may be because, in SAX approach, the needle is mostly visualized as an echogenic point, which may not necessarily represent the needle tip. Hence, accurate detection of needle tip puncturing the posterior IJV wall may not be possible in all patients. Improved visualization of the tip during the needle advancement probably prevented the occurrence of posterior wall puncture in both LAX and OAX groups. Similar results were obtained in the study by Batllori *et al.*^[8] where they reported higher incidence of posterior wall puncture in SAX group ($P < 0.001$). Srinivasan *et al.*^[17] in their study concluded that real-time USG-guided IJV cannulation reduces but does not wholly eliminate the incidence of posterior venous wall penetrations. A novel combined SAX and LAX approach has been suggested by Takeshita *et al.*^[18] in which the needle is launched visualizing the target vein in the SAX view. After visualizing the needle tip between the skin surface and anterior wall of the target vein in the midline axis, the probe is then rotated by 90° to visualize the entire length of the needle and target vein in the LAX view to reduce the incidence of posterior IJV wall puncture. However, this approach requires multiple needle direction and a considerable learning curve.

In SAX group, 14 patients had significant indentation of the anterior wall of IJV which is defined as >50% reduction in IJV diameter. Most of the patients who had posterior IJV wall puncture in SAX group had significant indentation of anterior wall during cannulation. Yoshida *et al.*^[19] reported that patients with small IJV diameter and long anterior venous wall tenting are the risk factors for posterior wall puncture.

In our study, two patients in LAX group had inadvertent carotid artery puncture, whereas none in other groups developed this complication. As both the vein and artery were visualized simultaneously on the screen in both SAX and OAX group, we had a better control on needle advancement that could prevent carotid artery puncture in these groups. Similar observation was made by Chittoodan *et al.*^[14]

However, in contrast to our study, meta-analysis of randomized trial comparing the three views for ultrasound-guided IJV cannulation revealed that there were no clinically significant differences between these approaches with respect to first pass success rate, number of needle passes, incidence of carotid artery puncture, and posterior IJV wall puncture.^[20,21]

Limitations

Our study has some limitations. Investigators who participated in our study were experts in ultrasound-guided IJV cannulation; therefore, our results may not be applicable to the novice operators. Although we tried to devise an objective grading scale based on the quality of ultrasonic visualization of the needle, we could not exclude an element of individual interpretation. Further, large randomized studies involving less-experienced operators, who will evaluate the results of ultrasound-guided IJV cannulation as guided by the above grading scale, are necessary to strengthen our findings. Differences in the ability of each operator in performing IJV cannulation using each of these ultrasound views were not compared and can be possible source of bias in this study. The results of our study may be different under emergent circumstances such as in patients with hypovolemic shock because of collapsed IJV diameter.

CONCLUSION

The OAX view has good quality of needle visualization, less incidence of posterior wall puncture, and higher first-needle pass success rate. Hence, we recommend this view to be adopted as a standard approach during ultrasound-guided IJV cannulation.

Financial support and sponsorship

Nil.

Conflicts of interest

There are no conflicts of interest.

REFERENCES

1. Troianos CA, Hartman GS, Glas KE, Skubas NJ, Eberhardt RT, Walker JD, *et al.* Guidelines for performing ultrasound guided vascular cannulation: Recommendations of the American Society of Echocardiography and the Society of Cardiovascular Anesthesiologists. *J Am Soc Echocardiogr* 2011;24:1291-318.
2. Lamperti M, Bodenham AR, Pittiruti M, Blaivas M, Augoustides JG, Elbarbary M, *et al.* International evidence-based recommendations on ultrasound-guided vascular access. *Intensive Care Med* 2012;38:1105-17.
3. Karakitsos D, Labropoulos N, De Groot E, Patrianakos AP, Kouraklis G, Poularas J, *et al.* Real-time ultrasound-guided catheterisation of the internal jugular vein: A prospective comparison with the landmark technique in critical care patients. *Crit Care* 2006;10:R162.
4. Milling TJ Jr., Rose J, Briggs WM, Birkhahn R, Gaeta TJ, Bove JJ, *et al.* Randomized, controlled clinical trial of point-of-care limited ultrasonography assistance of central venous cannulation: The Third Sonography Outcomes Assessment Program (SOAP-3) Trial. *Crit Care Med* 2005;33:1764-9.
5. National Institute for Clinical Excellence. Guidance on the use of Ultrasound Locating Devices for Placing Central Venous Catheters. NICE Technical Report Number 492002. Available from: <http://www.nice.org.uk/nicemedia/live/11474/32461>. [Last accessed on 2014 May 08].
6. Phelan M, Haggerty D. The oblique view: An alternative approach for ultrasound-guided central line placement. *J Emerg Med* 2009;37:403-8.
7. Tammam TF, El-Shafey EM, Tammam HF. Ultrasound-guided internal jugular vein access: Comparison between short axis and long axis techniques. *Saudi J Kidney Dis Transpl* 2013;24:707-13.
8. Batllori M, Urrea M, Uriarte E, Romero C, Pueyo J, López-Olaondo L, *et al.* Randomized comparison of three transducer orientation approaches for ultrasound guided internal jugular venous cannulation. *Br J Anaesth* 2016;116:370-6.
9. Hind D, Calvert N, McWilliams R, Davidson A, Paisley S, Beverley C, *et al.* Ultrasonic locating devices for central venous cannulation: Meta-analysis. *BMJ* 2003;327:361.
10. Blaivas M, Adhikari S. An unseen danger: Frequency of posterior vessel wall penetration by needles during attempts to place internal jugular vein central catheters using ultrasound guidance. *Crit Care Med* 2009;37:2345-9.
11. French JL, Raine-Fenning NJ, Hardman JG, Bedforth NM. Pitfalls of ultrasound guided vascular access: the use of three/four-dimensional ultrasound. *Anaesthesia* 2008;63:806-13.
12. Stone MB, Moon C, Sutijono D, Blaivas M. Needle tip visualization during ultrasound-guided vascular access: short-axis vs. long-axis approach. *Am J Emerg Med* 2010;28:343-7.
13. Chapman GA, Johnson D, Bodenham AR. Visualisation of needle position using ultrasonography. *Anaesthesia* 2006;61:148-58.
14. Chittoodan S, Breen D, O'Donnell BD, Iohom G. Long versus short axis ultrasound guided approach for internal jugular vein cannulation: a prospective randomised controlled trial. *Med Ultrason* 2011;13:21-5.
15. Baidya DK, Arora MK, Ray BR, Mohan VK, Anand RK, Khanna P, *et al.* Comparison between short axis and medial oblique view for ultrasound guided internal jugular vein cannulation: A randomized controlled trial. *Acta Anaesth Belg* 2018;69:107-12.
16. Chaudhari MS, Shah SB, Kamat HV. Ultrasound guided internal jugular vein cannulation with short and long axis approach. Technical ease and complications. *Indian J Clin Anaesth* 2016;3:546-50.
17. Srinivasan S, Govil D, Gupta S, Patel S, Jagadeesh KN, Tomar DS. Incidence of posterior wall penetration during internal jugular vein cannulation: A comparison of two techniques using real-time ultrasound. *Indian J Anaesth* 2017;61:240-4.
18. Takeshita J, Nishiyama K, Fukumoto A, Shime N. Combined approach versus 2 Conventional approaches in ultrasound-guided central venous catheterization: A Randomized Controlled Trial. *J Cardiothorac Vasc Anesth* 2019;33:1029-34.
19. Yoshida H, Yaguchi S, Itaya H, Ito K, Hatanaka R, Nakai K, *et al.* Cannulation needle-induced anterior wall tenting of internal jugular vein causing posterior wall penetration. *J Anesthesia* 2014;29:467-70.
20. Maitra S, Bhattacharjee S, Baidya D. Comparison of long-, short-, and oblique-axis approaches for ultrasound-guided internal jugular vein cannulation: A network meta-analysis. *J Vasc Access* 2020;21:204-9.
21. Chen JY, Wang LK, Lin YT, Lan KM, Loh EW, Chen CH, *et al.* Comparing short-, long- and oblique-axis approaches to ultrasound-guided internal jugular venous catheterization: A meta-analysis of randomized controlled trials. *J Trauma Acute Care Surg* 2019;86:516-23.