

# A sewing needle in contact with the cervical dura mater and vertebral artery

## A case report

Arizumi Fumihiro, MD\*, Inoue Shinichi, MD, PhD, Tachibana Toshiya, MD, PhD, Maruo Keishi, MD, PhD, Yoshiya Shinichi, MD, PhD

### Abstract

**Rationale:** Although cervical foreign bodies have been previously reported, the report of a needle in the cervical spinal cord is rare. Herein, we report a rare case of a sewing needle in contact with the cervical dura mater and vertebral artery.

**Patients concerns:** A 47-year-old man presented with discomfort in the posterior region of his neck. Approximately 2 years before admission, he suffered a stiff neck and had stabbed the posterior region of his neck with a sewing needle. The sewing needle had deeply entered his neck, and he left it alone because it could not be identified or removed. On examination, the patient had a full range of neck motion, but was experiencing discomfort. Cervical spine radiographs revealed a metal foreign body oriented from between the C2 and C3 spinous processes to the anterior cervical spine.

**Diagnosis:** Computed tomography (CT) myelogram and CT angiogram revealed that the sewing needle was penetrating into the foramen transversarium and was in contact with the cervical dura mater and the right vertebral artery.

**Interventions:** The sewing needle was removed under general anesthesia.

**Outcomes:** Cerebrospinal fluid leakage occurred immediately after removal of the needle. Symptoms of discomfort disappeared without any complications.

**Lessons:** This is the first report of a sewing needle that entered the cervical spinal canal while avoiding the cervical spine and the vertebral artery. Although no symptoms occurred for nearly 2 years, surgical removal of a foreign body near the cervical spinal cord and vertebral artery should be performed as soon as possible, before the occurrence of symptoms.

**Abbreviations:** CSF = cerebrospinal fluid, CT = computed tomography.

**Keywords:** case report, cervical spine, foreign body, sewing needle, vertebral artery

## 1. Introduction

Penetrating injury is a commonly observed condition in daily medical practice. Needles have been identified as foreign bodies in the distal regions of the extremities as well as in the heart,<sup>[1]</sup> lung,<sup>[2]</sup> and liver.<sup>[3]</sup> Cervical foreign bodies have been previously reported, but the report of a foreign body in the cervical spine is rare. Herein, we report an unusual case involving a sewing needle that had been stabbed into the neck by the patient.

In our case, the patient signed related informed consent for the publication of clinical data and images.

Editor: Bernhard Schaller.

The authors have no conflicts of interest to disclose.

Department of Orthopedic Surgery, Hyogo College of Medicine, Hyogo, Japan.

\* Correspondence: Arizumi Fumihiro, Department of Orthopedic Surgery, Hyogo College of Medicine, 1-1, Mukogawacho, Nishinomiya, Hyogo 663-8501, Japan (e-mail: f\_ali\_14@yahoo.co.jp)

Copyright © 2016 the Author(s). Published by Wolters Kluwer Health, Inc. This is an open access article distributed under the terms of the Creative Commons Attribution-Non Commercial-No Derivatives License 4.0 (CCBY-NC-ND), where it is permissible to download and share the work provided it is properly cited. The work cannot be changed in any way or used commercially without permission from the journal.

Medicine (2016) 95:52(e5764)

Received: 9 August 2016 / Received in final form: 30 November 2016 /

Accepted: 1 December 2016

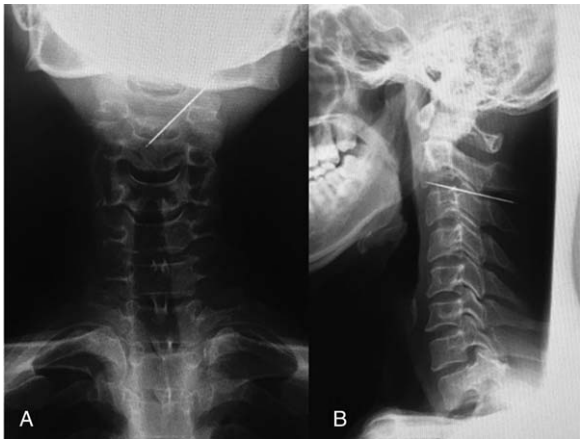
<http://dx.doi.org/10.1097/MD.0000000000005764>

## 2. Case presentation

A 47-year-old man presented with discomfort in the posterior region of his neck. His medical history included schizophrenia and hypospadias. Approximately 2 years before admission, he experienced a stiff neck and stabbed the posterior region of his neck with a sewing needle. He reported that the sewing needle entered his neck deeply, and he left it alone because it could not be identified or removed. Thereafter, he did not experience any symptoms until the recent discomfort.

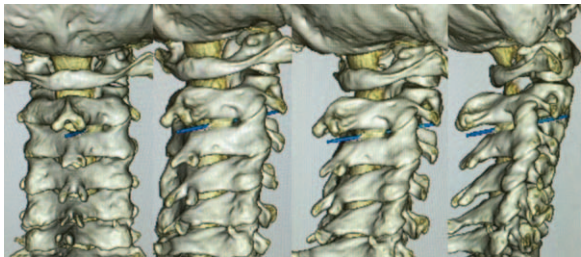
Examination of the puncture site did not reveal an obvious entry point. He had a full range of neck motion, but experienced neck discomfort. Neurological examination did not reveal any abnormalities. Posteroanterior and lateral cervical spine radiographs revealed a metal foreign body (presumably the sewing needle), measuring about 5 cm, running from between the C2 and C3 spinous processes to the anterior cervical spine (Fig. 1). A cervical spine computed tomography (CT) myelogram and CT angiogram revealed that the sewing needle had penetrated into the foramen transversarium and was in contact with wall of the cervical dura mater and was passing near the right vertebral artery (Figs. 2–4). Magnetic resonance imaging was not performed due to the contraindicated nature of the foreign body. We decided to operate on this patient to remove the needle, because if this condition persisted, it could lead to potential damage to the spinal cord and vertebral artery.

Removal of the foreign body was performed under general anesthesia. A 3-cm incision was made at the midline of the neck,



**Figure 1.** Posteroanterior (A) and lateral (B) cervical spine radiographs revealing the embedded sewing needle.

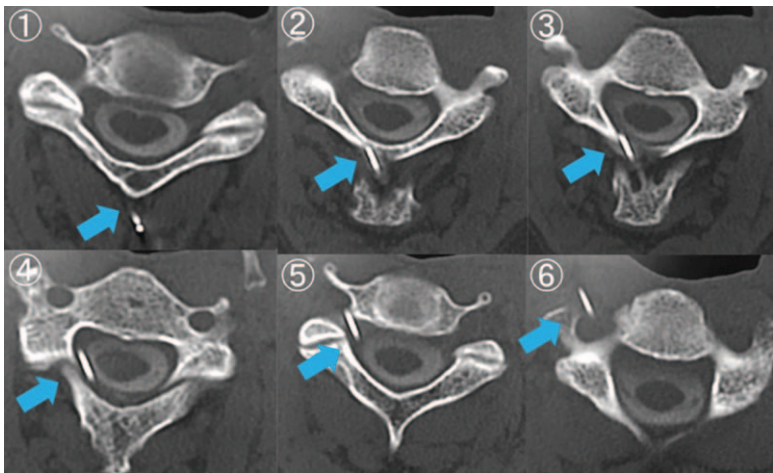
and the tip of the needle was identified and easily extracted after the exposure of the C2 and C3 spinous processes; however, cerebrospinal fluid (CSF) leakage occurred immediately after removal. CSF leakage repair was performed by suturing the



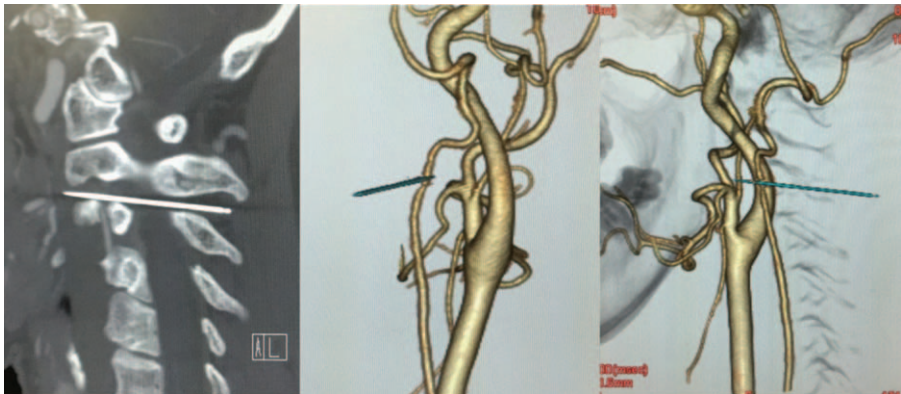
**Figure 2.** Three-dimensional computed tomography myelograms demonstrating the orientation of the sewing needle from between the C2 and C3 spinous processes to the anterior cervical spine.

ligamentum nuchae tightly. The CSF leak indicated that the needle was in contact with the dura mater.


The removed sewing needle was completely covered with rust (Fig. 5). The microbiological study of the needle was not performed. The patient’s postoperative course was uneventful; following 3 days of antibiotic therapy with high penetration of ceftriaxone in the CSF. The treatment of tetanus was not administered because the foreign body had migrated into his neck



**Figure 3.** Axial computed tomography myelograms showing that the sewing needle penetrated the foramen transversarium and was in contact with the cervical dura mater. Arrows indicate the sewing needle in each image panel.



**Figure 4.** Computed tomography angiogram demonstrating that the sewing needle was in contact with the right vertebral artery.



**Figure 5.** The removed sewing needle was completely covered with rust.

long ago. The patient was discharged on postoperative day 5 with no symptoms.

### 3. Discussion

Cervical foreign bodies have been previously reported, including cases of a nail-gun nail,<sup>[4]</sup> chopstick,<sup>[5]</sup> sublamina wiring,<sup>[6]</sup> and a pocket knife blade.<sup>[7]</sup> However, the report of a needle in the cervical spine is rare; only 2 previous reports exist. In 1 case,<sup>[8]</sup> the needle accidentally penetrated the cervical spine during a soccer game. In the other case,<sup>[9]</sup> the patient had been performing acupuncture on herself in the posterior neck region. In the current and both previous cases, the needle was removed under general anesthesia without any problems and the symptoms resolved.

In the present case, the needle entered the neck while avoiding the cervical spine and the vertebral artery, despite penetration through the spinal cord and into the foramen transversarium, as demonstrated by CT myelogram and CT angiogram. To the best of our knowledge, this is the first such report. Diagnostic imaging techniques such as 3D CT, CT myelogram, and CT angiogram are necessary because these tools can identify the relationship between a foreign body and tissues, such as blood vessels and nerves. In this case, CT myelogram and CT angiogram did not show penetration into the spinal cord and vertebral artery; hence, minimum invasive surgery was chosen.

There are more reports in the literature involving an acupuncture needle, rather than a sewing needle, as a foreign body in the cervical spine.<sup>[10,11]</sup> In general, sewing needles are thicker than acupuncture needles and are made of iron. Therefore, if left alone, a sewing needle may erode, which could lead to breakage and infection. We were concerned about a risk of meningitis; however, the patient exhibited no such symptoms.

Ulloth et al<sup>[12]</sup> reported a case of a CSF fistula caused by an acupuncture needle. In the present case, CSF leakage was observed immediately after removal of the needle. The cause of the CSF leakage was identified as a dural tear due to the needle removal. Thus, the contact between the needle and dura mater may result in a dural tear, even if the needle does not pierce the spinal cord.

In our case, the patient did not experience any symptoms after stabbing the posterior region of this neck with the sewing needle. However, the clinical picture of contact between the dura mater and a foreign body may involve sensorimotor deficits, CSF leakage, meningitis, and vertebral artery injury. Therefore, the surgical removal of a foreign body near the cervical spinal cord and vertebral artery should be performed as soon as possible, before the appearance of symptoms and signs.

### 4. Conclusion

We provide the first report of a sewing needle that entered the cervical spinal canal while avoiding the cervical spine and vertebral artery. Although no symptoms occurred for nearly 2 years, the needle had penetrated the foramen transversarium. Surgical removal of a foreign body near the cervical spinal cord and vertebral artery should be performed before the occurrence of symptoms.

### References

- [1] Di Paolo M, Guidi B, Vergaro G, et al. Self-inserted needles in the heart. *Am J Cardiol* 2015;116:1315–7.
- [2] Lewek P, Lewek J, Kardas P. An acupuncture needle remaining in a lung for 17 years: case study and review. *Acupunct Med* 2012;30:229–32.
- [3] Senol A, Isler M, Minkar T, et al. A sewing needle in the liver: 6 years later. *Am J Med Sci* 2010;339:390–1.
- [4] Nathoo N, Sarkar A, Varma G, et al. Nail-gun injury of the cervical spine: simple technique for removal of a barbed nail. *J Neurosurg Spine* 2011;15:60–3.
- [5] Yamaguchi S, Eguchi K, Takeda M, et al. Penetrating injury of the upper cervical spine by a chopstick. *Neurol Med Chir (Tokyo)* 2007;47:328–30.
- [6] Fraser AB, Sen C, Casden AM, et al. Cervical transdural intramedullary migration of a sublamina wire. A complication of cervical fixation. *Spine* 1994;19:456–9.
- [7] Zaldivar-Jolissaint JF, Bobinski L, Van Dommelen Y, et al. Delayed presentation of deep penetrating trauma to the subaxial cervical spine. *Eur Spine J* 2015;4:540–3.
- [8] Silvestro C, Cocito L, Pisani R. Delayed effects of a migrated foreign body (sewing needle) in the cervical spine. *Spine* 2001;26:578–9.
- [9] Anderson DW, Datta M. The self-pith. *AJNR Am J Neuroradiol* 2007;28:714–5.
- [10] Abumi K, Ando H, Kaneda K. Migration of an acupuncture needle into the medulla oblongata. *Eur Spine J* 1996;5:137–9.
- [11] Murata K, Nishio A, Nishikawa M, et al. Subarachnoid hemorrhage and spinal root injury caused by acupuncture needle: case report. *Neurol Med Chir (Tokyo)* 1990;30:956–9.
- [12] Ulloth JE, Haines SJ. Acupuncture needles causing lumbar cerebrospinal fluid fistula. *J Neurosurg Spine* 2007;6:567–9.