



## CASE BASED DISCUSSIONS

## Severe organising pneumonia following COVID-19

István Vadász,<sup>1,2,3,4</sup> Faeq Husain-Syed,<sup>1</sup> Peter Dorfmueller,<sup>2,3,5</sup> Fritz C Roller,<sup>6</sup> Khodr Tello,<sup>1,2,3,4</sup> Matthias Hecker,<sup>1,2,3</sup> Rory E Morty,<sup>1,2,3,4,7</sup> Stefan Gattenlöhner,<sup>5</sup> Hans-Dieter Walmrath,<sup>1</sup> Friedrich Grimminger,<sup>1,2,3,4</sup> Susanne Herold,<sup>1,2,3,4</sup> Werner Seeger<sup>1,2,3,4,7,8</sup>

**ABSTRACT**

Various forms of diffuse parenchymal lung disease have been proposed as potential consequences of severe COVID-19. We describe the clinical, radiological and histological findings of patients with COVID-19-associated acute respiratory distress syndrome who later developed severe organising pneumonia including longitudinal follow-up. Our findings may have important implications for the therapeutic modalities in the late-phase of severe COVID-19 and might partially explain why a subgroup of COVID-19 patients benefits from systemic corticosteroids.

**INTRODUCTION**

Over 15% of hospitalised patients with COVID-19 develop acute respiratory distress syndrome (ARDS).<sup>1</sup> ARDS is characterised by acute onset of bilateral infiltrates, hypoxaemia and lung oedema, which is not fully explained by cardiac failure or fluid overload, and is associated with high mortality.<sup>2</sup> The mortality in the critically ill group of patients with COVID-19 is comparable with that of severe ARDS, reaching approximately 40% at day 30 after admission to the intensive care unit (ICU).<sup>1</sup> Of note, the majority of patients with COVID-19-associated ARDS receive prolonged mechanical ventilation.<sup>3</sup> Several reports have now provided radiological evidence for different forms of diffuse parenchymal lung disease (DPLD) during the later course of the disease.<sup>4</sup> Organising pneumonia (OP), a form a DPLD, is a distinct clinicopathological entity that may occur as a pulmonary reaction to various injuries, including ARDS. OP is characterised by the patchy filling of alveoli and bronchioles by loose plugs of connective tissue with concomitant diffuse alveolar damage, the hallmark of ARDS. Radiological findings typically include peripheral consolidation, ground-glass infiltrates and/or solitary nodules. The definitive diagnosis of OP requires histological assessment and the primary treatment of OP is, apart from treating the underlying disease, corticosteroid administration over several months, initially at relatively high doses.<sup>5</sup>

**CASE REPORT**

Here, we describe the clinical, radiological and histological findings of three patients with COVID-19 who presented at our ICU and later developed severe OP, also focusing on the phase of recovery on corticosteroid therapy. Legally authorised representatives of the patients included in this study provided written informed consent. Between

March and May 2020, 38 patients tested positive for SARS-CoV-2, as confirmed by real-time PCR, and were admitted to our ICU. Twenty-four of these patients were diagnosed with moderate to severe ARDS, requiring mechanical ventilation. Over the course of the disease, after a phase of transient recovery, three patients exhibited extraordinary clinical worsening with progressively decreasing pulmonary compliance (from initial  $40.1 \pm 2.3$  to  $59.9 \pm 6.8$  on recovery, and then to  $18.9 \pm 3.8$  mL/mbar on deterioration) and reduced PaO<sub>2</sub>/FiO<sub>2</sub> ratio (for clinical data see online supplemental table 1).

**Patient 1**

A 57-year-old male patient was admitted to our ICU with severe acute respiratory failure, 8 days after he had developed unproductive cough and fever with an initial peripheral oxygen saturation (SaO<sub>2</sub>) of 72% under room air. On supplementation with 6L O<sub>2</sub>/min, arterial blood gas analysis revealed a PaO<sub>2</sub> of 67 mm Hg and a SaO<sub>2</sub> of 94% accompanied by moderate hypocapnia as a consequence of compensatory hyperventilation. The initial chest X-ray of the patient revealed extensive ground-glass opacification in both lower lobes and the left midfield (online supplemental figure 1A). On the fourth day in the ICU, the patient had to be intubated due to severe respiratory failure. In the following hours, the PaO<sub>2</sub>/FiO<sub>2</sub> ratio remained ~70. Oxygenation could be improved after prone positioning and inhaled nitric oxide therapy. Over the following 2 weeks, the condition of the patient gradually improved. In sequential bronchial lavage samples, SARS-CoV-2 remained positive for 8 days after admission to ICU (and 16 days after the initial PCR). Subsequent lavage samples were all SARS-CoV-2 negative. The microbiological analysis of a lavage sample on day 8 after admission revealed a bacterial superinfection with *Serratia marcescens* that was treated with antibiotics. Approximately 16 days after initiation of mechanical ventilation, lung compliance deteriorated, necessitating the use of higher driving pressure and respiratory rate and ultimately extracorporeal CO<sub>2</sub> removal to limit further ventilator-induced lung injury and to prevent the deleterious effects of respiratory acidosis on distant organs. At this point, the microbiological analysis of a bronchial lavage revealed no bacterial or fungal infection. A follow-up X-ray, as well as a high-resolution CT, revealed consolidation, bronchiectasis and fibrous bands after the initial phase of ground-glass opacification (online supplemental figure 1B,

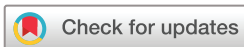► Supplemental material is published online only. To view please visit the journal online (<http://dx.doi.org/10.1136/thoraxjnl-2020-216088>).

For numbered affiliations see end of article.

**Correspondence to**

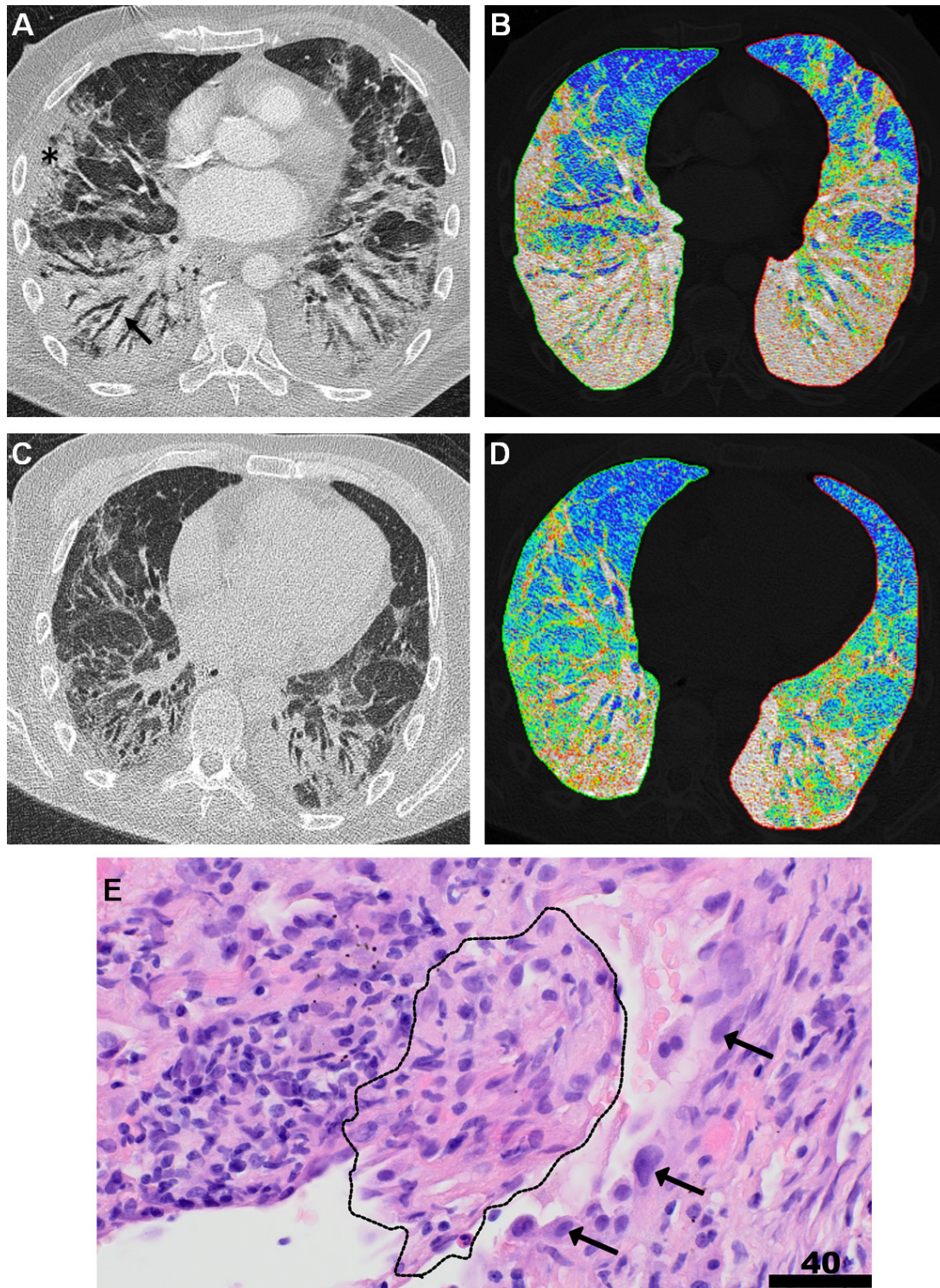
Dr István Vadász, Department of Internal Medicine, Faculty of Medicine, Justus Liebig University Giessen, 35392 Giessen, Germany; [istvan.vadasz@innere.med.uni-giessen.de](mailto:istvan.vadasz@innere.med.uni-giessen.de)

Received 26 August 2020  
Revised 2 October 2020  
Accepted 12 October 2020



© Author(s) (or their employer(s)) 2020. No commercial re-use. See rights and permissions. Published by BMJ.

**To cite:** Vadász I, Husain-Syed F, Dorfmueller P, et al. *Thorax* Epub ahead of print: [please include Day Month Year]. doi:10.1136/thoraxjnl-2020-216088



**Figure 1** Organising pneumonia complicating severe COVID-19. (A) Thoracic CT of a patient with COVID-19 on clinical deterioration and markedly decreasing pulmonary compliance 16 days after the initiation of mechanical ventilation, revealing extensive subpleural patchy consolidation (black asterisk), fibrotic bands and traction bronchiectasis (black arrow) of the middle lobe, the lingula and both lower lobes, compatible with organising pneumonia. (B) A colour-coded lung density map (based on Hounsfield units) at the same level as (A). Blue areas represent normal lung tissue with normal lung density values, whereas green areas represent lung tissue with slightly increased density values, consistent with ground-glass opacification and red/white areas characterise lung tissue with markedly increased density values consistent with consolidations/fibrotic changes. (C) Follow-up CT approximately 8 weeks after the initiation of corticosteroid therapy, showing partially reversed peribronchovascular consolidation, fibrotic bands and bronchiectasis. (D) The corresponding colour-coded lung density map confirms the decreased density values of the affected areas. (E) Histology of a transbronchial biopsy from the same patient with H&E staining at a magnification of  $\times 400$  is illustrated. The organisation of an actin<sup>+</sup> fibrous plug (immunostainings not shown) within an alveolus, intermingled with lymphocytes (dotted line), corresponding to organising pneumonia with prominent hyperplasia of surrounding alveolar pneumocytes (arrows). Scale bar corresponds to 40  $\mu\text{m}$ .

figure 1A and B, online supplemental video 1). These radiological findings were compatible with severe OP as an apparent cause of declining pulmonary compliance and gas exchange. Subsequently, the patient underwent bronchoscopy with transbronchial biopsies from the affected regions to enable histological evaluation. Apart from diffuse alveolar damage, histopathological findings confirmed the typical features of OP, including mesenchymal plugs partially filling the alveolar lumen (Masson bodies; figure 1E, online supplemental figure 2). Consequently, a systemic corticosteroid therapy with prednisolone at a dose of 1 mg/kg/d for 4 weeks, and gradually reduced over the subsequent weeks, was initiated. On steroid therapy, the pulmonary function and blood gases markedly improved, which correlated with the radiological findings (figure 1C and D and online supplemental video 2). Two and 4 weeks after the initiation of steroid therapy, respectively, the patient was weaned from extracorporeal CO<sub>2</sub> removal and the ventilator; after which he was transferred to a rehabilitation clinic without any oxygen supplementation required.

### Patient 2

An intubated 70-year-old male patient with COPD was transferred to our ICU from another hospital with confirmed SARS-CoV-2 infection, presenting with an acute pneumothorax on mechanical ventilation that could only partially be resolved after placing a narrow-bore chest tube. The patient was admitted to the ICU 8 days after the initial presentation of symptoms, and mechanical ventilation was required 2 days postadmission. The pneumothorax was evident on day 6 after initiation of mechanical ventilation, and transfer to our centre followed 2 days after placement of two chest tubes. After placing a large-bore chest tube at our ICU, the patient exhibited a transient recovery; however, it remained difficult to wean the patient from the ventilator. Over the following 4 weeks, a progressive clinical worsening with gradually decreasing pulmonary compliance was evident, similarly to patient 1. High-resolution CT revealed consolidation and bronchiectasis, in line with the presentation of OP, which was confirmed by histological analysis of transbronchial biopsies. On prednisolone therapy at an initial dose of 1 mg/kg/d for 4 weeks, both pulmonary compliance and the extent of the OP that was evident radiologically markedly improved, and the patient was rapidly weaned off the ventilator. However, over the following weeks, several episodes of pneumothorax complicated this case and required video-assisted thoracoscopic surgery. Nevertheless, nearly 4 months after admission, this patient was discharged from the ICU without any need for supplemental oxygen.

### Patient 3

Similar to patient 2, patient 3 was transferred to our ICU from another hospital with confirmed SARS-CoV-2 infection 8 days after the initial presentation of symptoms. At admission, the 76-year-old male patient required supplementation of 6L O<sub>2</sub>/min. After a further deterioration of respiratory function, the patient underwent intubation 4 days later because non-invasive ventilation via a helmet was not tolerated. After the acute phase of ARDS, weaning of the patient from the ventilator remained problematic. On worsening of lung compliance, CT suggested OP. The diagnosis of OP was confirmed by histological analysis of transbronchial biopsies, 8 weeks after initiation of mechanical ventilation. Similar to the other two cases, on prednisolone therapy, radiological signs of OP abated, and the patient was weaned from the ventilator. Of

note, 4 weeks after the initiation of prednisolone, the patient was transferred to a rehabilitation clinic without the requirement of supplemental oxygen.

### DISCUSSION

To the best of our knowledge, this is the first report on OP with longitudinal follow-up secondary to COVID-19-associated ARDS. Of note, our findings may have important implications for the therapeutic modalities in the late phase of severe COVID-19 since OP is generally regarded as corticosteroid sensitive.<sup>5</sup> Furthermore, the incidence of OP (12.5%) is relatively common in our cohort. Although our study has the limitations of its single-centre nature and of small sample size, these findings might partially explain why a subgroup of COVID-19 patients appears to benefit from systemic corticosteroids.<sup>6</sup>

Various other forms of DPLD have also been proposed as potential complications/consequences of severe COVID-19, including pathologies where more prominent fibrotic changes are evident.<sup>7</sup> Even if these entities are relatively rare, given that as of 1 October 2020, over 34 million people worldwide have been infected with SARS-CoV-2, the implications at the population level are potentially significant. Thus, it is important that the survivors of severe (and perhaps also mild and moderate) COVID-19 are followed-up regularly in specialised centres to recognise potential deteriorations early. Indeed, in our lung centre, we have now established a post-COVID-19 outpatient clinic where, at timed intervals, patient-reported outcome measures are collected and lung function as well as longitudinal CT scans are performed and analysed to more precisely assess the burden of DPLD on COVID-19 and whether it varies from non-COVID ARDS.

Importantly, corticosteroids (6 mg dexamethasone or equivalent given once daily for up to 10 days) are now recommended by the WHO in severe and critical forms of COVID-19.<sup>6,8</sup> Thus, it may well be that although the dose and duration of corticosteroid therapy in OP clearly differ, the incidence of OP on ARDS secondary to COVID-19 might decrease. However, in selected cases in which patients show clinical worsening together with consolidation, bronchiectasis and/or fibrotic changes in radiological imaging, transbronchial biopsies enabling further histological evaluation might have added value.

Furthermore, whether these pathologies are specific to COVID-19 or rather a consequence of sustained mechanical ventilation has not yet been determined. If deleterious remodelling has been confirmed, it will be important to tease out the mechanisms by which such pathologies are driven and their nature regarding reversibility. Moreover, as parenchymal alterations on COVID-19 have been described relatively early in a subset of patients,<sup>7</sup> it might be worthwhile to investigate whether in the early post-acute phase of COVID-19, a preventive anti-inflammatory approach is more beneficial than a therapeutic one. Prospective interventional clinical trials to address these issues are warranted.

### Author affiliations

<sup>1</sup>Department of Internal Medicine, Faculty of Medicine, Justus Liebig University Giessen, Giessen, Hessen, Germany

<sup>2</sup>Universities of Giessen and Marburg Lung Center, Giessen, Hessen, Germany

<sup>3</sup>German Center for Lung Research, Giessen, Hessen, Germany

<sup>4</sup>The Cardio-Pulmonary Institute, Giessen, Hessen, Germany

<sup>5</sup>Institute of Pathology, Faculty of Medicine, Justus Liebig University Giessen, Giessen, Hessen, Germany

<sup>6</sup>Department of Radiology, Faculty of Medicine, Justus Liebig University Giessen, Giessen, Hessen, Germany

<sup>7</sup>Department of Lung Development and Remodelling, Max Planck Institute for Heart and Lung Research, Bad Nauheim, Hessen, Germany

<sup>8</sup>Institute for Lung Health, Giessen, Hessen, Germany

**Contributors** The authors shared data collection, data analyses and data interpretation, as well as preparation, review and approval of the manuscript. The corresponding author had full access to all study data and had final responsibility for the decision to submit for publication. IV, FH-S, PD, FCR, KT, MH, SG, H-DW, FG, SH and WS: acquisition, analyses or interpretation of data. REM, SG, H-DW, SH and WS: literature research and clinical advice. IV: manuscript drafting. IV, FH-S, PD, FCR, KT, MH, REM, SG, H-DW, FG, SH and WS: critical revision of the manuscript for important intellectual content. IV, FH-S, PD and FCR: figure illustration. IV and WS: study supervision.

**Funding** Grants from the Federal Ministry of Education and Research (German Center for Lung Research [DZL/ALI]; to IV, FG, SH and WS), the German Research Foundation (DFG/CRU309; to IV, REM, FG, SH and WS) and The Cardio-Pulmonary Institute (EXC 2026; Project ID: 390649896; to IV, KT, REM, FG, SH and WS), the von Behring Röntgen Foundation (Project 66-LV07; to IV) supported this work.

**Competing interests** None declared.

**Patient consent for publication** Obtained.

**Provenance and peer review** Not commissioned; externally peer reviewed.

This article is made freely available for use in accordance with BMJ's website terms and conditions for the duration of the covid-19 pandemic or until otherwise determined by BMJ. You may use, download and print the article for any lawful,

non-commercial purpose (including text and data mining) provided that all copyright notices and trade marks are retained.

## REFERENCES

- 1 Cummings MJ, Baldwin MR, Abrams D, *et al*. Epidemiology, clinical course, and outcomes of critically ill adults with COVID-19 in New York City: a prospective cohort study. *Lancet* 2020;395:1763–70.
- 2 Bellani G, Laffey JG, Pham T, *et al*. Epidemiology, patterns of care, and mortality for patients with acute respiratory distress syndrome in intensive care units in 50 countries. *JAMA* 2016;315:788–800.
- 3 Bhatraju PK, Ghassemieh BJ, Nichols M, *et al*. Covid-19 in Critically Ill Patients in the Seattle Region - Case Series. *N Engl J Med* 2020;382:2012–22.
- 4 Shi H, Han X, Jiang N, *et al*. Radiological findings from 81 patients with COVID-19 pneumonia in Wuhan, China: a descriptive study. *Lancet Infect Dis* 2020;20:425–34.
- 5 Drakopanagiotakis F, Polychronopoulos V, Judson MA. Organizing pneumonia. *Am J Med Sci* 2008;335:34–9.
- 6 WHO Rapid Evidence Appraisal for COVID-19 Therapies (REACT) Working Group, Sterne JAC, Murthy S, *et al*. Association between administration of systemic corticosteroids and mortality among critically ill patients with COVID-19: a meta-analysis. *JAMA* 2020. doi:10.1001/jama.2020.17023. [Epub ahead of print: 02 Sep 2020].
- 7 George PM, Wells AU, Jenkins RG. Pulmonary fibrosis and COVID-19: the potential role for antifibrotic therapy. *Lancet Respir Med* 2020;8:807–15.
- 8 RECOVERY Collaborative Group, Horby P, Lim WS, *et al*. Dexamethasone in Hospitalized Patients with Covid-19 - Preliminary Report. *N Engl J Med* 2020. doi:10.1056/NEJMoa2021436. [Epub ahead of print: 17 Jul 2020].