

CASE REPORT

APPENDICITIS AND SITUS INVERSUS VISCERUM IN A 32-YEAR-OLD FEMALE NIGERIAN: A CASE REPORT

A.E.O. Adeniyi¹, Cynthia O. Akisanya², O.S. Ogah³, Akinremi Titilola O⁴., Charles A. Erinle⁵

1. Department of Surgery 2. Department of Radiology 3. Department of Medicine 4. Department of Pathology.
5. Department of Family Medicine, (Federal Medical Centre, Abeokuta, Ogun State, Nigeria)

Corresponding Author

Dr O.S. Ogah

Department of Medicine,
Federal Medical Centre, Idi-Aba, Abeokuta,
PMB 3031 Sapon PO, Abeokuta,
Ogun State, Nigeria
E-mail: osogah56156@yahoo.com

ABSTRACT

Situs inversus is a relatively rare congenital abnormality in which the internal organs are disposed in a mirror image of the normal. It is said to be an autosomal recessive genetic condition. Its prevalence varies with population. In the United States, Situs inversus is found in 0.01% of the population. The incidence in Nigeria is unknown. We present the case of a young lady with situs inversus discovered during management for appendicitis. As is often the case in situs situations, there was initial confusion and some significant delay in offering needed treatment due to the unusual disposition of the organs.

Key Words: Situs Inversus, Appendicitis, Dextrocardia

INTRODUCTION

Matthew Baillie first described the complete mirror image reversal of the thoracic and abdominal organs in situs inversus in the 18th century. Earlier in 1643, Marco Severino had described the first case of dextrocardia. Since then several cases of both conditions separately or together have been reported in western literature¹⁻⁴ but relatively rarely in the developing world⁵⁻⁹. Situs abnormalities are congenital without racial or sexual predilection¹⁰.

We present the case of a young lady with situs inversus discovered during management for appendicitis. As is often the case in situs situations, there was initial confusion and some significant delay in offering needed treatment due to the unusual disposition of the organs. This is highlighted in our presentation.

Case Summary

A 32 year old Nigerian woman first presented to us with complaint of right sided abdominal pain of 9 days duration described as biting in nature and radiating to the lower back. She had three similar attacks in the preceding thirteen years, usually short-lived and associated with nausea and vomiting. She had a bowel movement every three 3 or 4 days but the stools were normal.

She had unproductive cough since childhood, worked as an executive secretary, and had three children at presentation all from spontaneous vaginal deliveries. She was otherwise in good health.

On abdominal palpation, there was tenderness maximal at the right iliac fossa but extending to the suprapubic area. White blood cell count as well as urine analysis results were unremarkable. A clinical diagnosis of acute on chronic appendicitis was made with some degree of confidence and surgery was planned.

The chest X-ray (Figure 1) showed a right-sided cardiac apex indicative of dextrocardia. However, due to the poor visualization of the gastric air bubble, an abdominal ultrasound was done to rule out a situs inversus. The abdominal ultrasound confirmed situs inversus affecting the intraabdominal viscera. No sign of gynaecological problem was visualised.

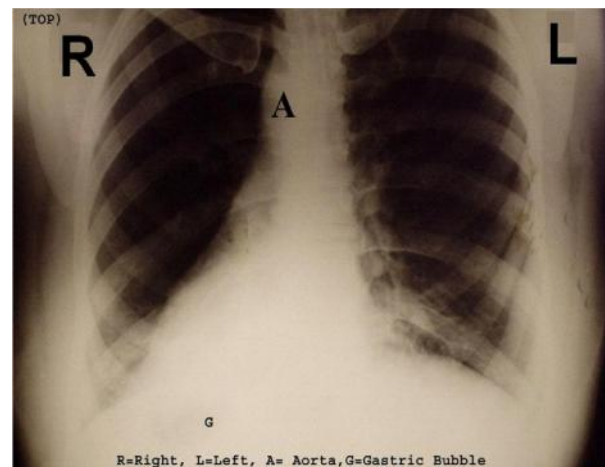


Figure 1. The chest radiograph of the patient showing dextrocardia and gastric air bubble on the right

It became difficult attributing the mainly right-sided pain to appendicitis. A laparoscope was not available so a barium enema was ordered to exclude symptomatic diverticular disease and other colonic pathology. Barium enema (Figure 2) showed no large bowel pathology apart from confirming situs inversus. CXR showed no evidence of bronchiectasis or other lung lesion. A normal left sided electrocardiogram showed inversion of the waves in leads aVR, I, aVL, V4-6. A reverse (Right sided ECG) demonstrated a normal pattern (Figures not shown) Echocardiography indicated atrio-ventricular and great arteries-ventricular concordance.

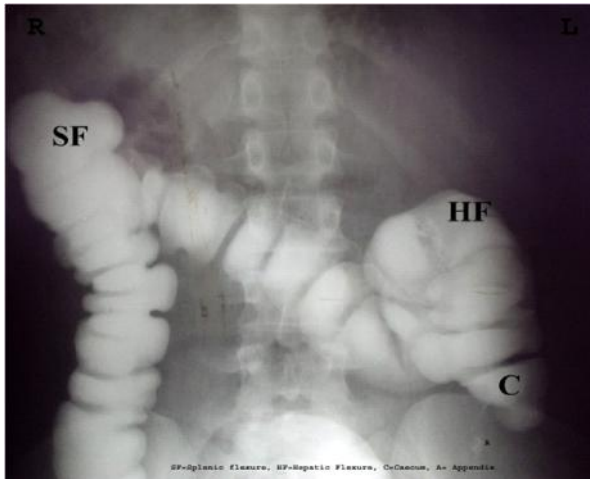


Figure 2. The Barium enema of the patient showing splenic flexure on the right and hepatic flexure on the left.

The pain gradually subsided on the interim medical treatment (antibiotics –Ceftriazone and Metronidazole) being given and the patient, who had been apparently trying to come to terms with the notion that she was “abnormal”, opted to go home.

About 18 months later she re-presented with features typical of appendicitis, complete with rebound phenomenon, but now sited over the left iliac fossa.

She admitted that she had a number of similar attacks of the pain in the interval between the last admission and the current presentation. Also the location of the pain varied from left to right and centrally in the lower abdomen.

She had an uneventful appendicectomy (via a midline infra umbilical laparotomy incision so as to be able to explore the abdomen more satisfactorily).

Situs inversus was confirmed at operation with the caecum and appendix in the left iliac fossa.

The appendix was 11cm long and was buried in adhesions involving almost its entire length binding it to both the caecum and the terminal ileum and was disposed in the preileal position. Subsequent histology revealed section of appendix showing mucosal and sub-mucosal lymphoid hyperplasia, ulceration and fibrosis as well as inflammatory cellular infiltration with lymphocytes, eosinophils and neutrophils. The muscle and serosal layers were oedematous with lymphocytic and eosinophilic cellular infiltrate in keeping with acute on chronic appendicitis (figure 3).

She made an uneventful recovery and was discharged home obviously greatly relieved.

DISCUSSION

Situs inversus is a relatively rare congenital abnormality in which the internal organs are disposed in a mirror image of the normal. It is said to be an autosomal

recessive genetic condition. Its prevalence varies with population. In the United States, Situs inversus is found in 0.01% of the population¹⁰. The incidence in Nigeria is unknown. There is no racial predilection and sex incidence is 1:1

Situs describes the position of the cardiac atria and viscera. Situs solitus is the normal position while situs inversus is the mirror image of solitus. In situs inversus, the morphologic right atrium is on the left while the morphologic left atrium is on the right. The left lung has 3 lobes while the right lung has 2 as opposed to the normal pulmonary anatomy. The liver and gallbladder are situated on the left while the stomach and spleen are on the right.

Individuals with situs inversus are predisposed to common medical as well as surgical conditions.

The recognition of situs inversus is of surgical importance, as it will prevent surgical mishaps resulting from an atypical history and failure to recognise reversed anatomy.

Acute appendicitis is the commonest cause of surgical abdominal pain and it is not surprising that appendicitis is widely reported in situs inversus despite the fact that that condition is by itself relatively rare.

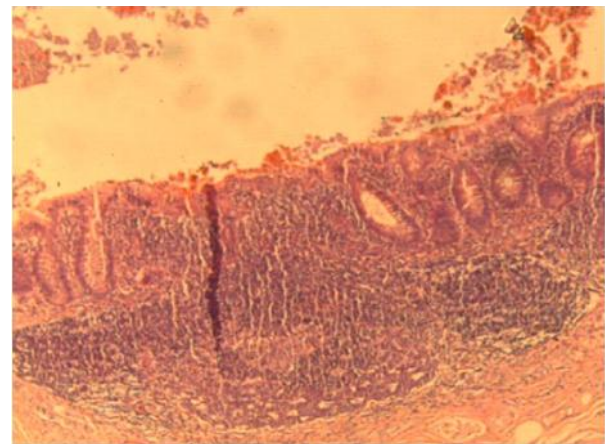


Figure 3. Photograph of the histology of the removed appendix showing features of acute on chronic appendicitis.

Not helping matters is the report that abdominal pain in situs inversus can be poorly localized and that in up to 50% of cases the pain is referred to the right iliac fossa²¹. This situation seems to have been highlighted by our patient whose pain seemed to migrate across her lower abdomen. She was saved from a potentially non-effective standard right iliac fossa appendicectomy incision by the chest x-ray ordered for other reasons, which exposed a dextrocardia, which subsequently triggered a search for the related condition of situs inversus.

The situation underscores the importance of laparoscopy in the management of acute abdominal

pain of uncertain origin in general and in situs inversus in particular. Contini *et al.* advised the use of laparoscopy when appendicitis is suspected in the presence of situs inversus because of its superior advantage over open appendicectomy. This allows more accurate diagnosis and better exploration of the abdomen^[4].

Patients with situs inversus reportedly have a normal life expectancy. In the rare instances of cardiac anomalies, the life expectancy is reduced depending on the severity of the defect.

Our patient was an otherwise normal mother of three. The diagnosis of situs inversus would probably never have been made had she not had appendicitis. It is possible that many cases of situs inversus have been missed and are still being missed especially in the developing world where medical examinations are infrequently conducted in individuals who are not ill.

Differential diagnosis of lower abdominal pain in this setting will include disorders of the genitourinary tract such as pelvic inflammatory disease, ovarian torsion, and ectopic gestation. Others are disorders of the gastrointestinal tract such as acute Pancreatitis and diverticular disease

The purpose of this presentation is to report the existence of this condition in our environment and highlight some of the difficulties that may arise in management of otherwise straightforward surgical condition if its presence is not recognized on time.

REFERENCES

1. **Jules P.** Acute appendicitis in situs inversus; report of a case. *J Med Soc N J* 1956;53(12):582-583.
2. **Lesser A.,** Zuckerman H. Acute appendicitis in situs inversus. *N Y State J Med* 1958;58(1):67-68.
3. **Holgersen L.O.,** Kuehner C.R., Stanley-Brown E.G. Acute appendicitis in a child with complete situs inversus. *J Pediatr Surg* 1970;5(3):379-380.
4. **Contini S.,** Dalla Valle R., Zinicola R. Suspected appendicitis in situs inversus totalis: an indication for a laparoscopic approach. *Surg Laparosc Endosc* 1998;8(5):393-394.
5. **Adeyekun A.A.,** Onunu A.N., Mazeli F.O. Dextrocardia with situs inversus: a case report. *West Afr J Med* 2003;22(4):358-360.
6. **Danbauchi S.S.,** Alhassan M.A. Case report: dextrocardia with situs inversus; two cases presenting differently. *Niger Postgrad Med J* 2002;9(4):248-252.
7. **Ofofile F.A.,** Adelaye A. Acrocephalosyndactyly with hydrocephalus and dextrocardia in a Nigerian child. *J Natl Med Assoc* 1982;74(8):800-803.
8. **Singhadej P.,** Sintuvanich A., Vichankaiyakij V. Situs inversus and appendicitis. *J Med Assoc Thai* 1984;67(3):194-200.
9. **Prasad V.** Left sided appendicitis and situs inversus. *Indian J Gastroenterol* 1992;11(1):44-45.
10. **Carmichael K.A.,** Gayle W.E., Jr. Situs inversus and appendicitis. *South Med J* 1979;72(9):1147-1150.